

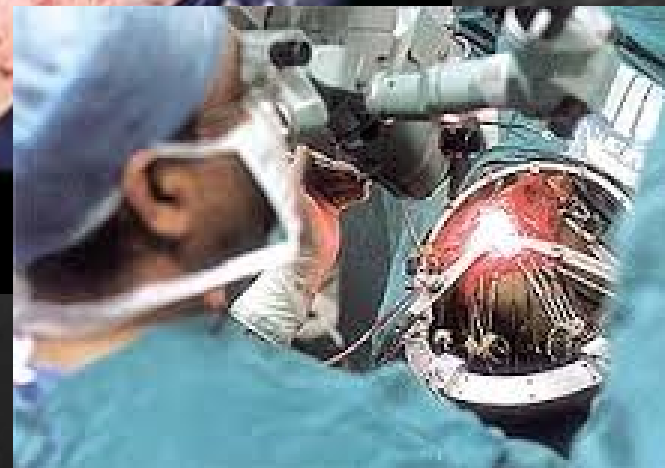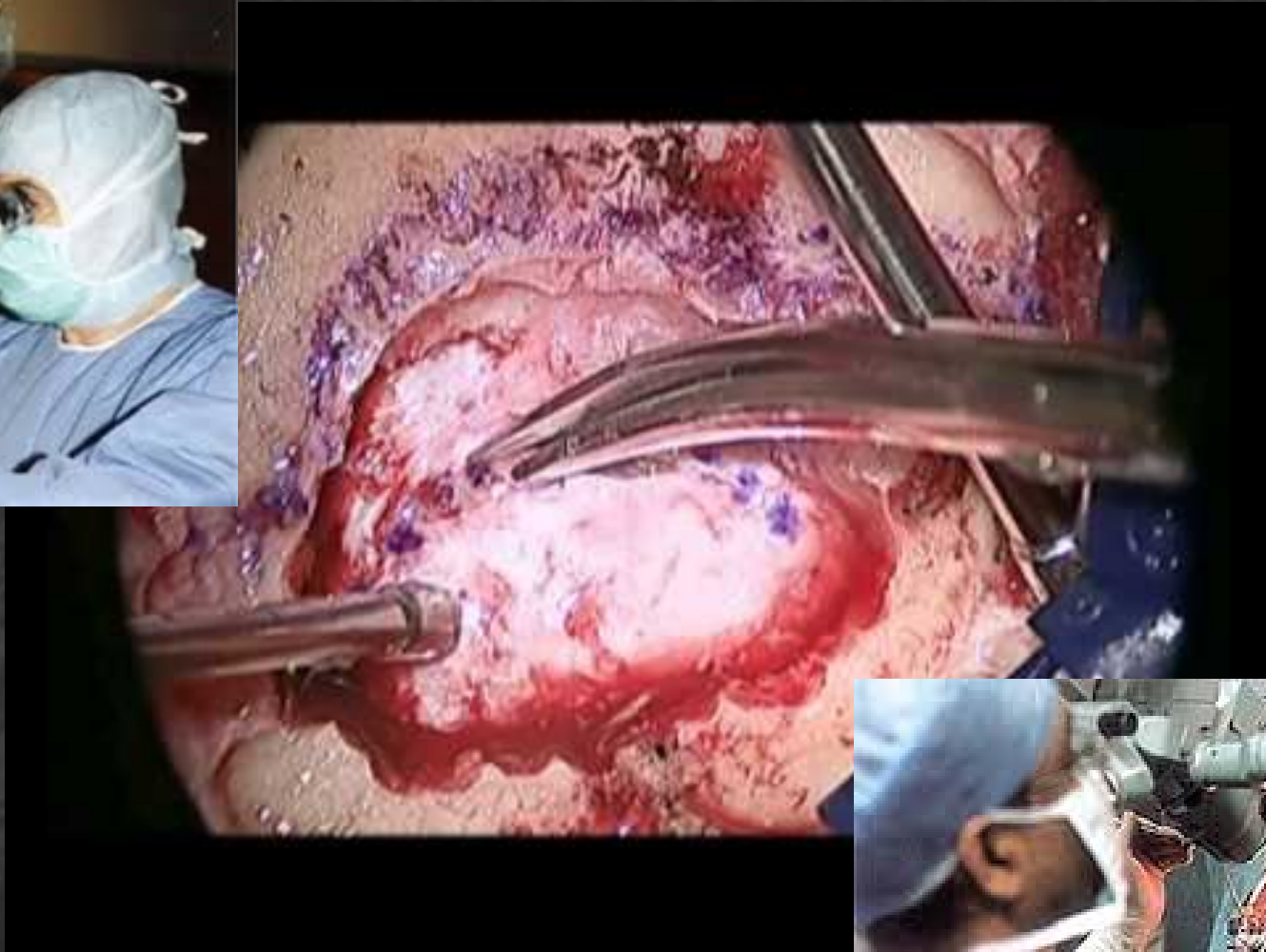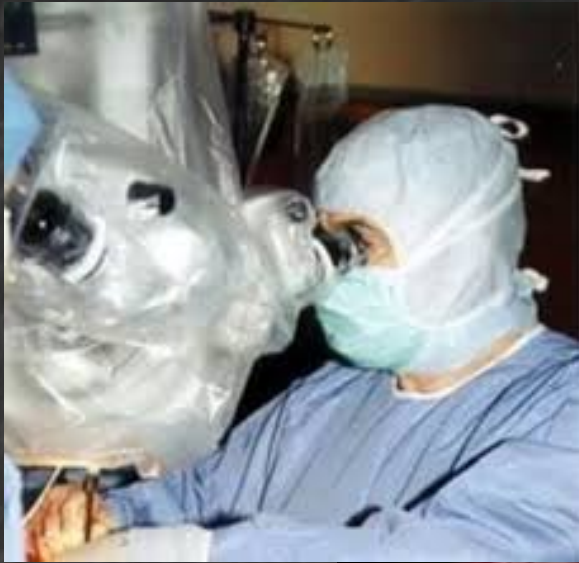Veľké pokroky v neurochirurgii

Opšenák R.

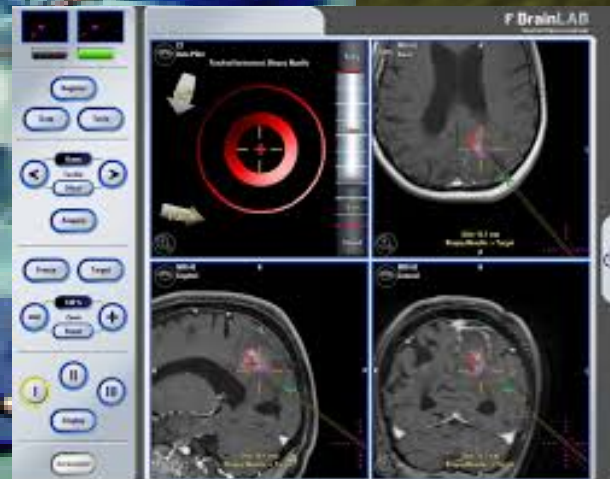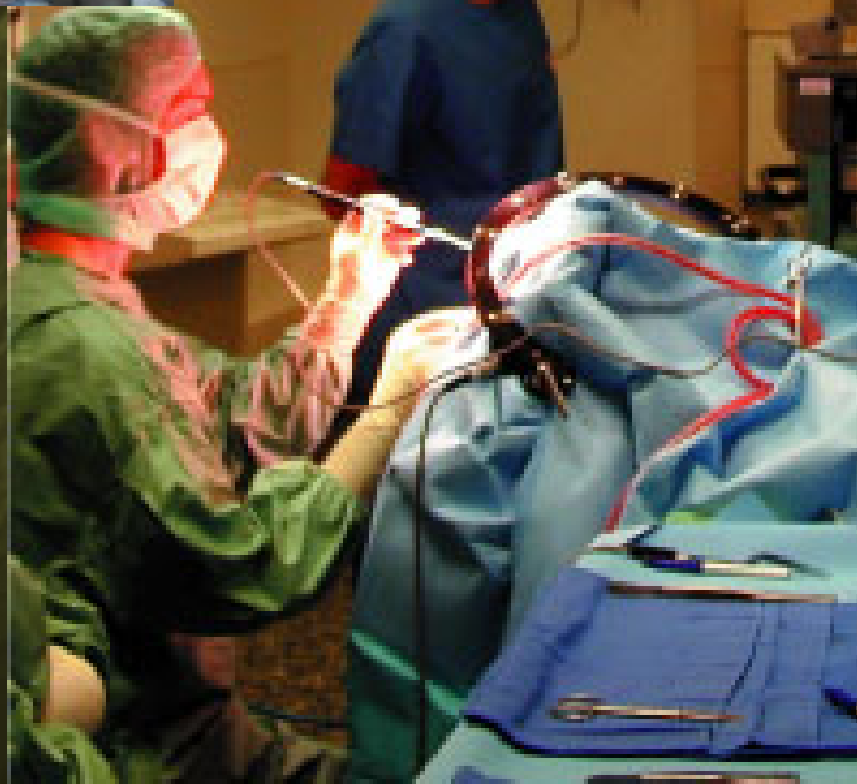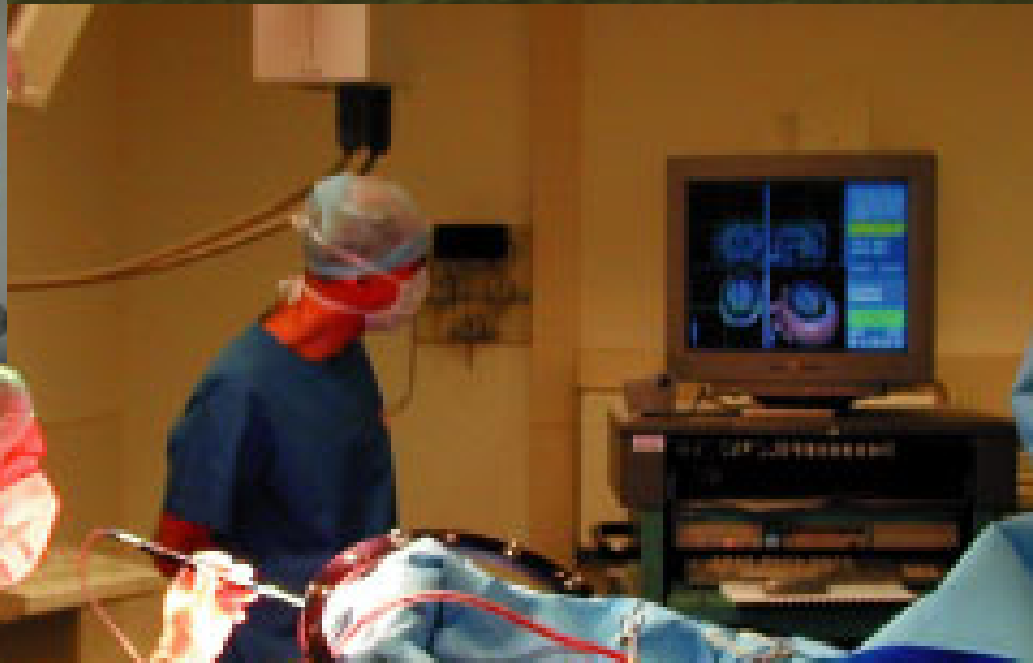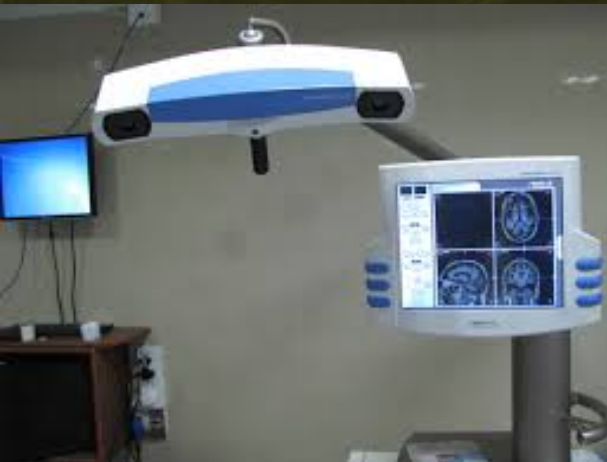Neurochirurgická klinika JLF UK a UNM

Univerzita tretieho veku pri JLF UK v Martine

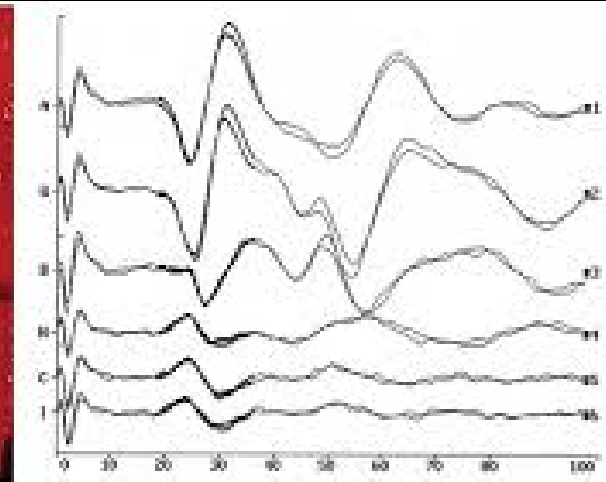
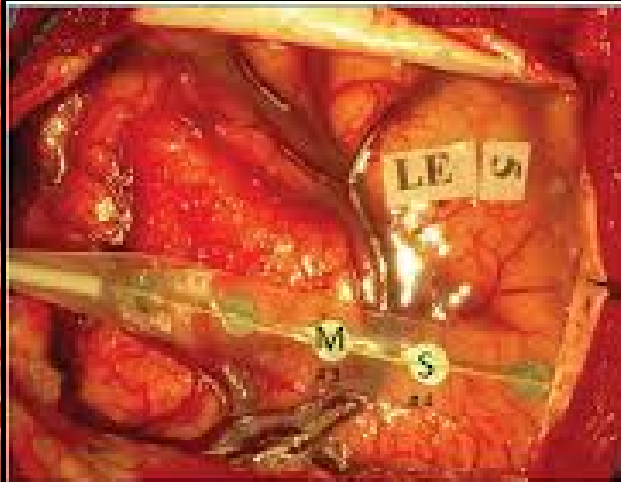
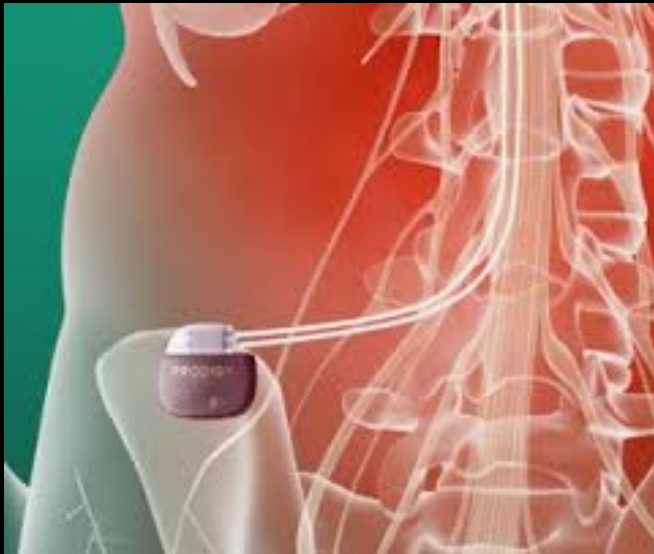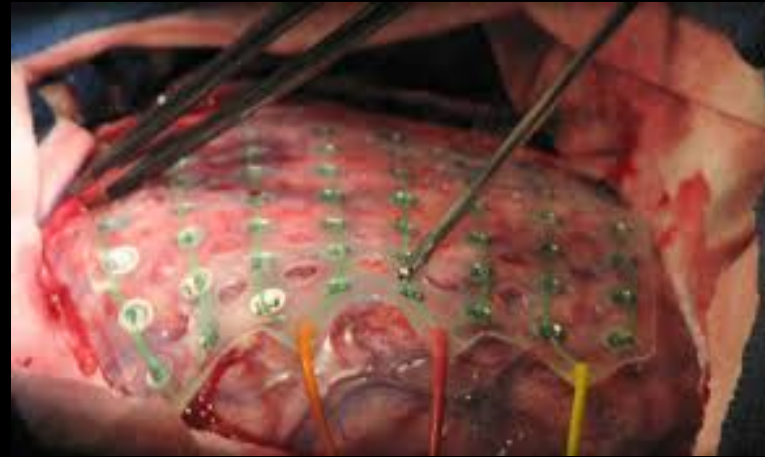
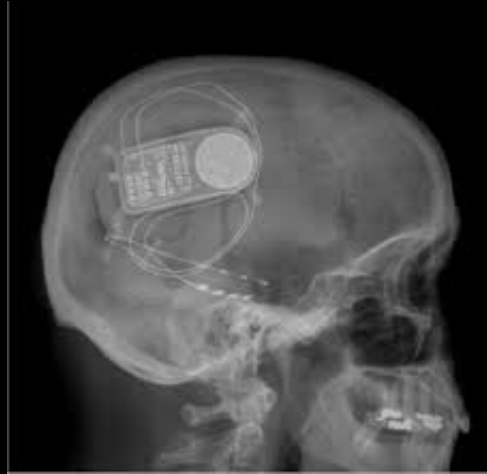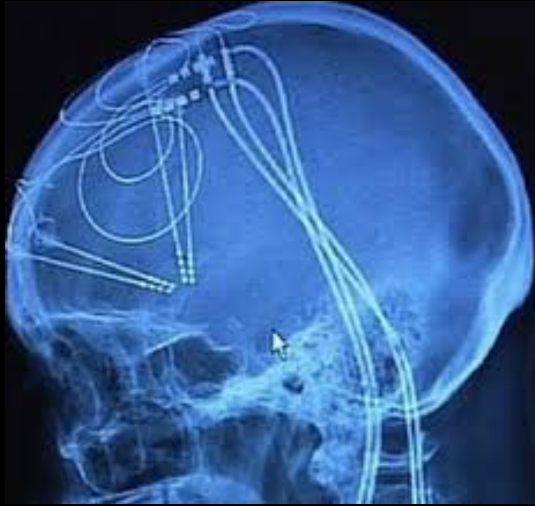
Mikrochirurgická technika

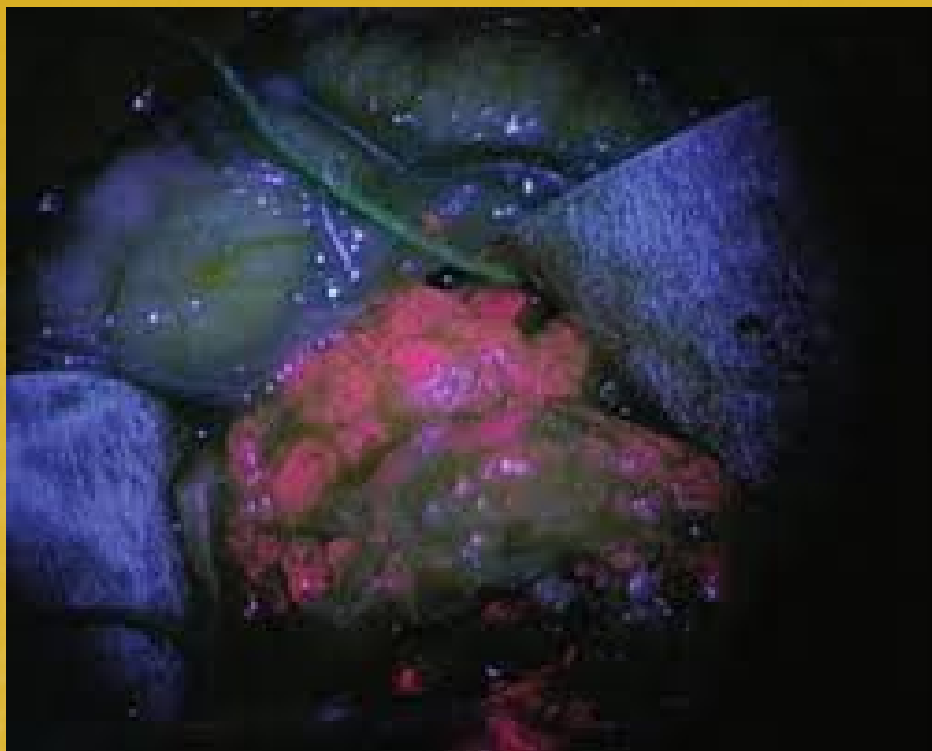


Neuronavigácia

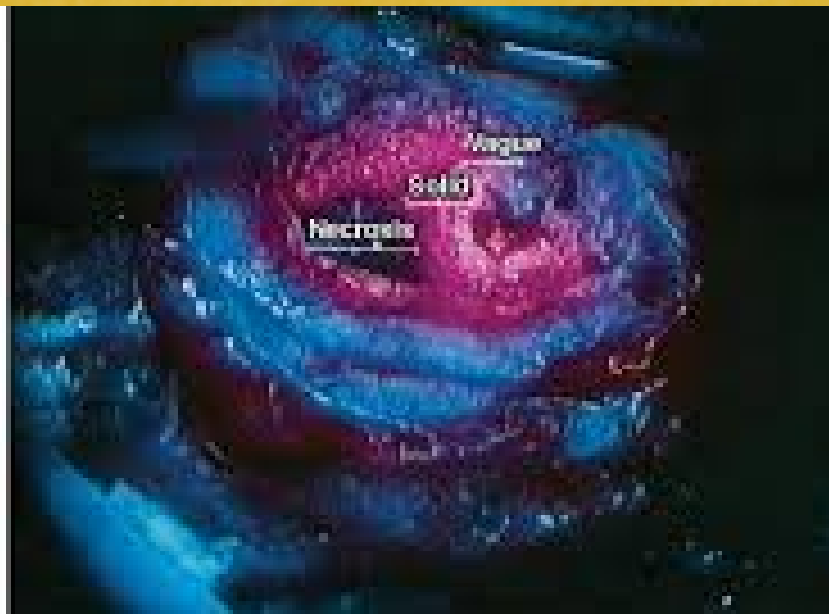
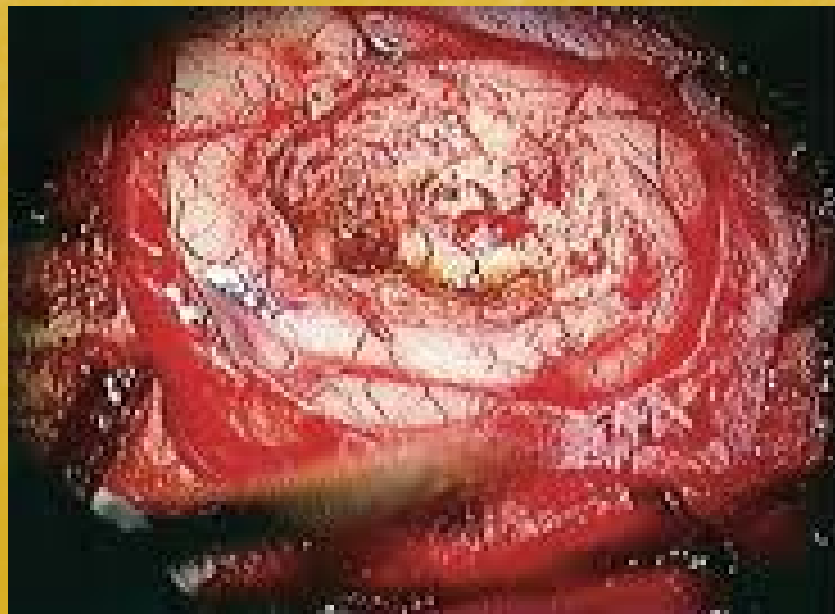
Neurostimulácia

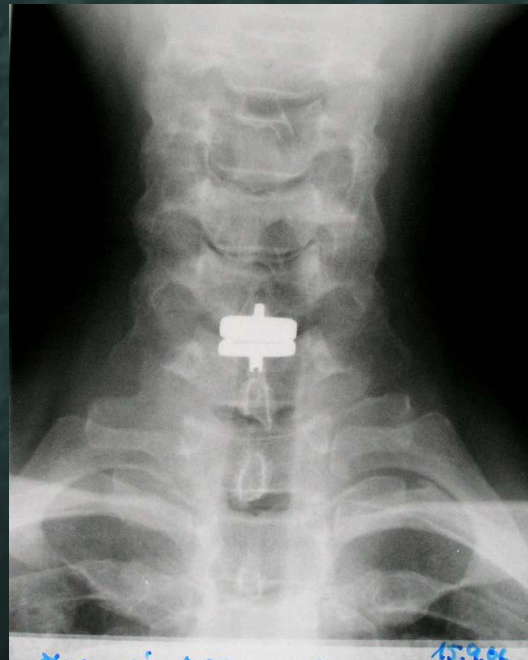
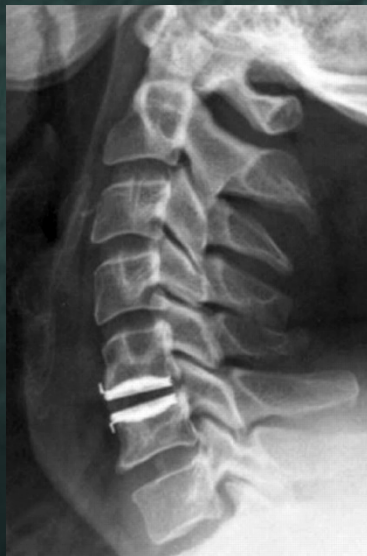
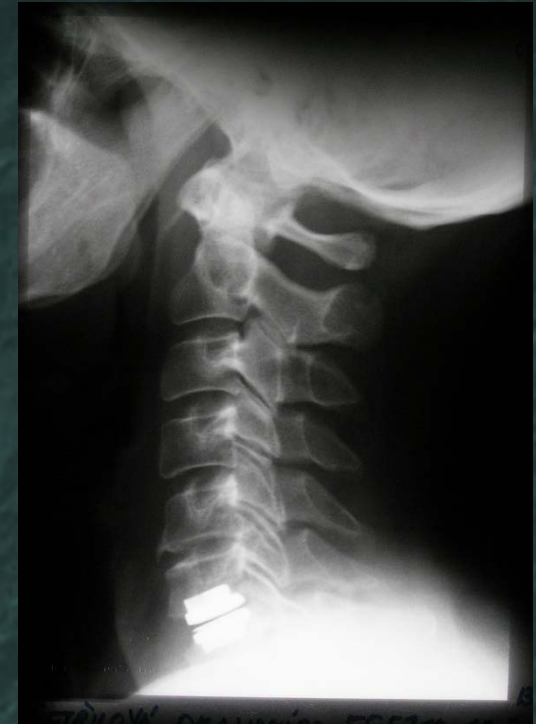
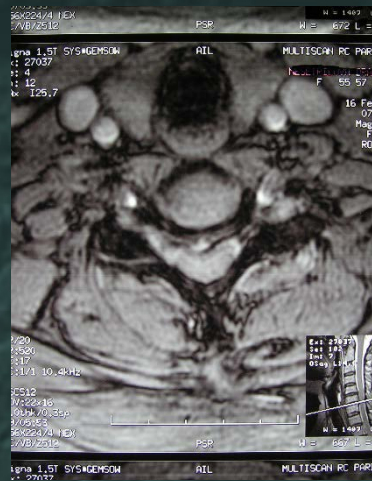
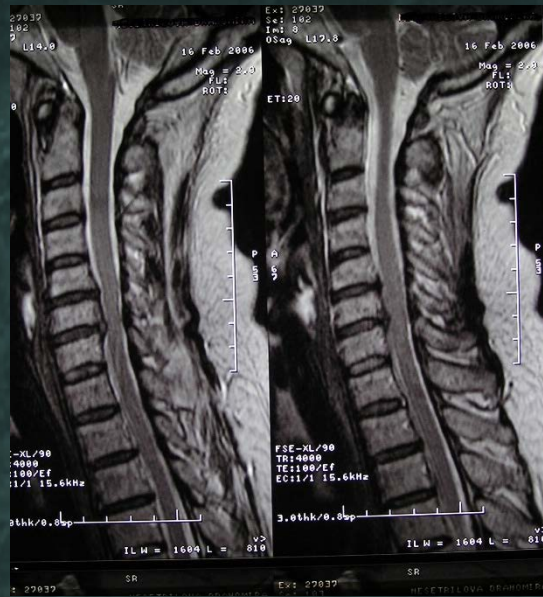
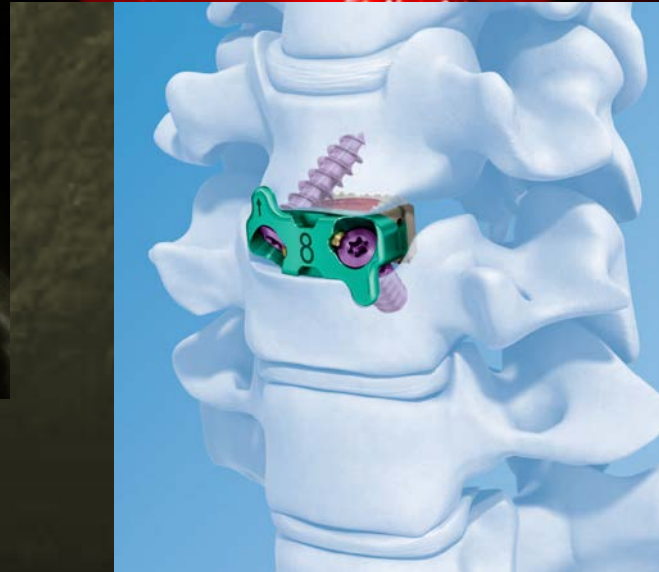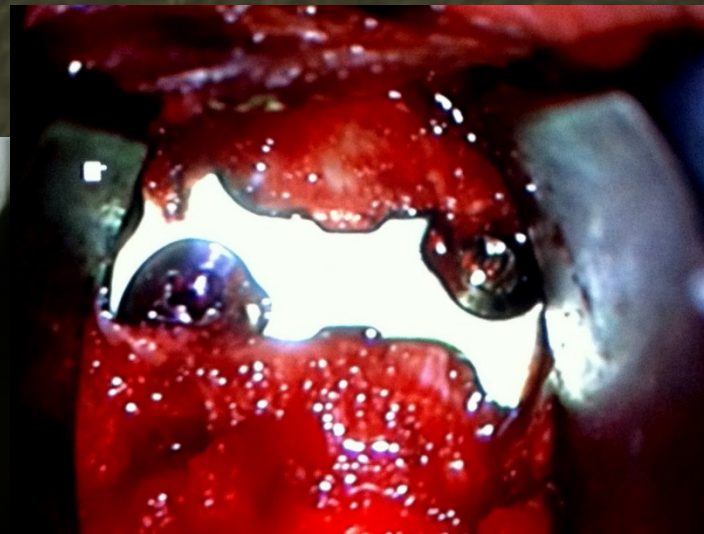
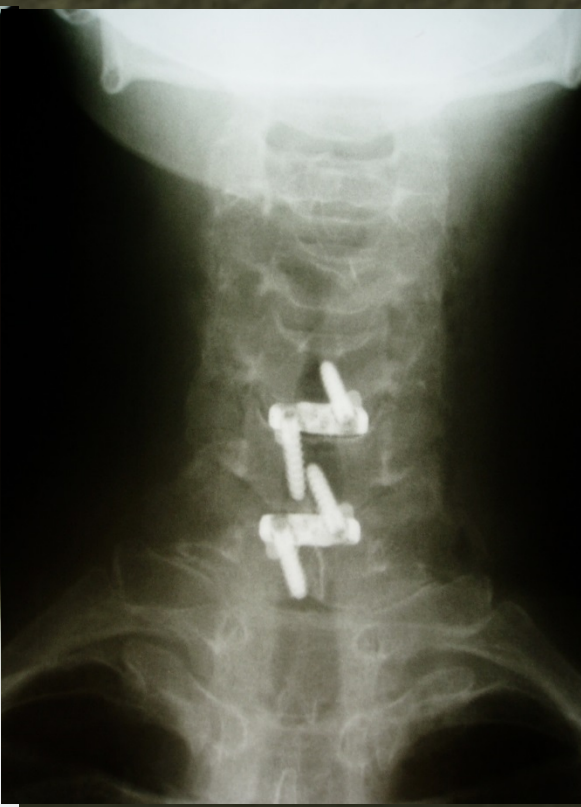
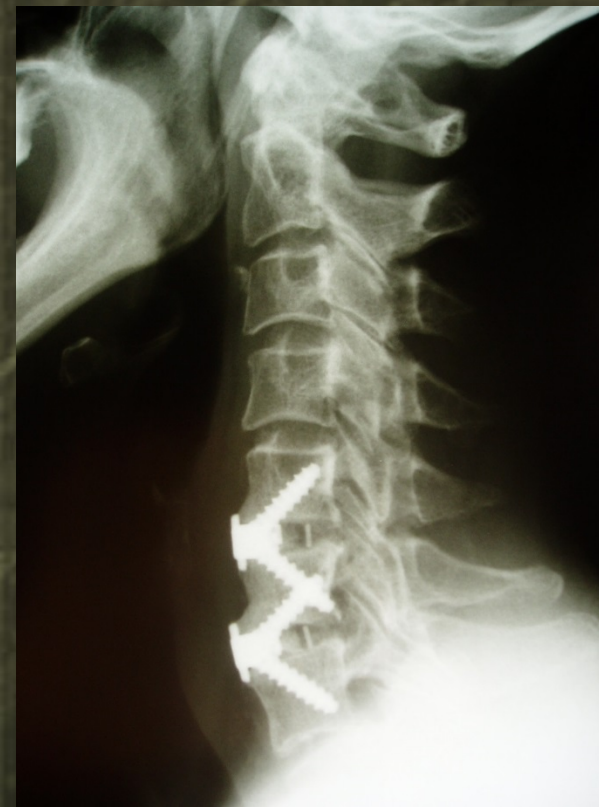
ALA



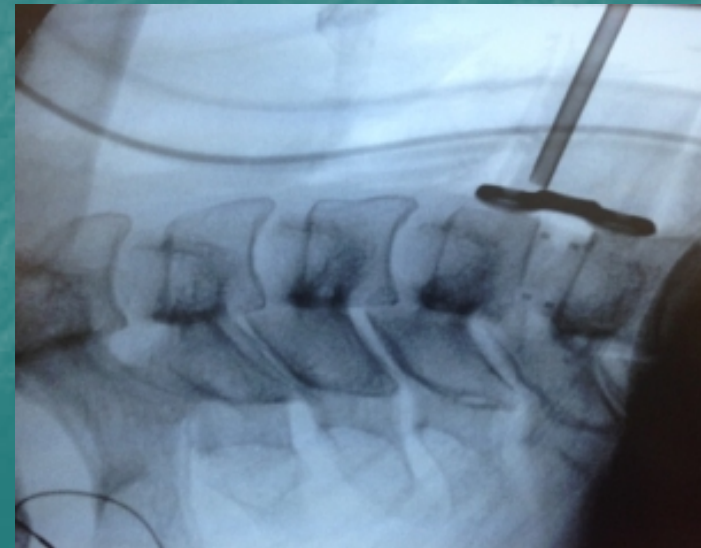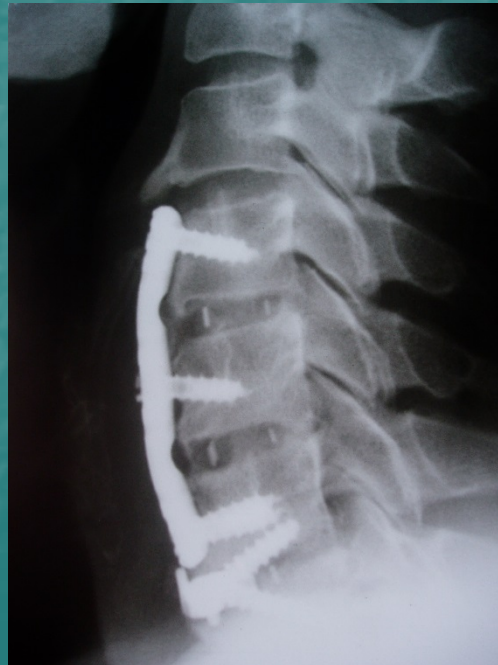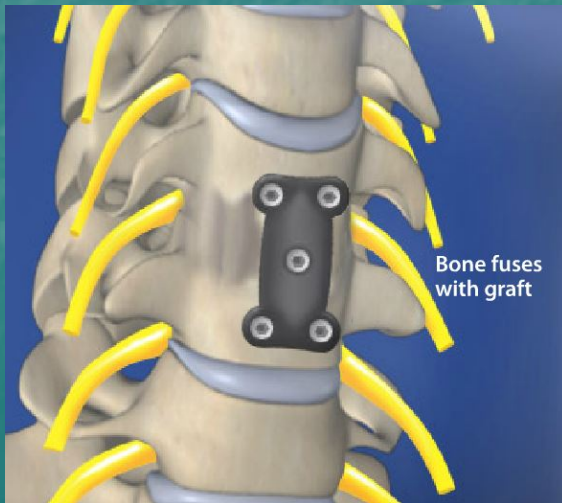
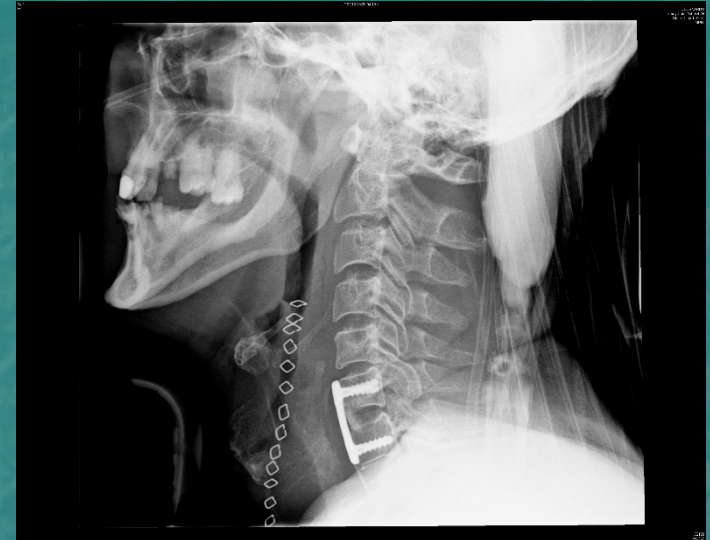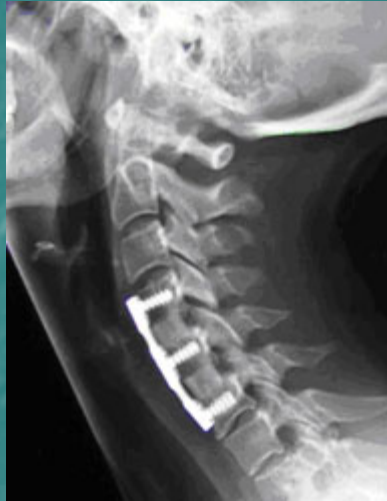
Totálna artroplastika krčnej chrbtice



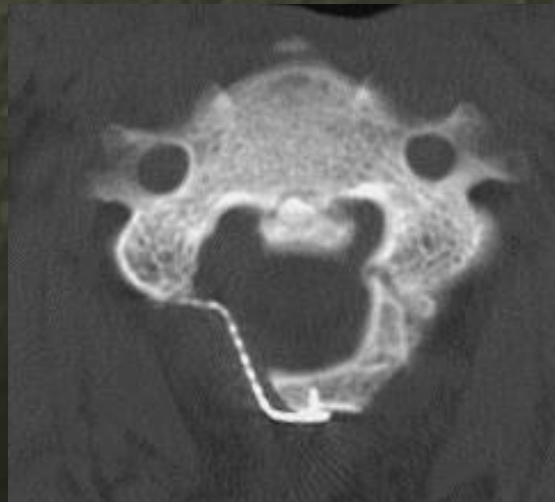
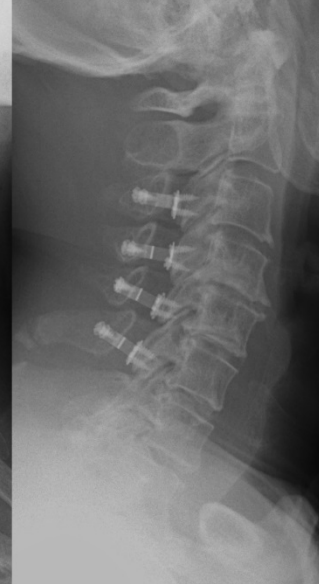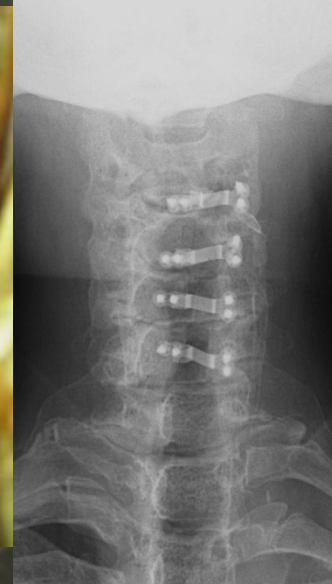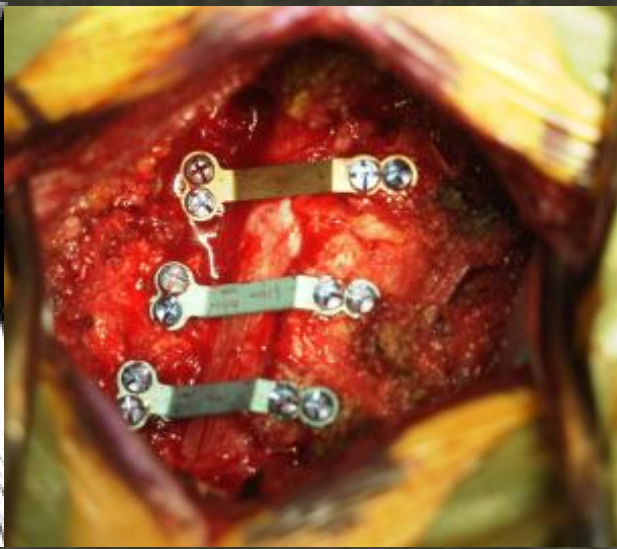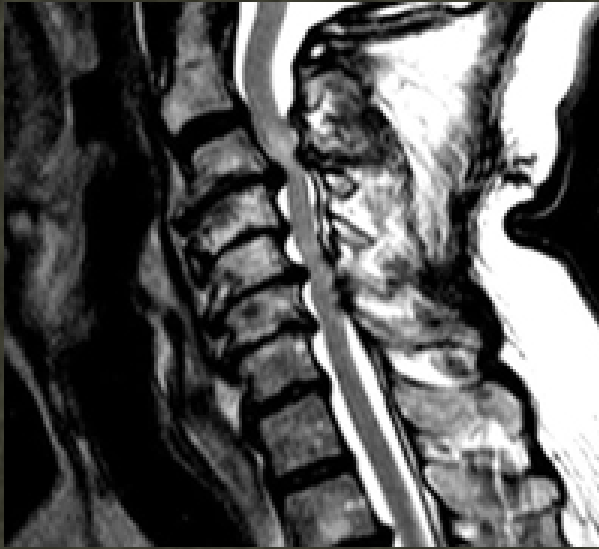Implantáty s integrovanou krčnou dlahou



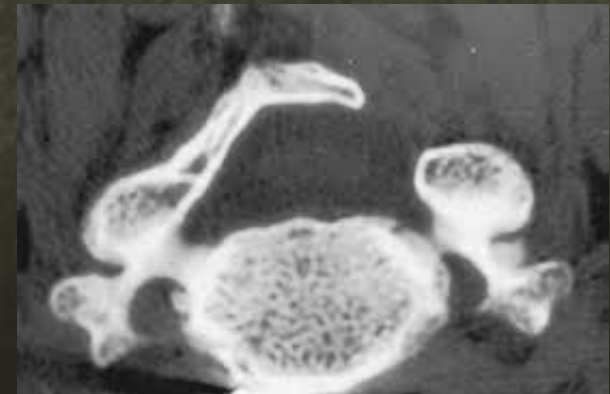
ACIF klietka + dlaha



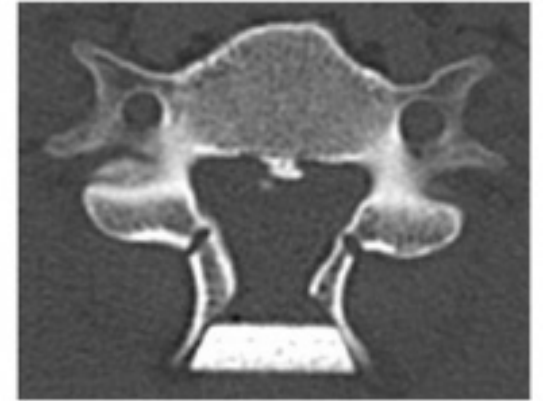
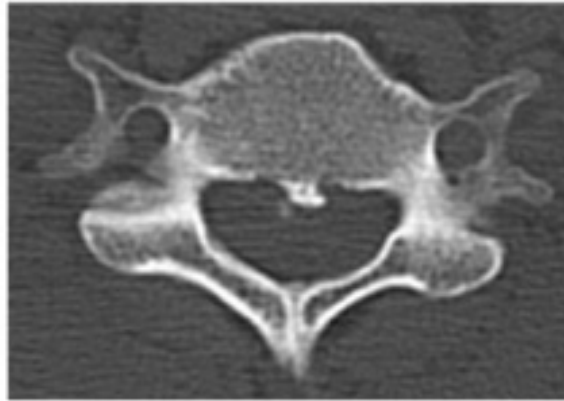
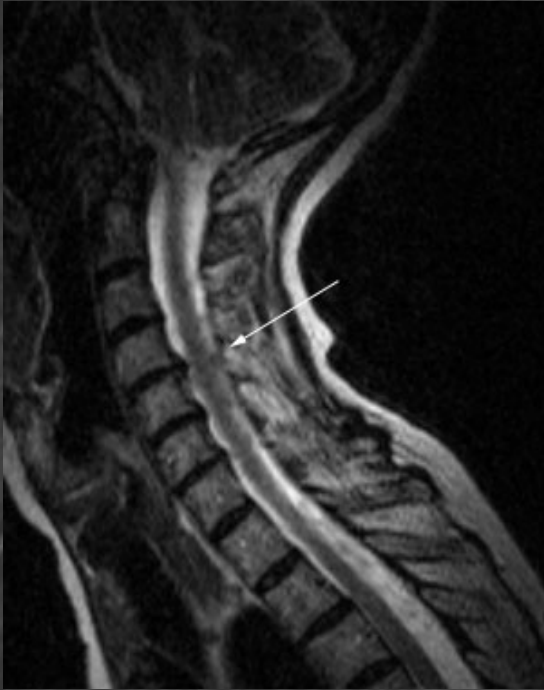Degeneratívna stenóza krčnej chrbtice



Open door



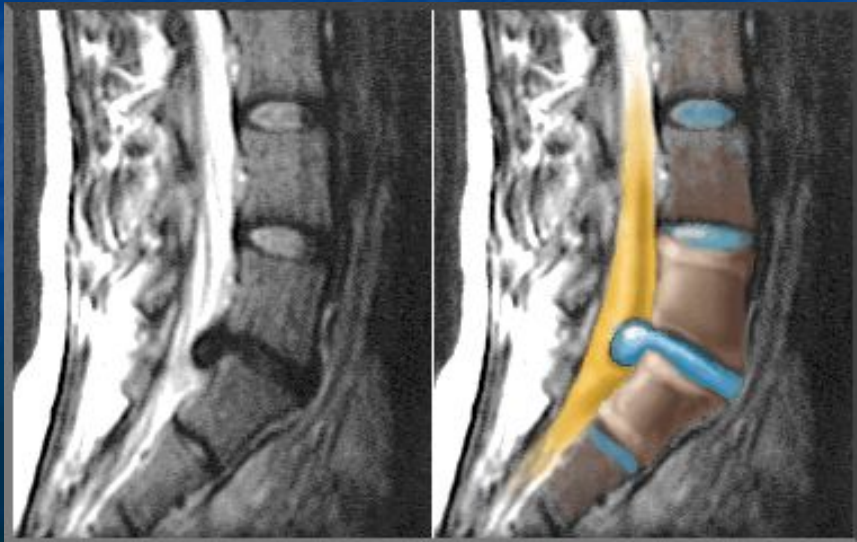
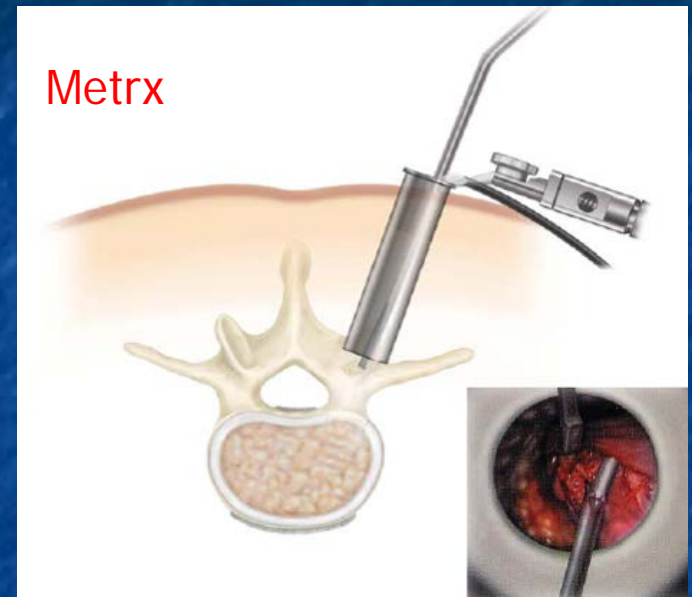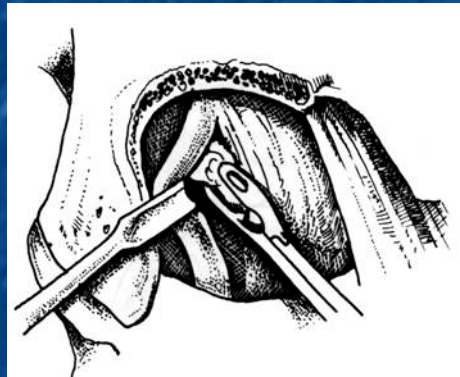
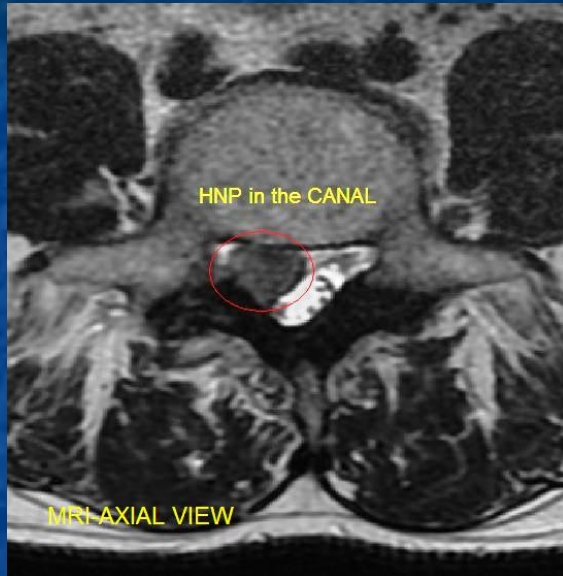
Degeneratívna stenóza krčnej chrbtice



Double open door /french door/

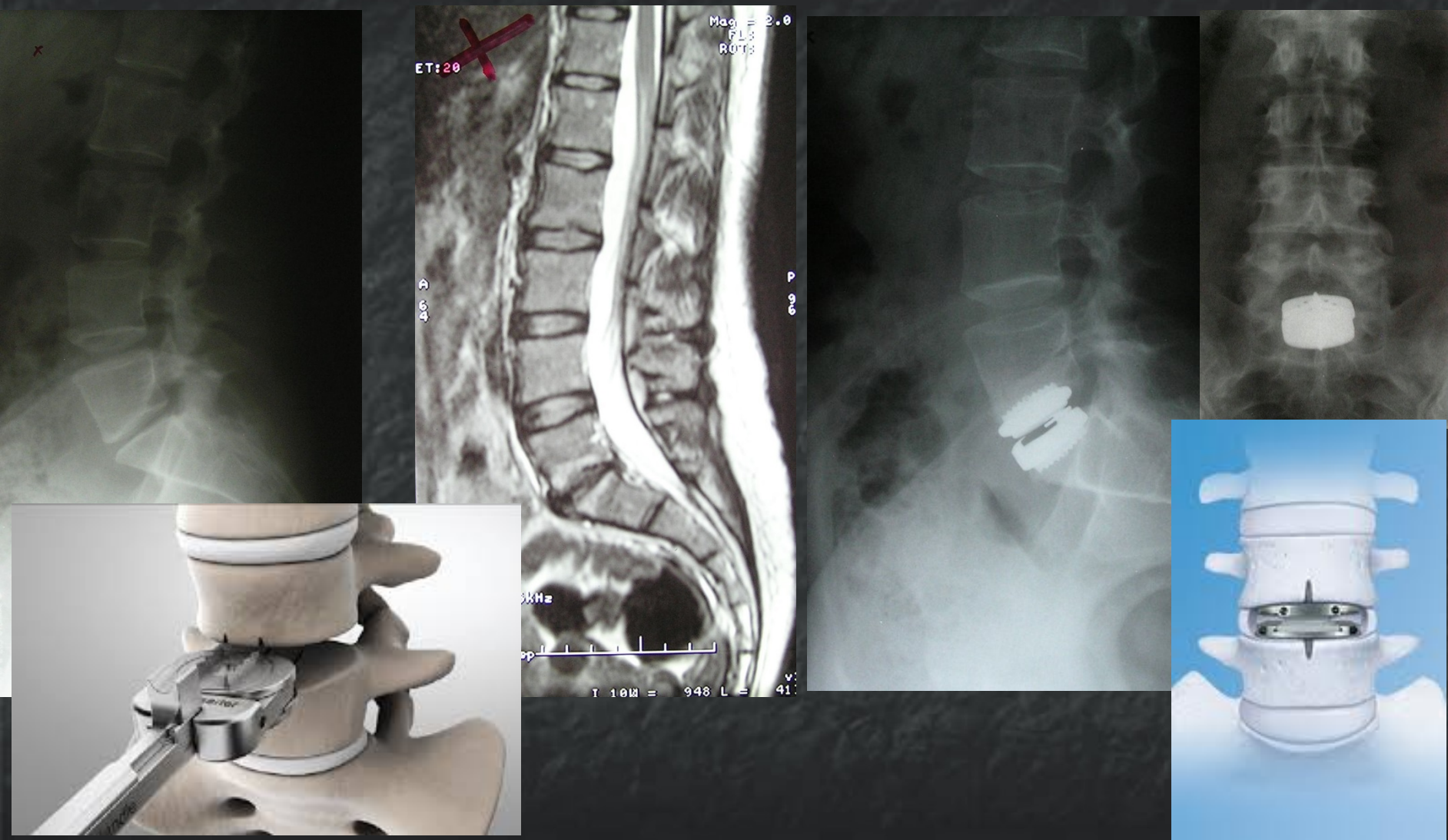

Degeneratívne ochorenie lumbálnej chrbtice



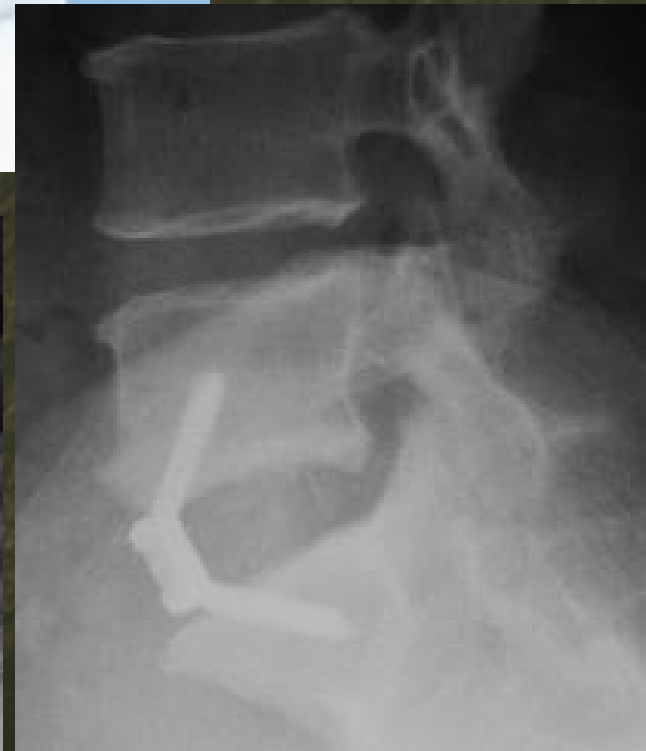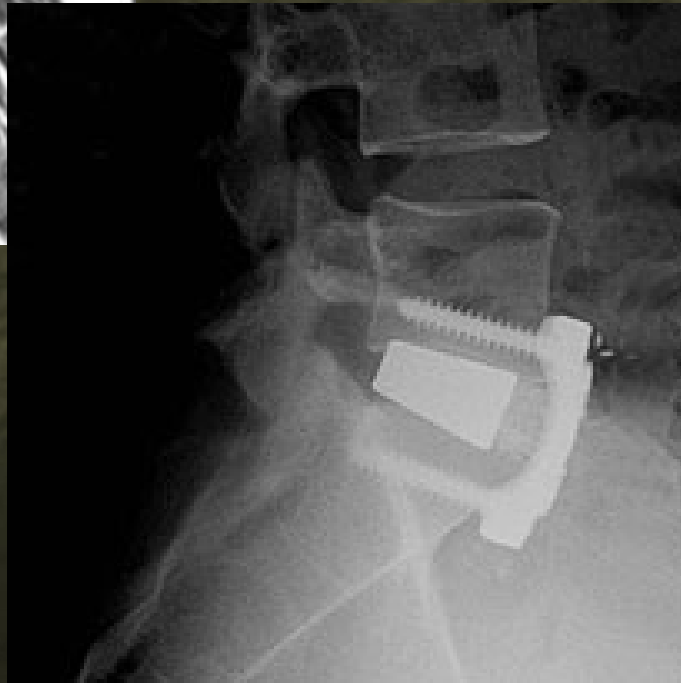
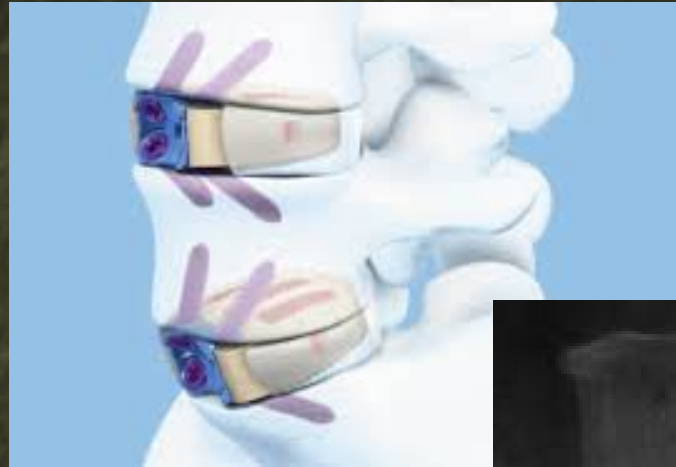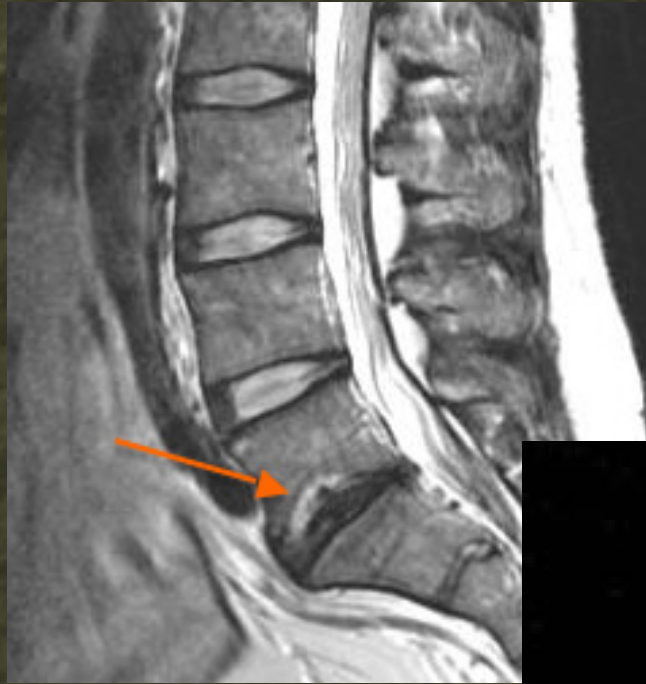Lumbálna mikrodiskektómia

Degeneratívne ochorenie lumbálnej chrbtice



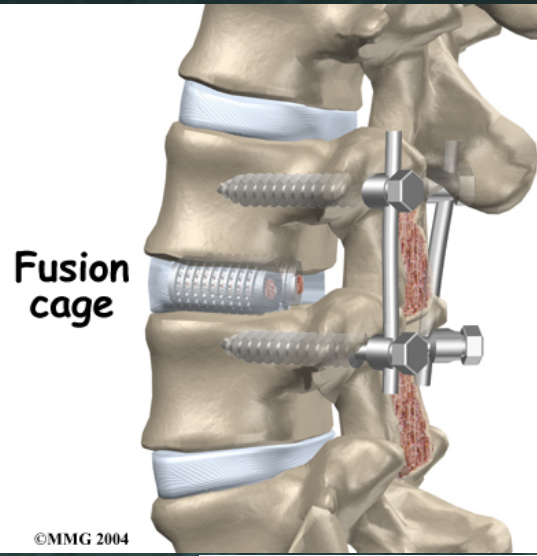
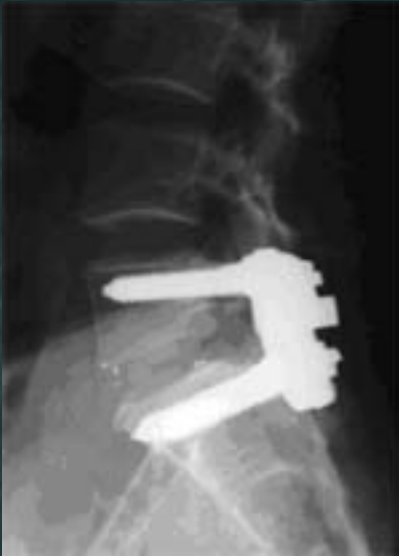Arteficiálny lumbálny disk /totálna artroplastika/

Degeneratívne ochorenie lumbálnej chrbtice

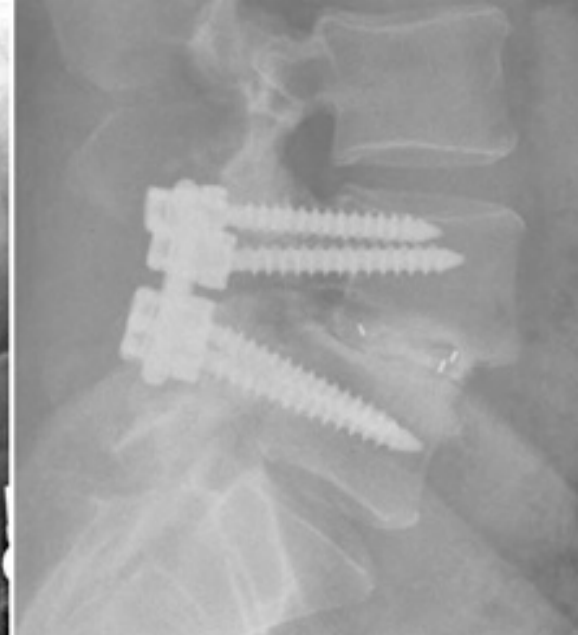
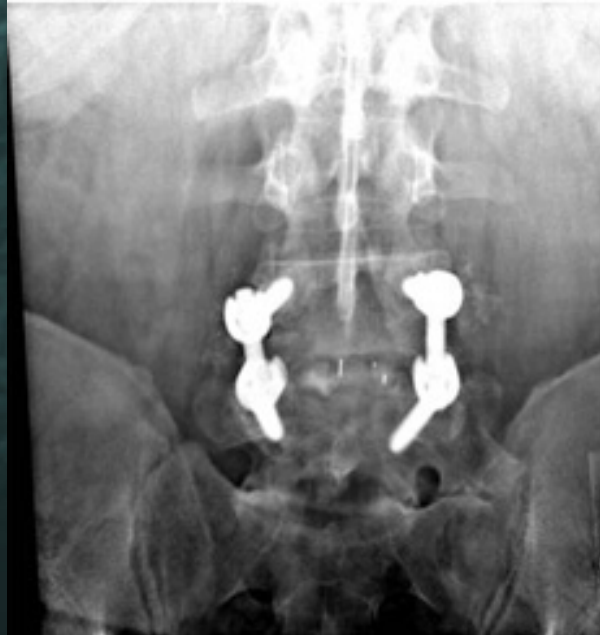

ALIF

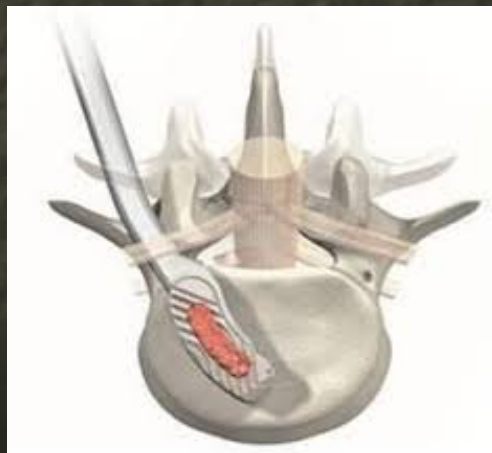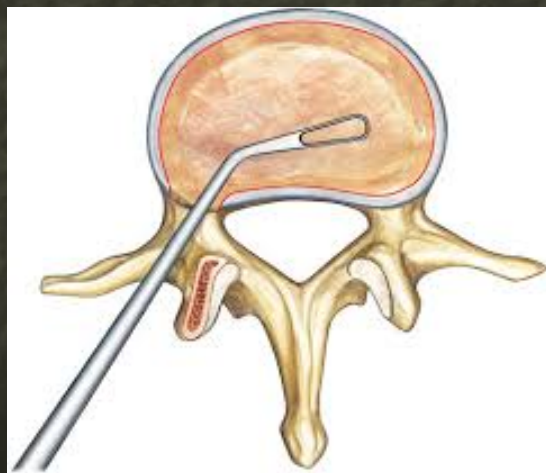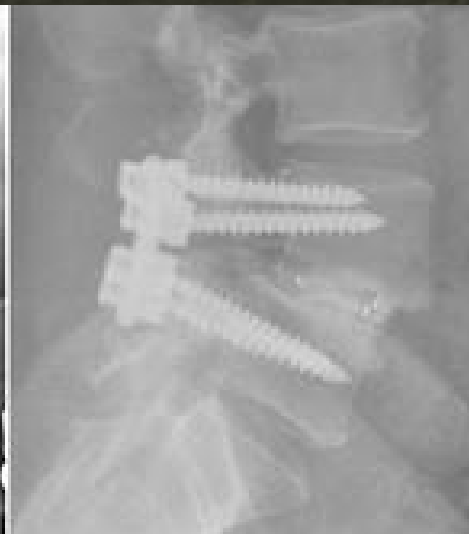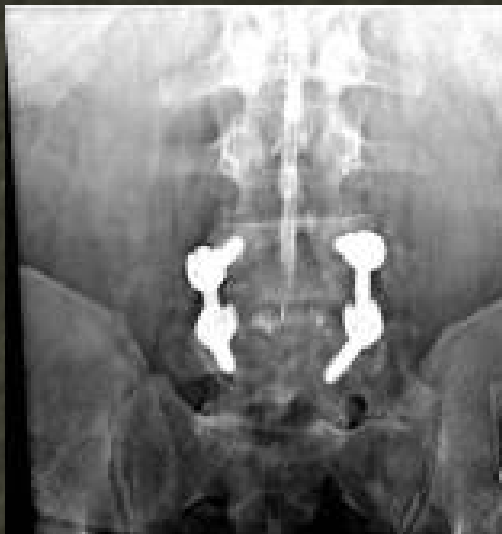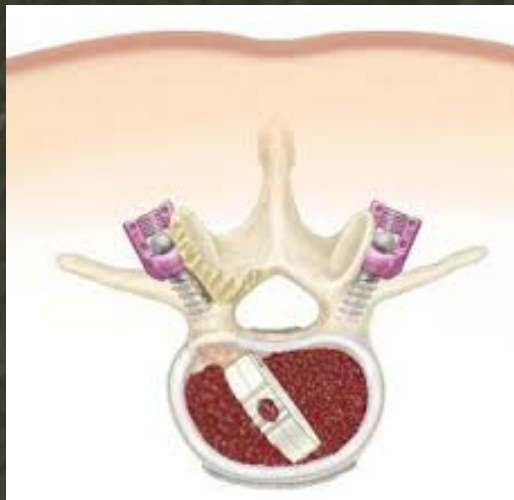Degeneratívne ochorenie lumbálnej chrbtice



PLIF

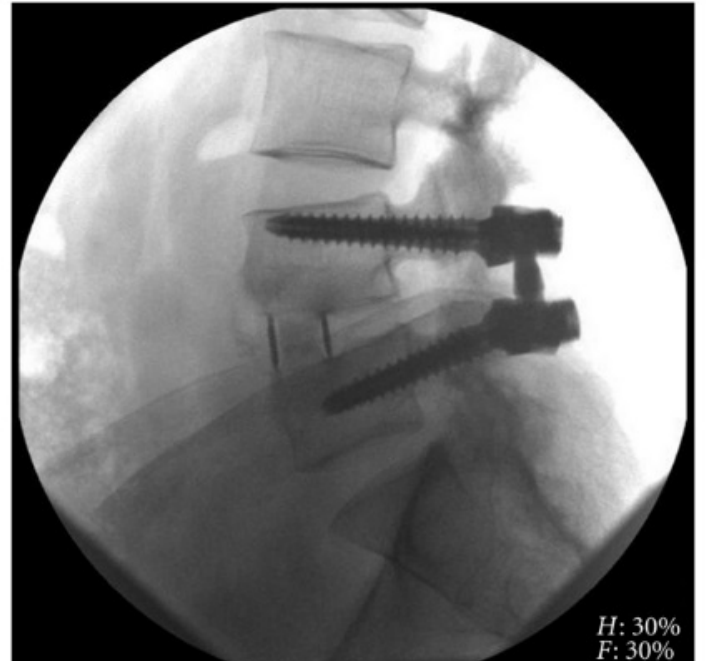
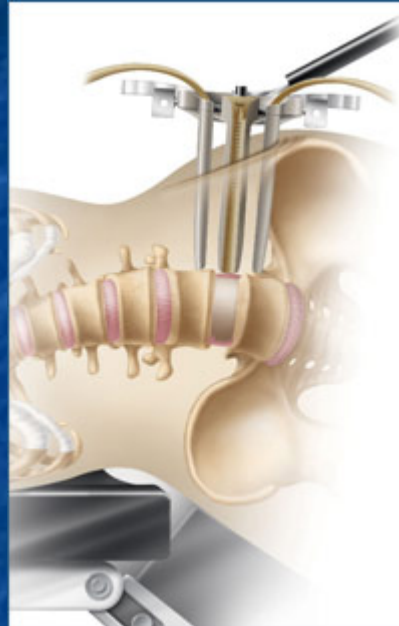
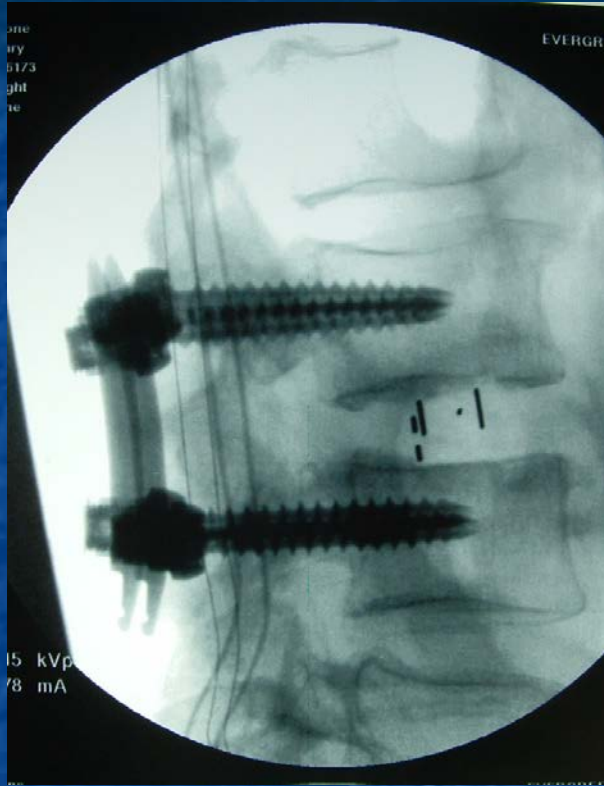


Degeneratívne ochorenie lumbálnej chrbtice

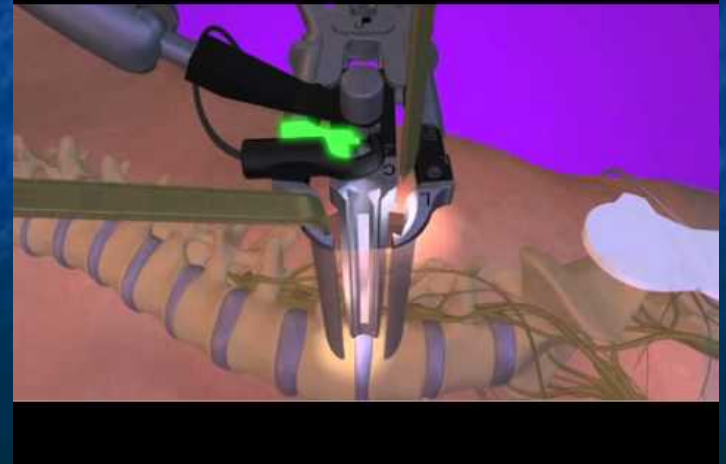


TLIF

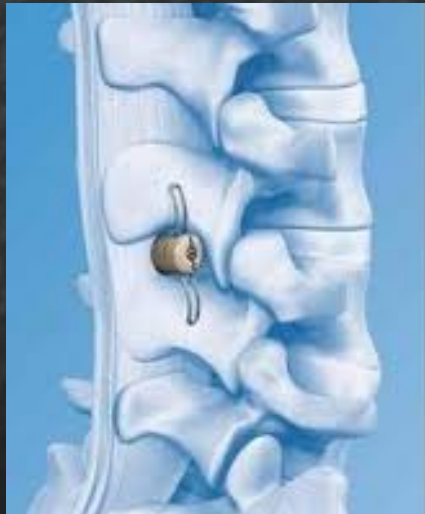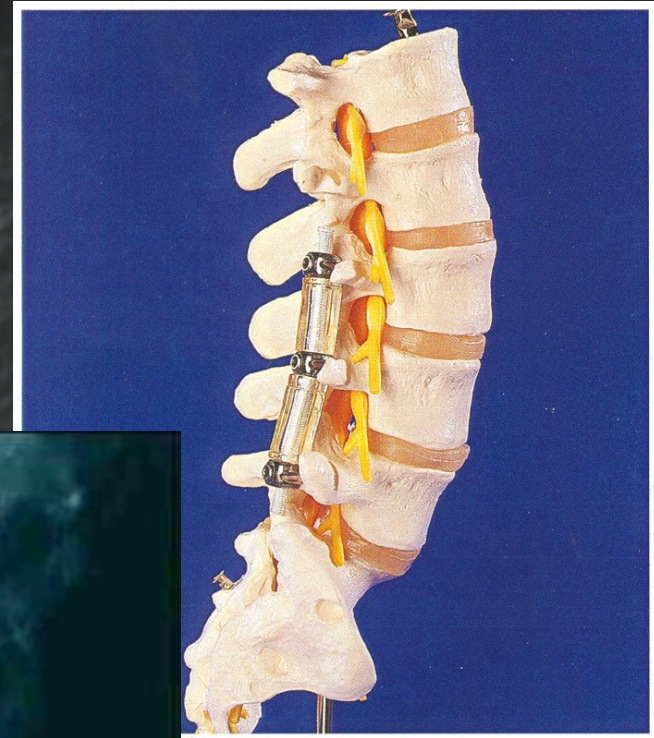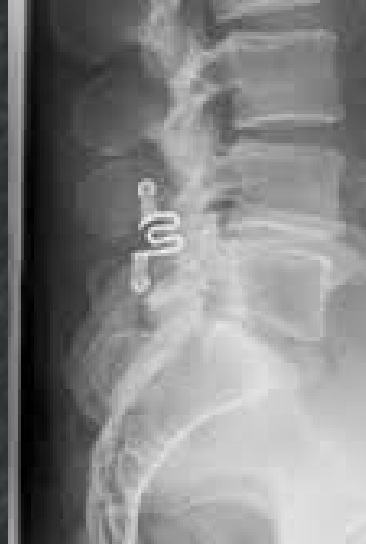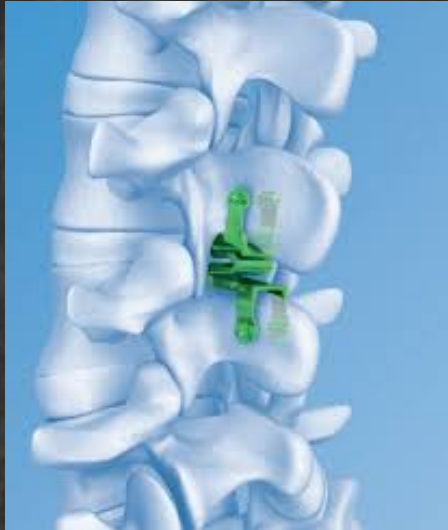Degeneratívne ochorenie lumbálnej chrbtice



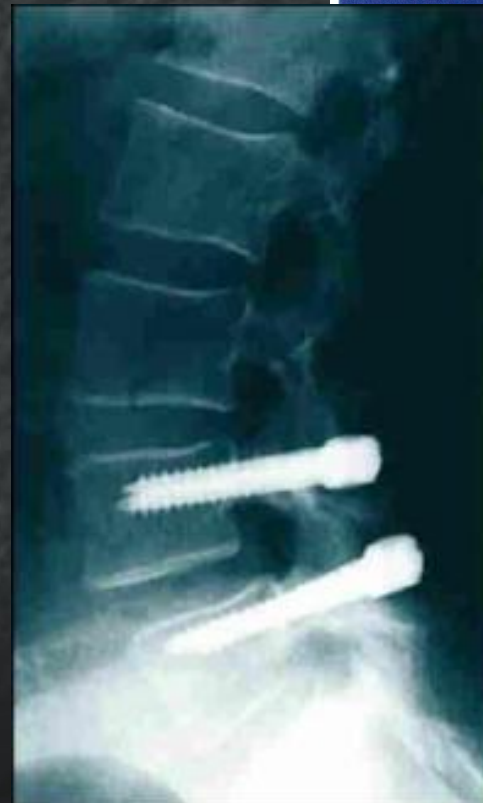XLIF /DLIF/



Degeneratívne ochorenie lumbálnej chrbtice

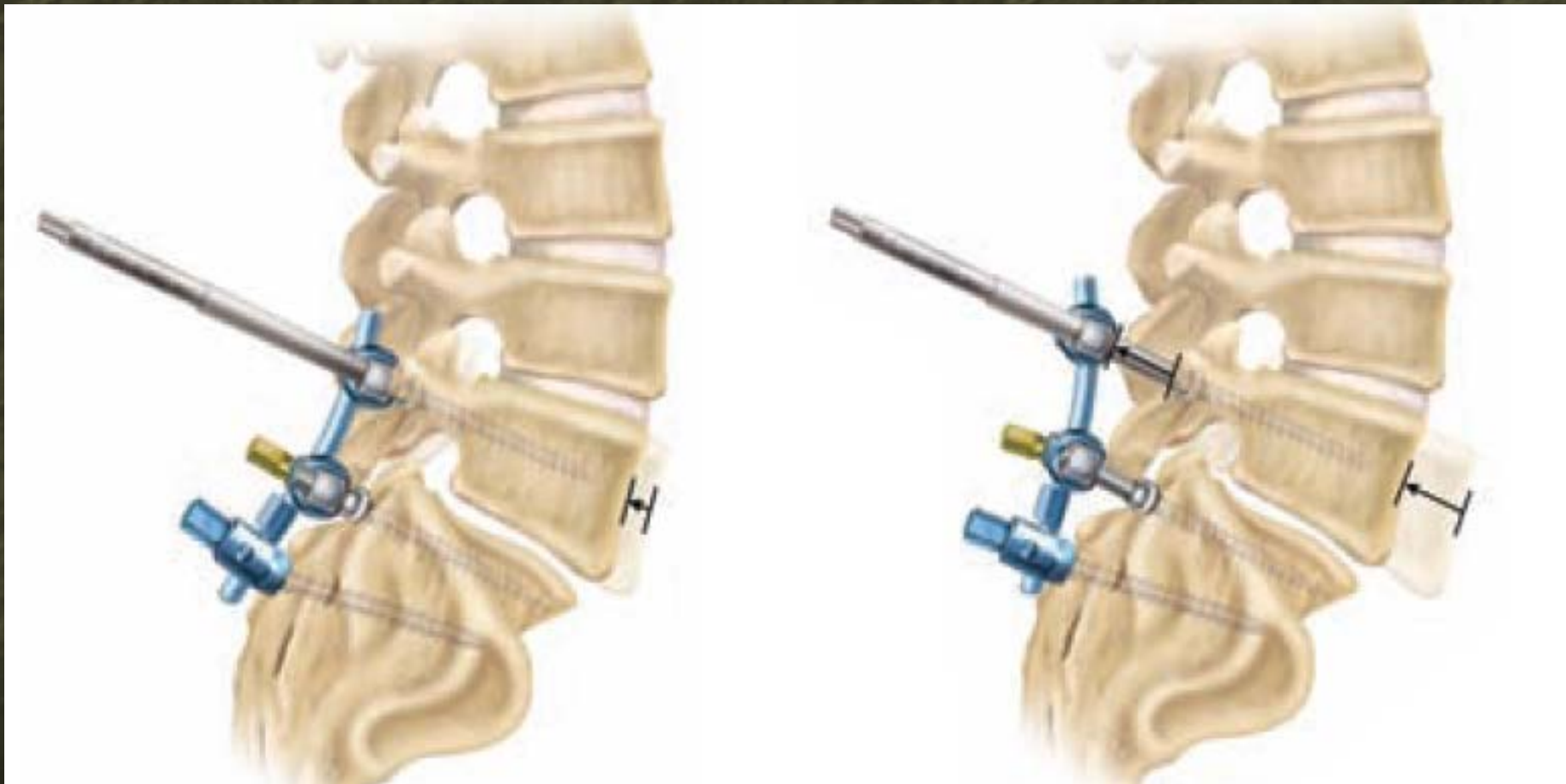


Interspinózna
neutralizácia

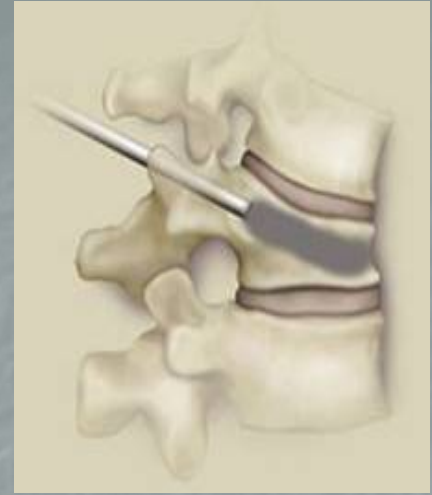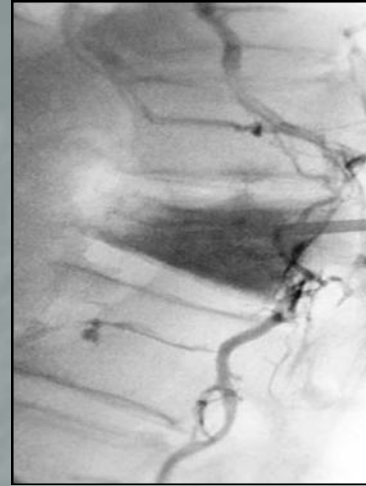

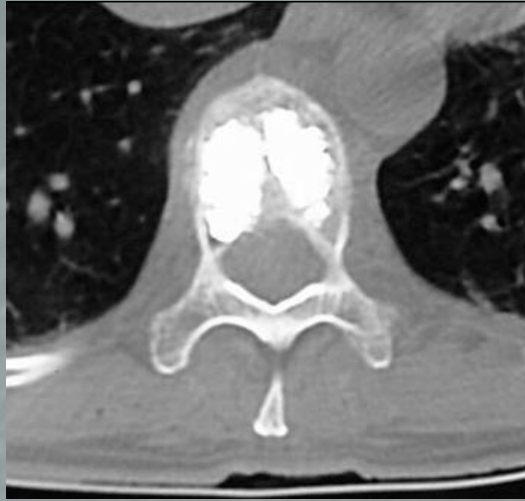
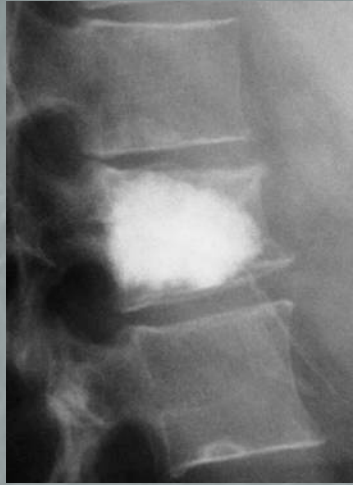Transpedikulárna
neutralizácia

Repozícia spondylolistézy

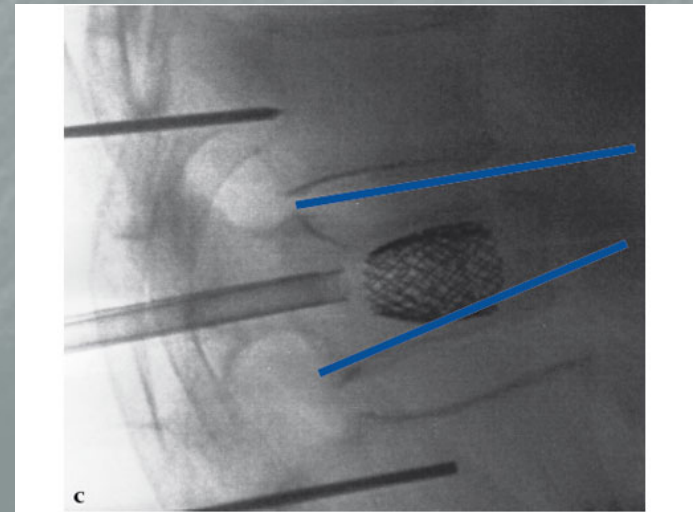
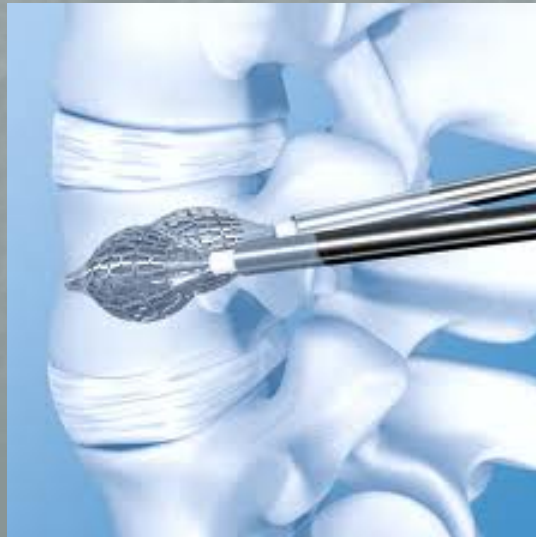
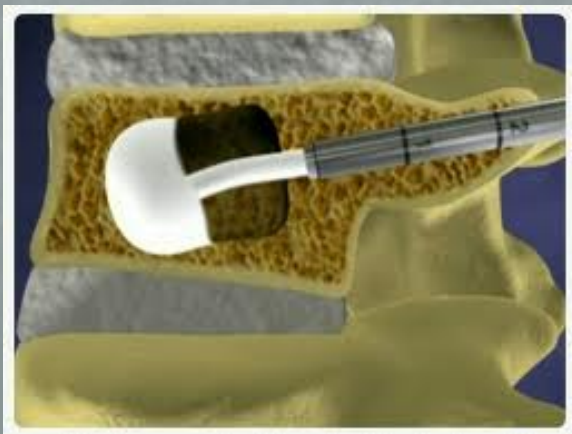
Vertebroplastika

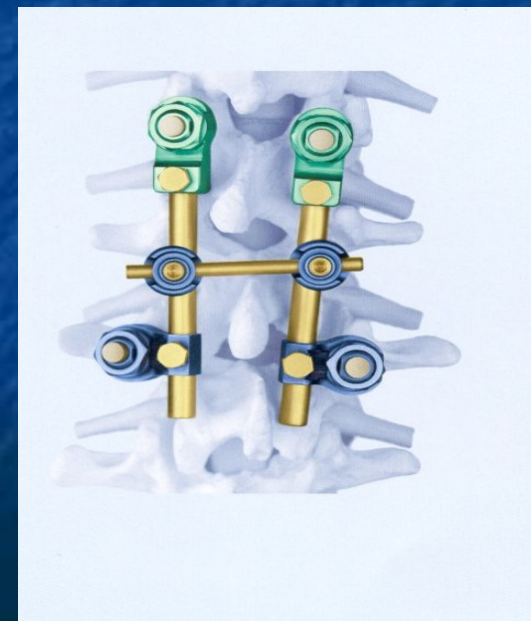
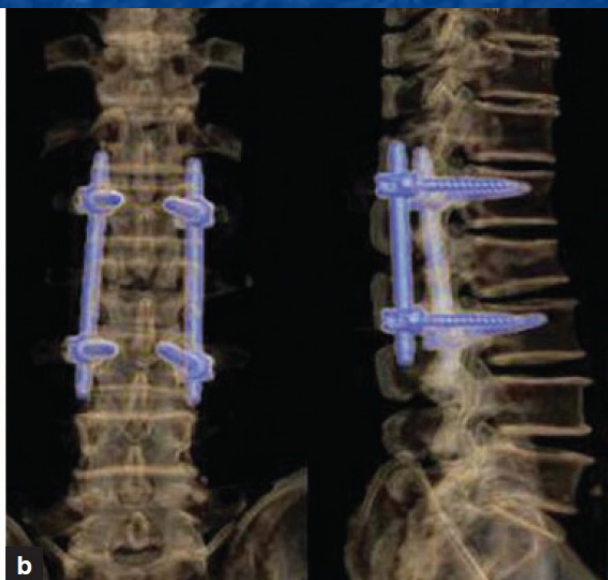
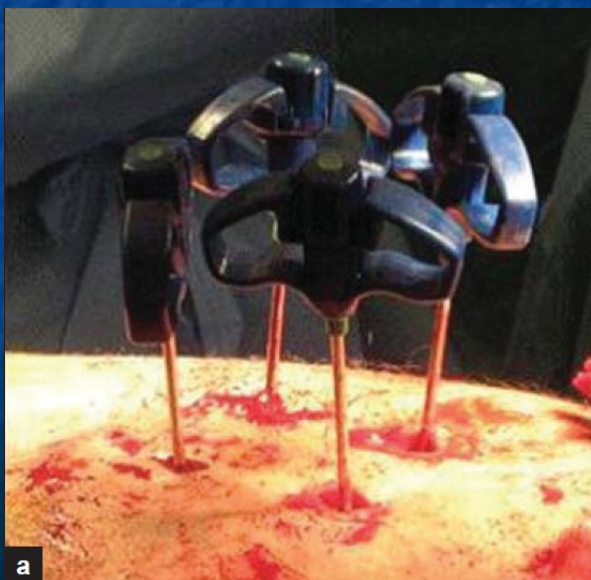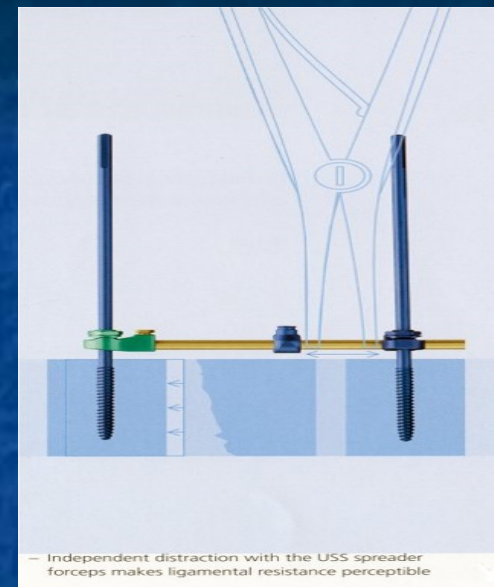
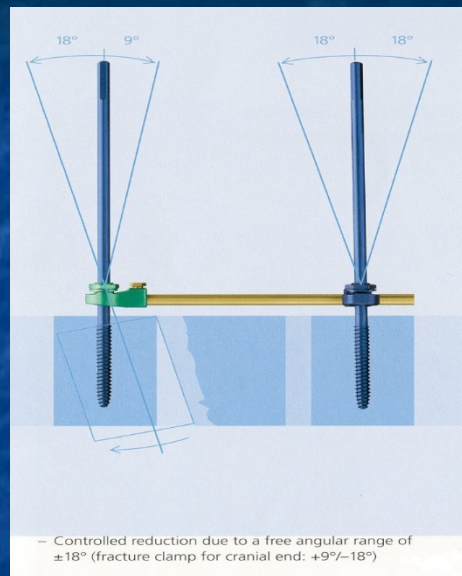

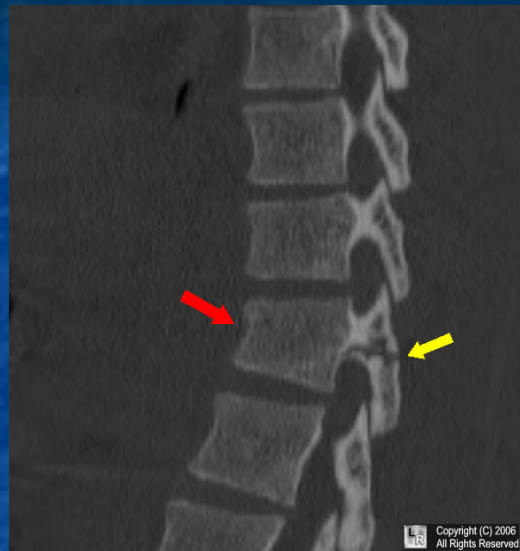
VBS

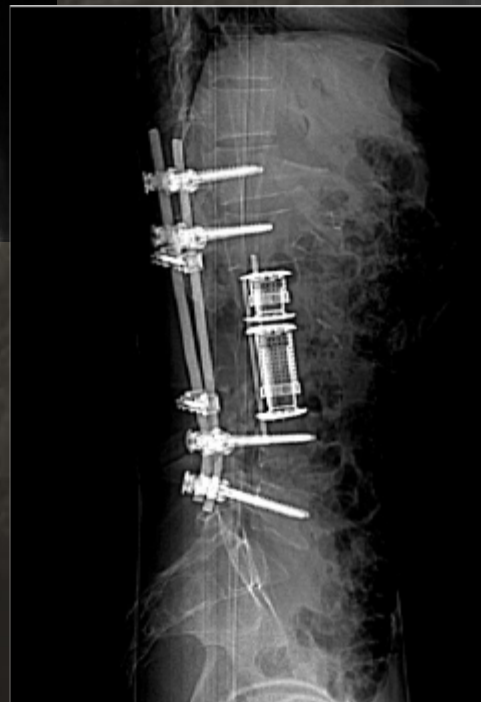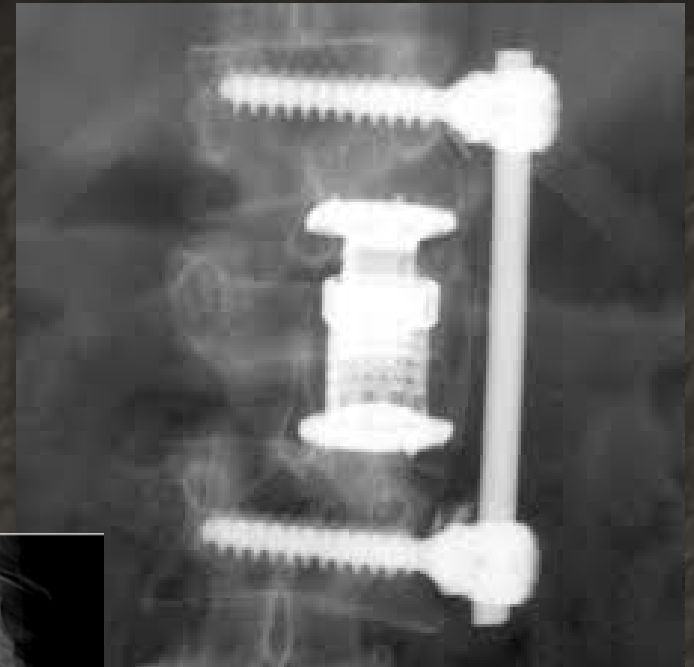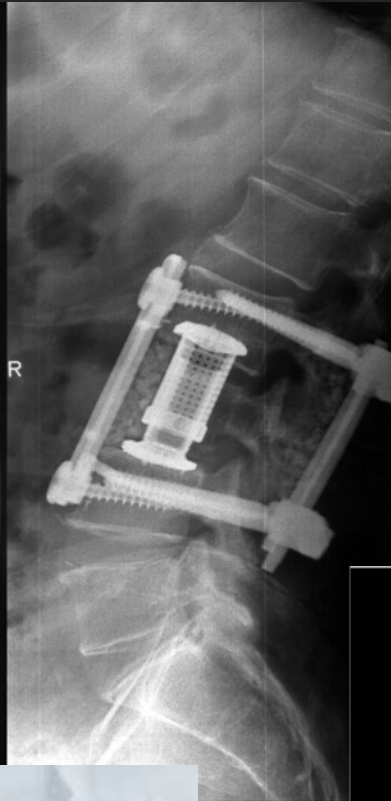
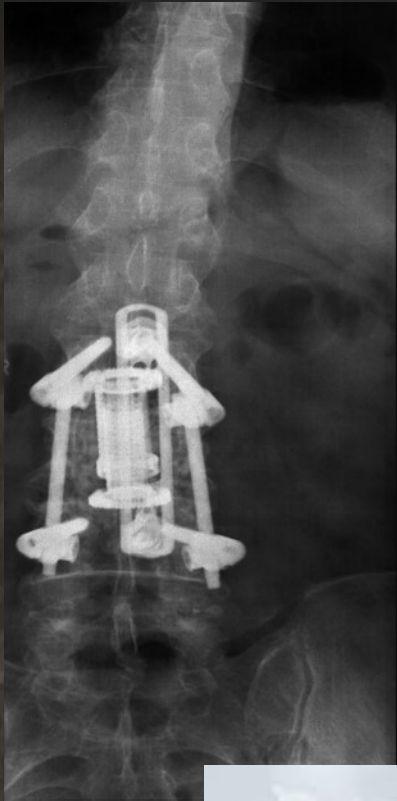
Kyfoplastika



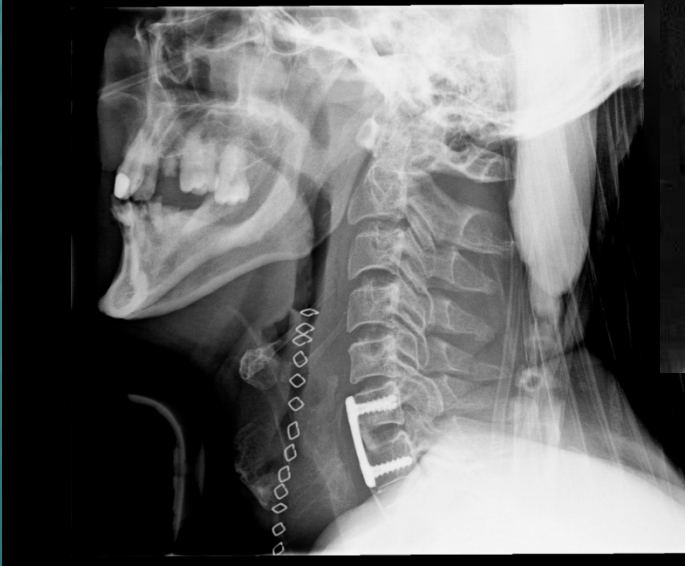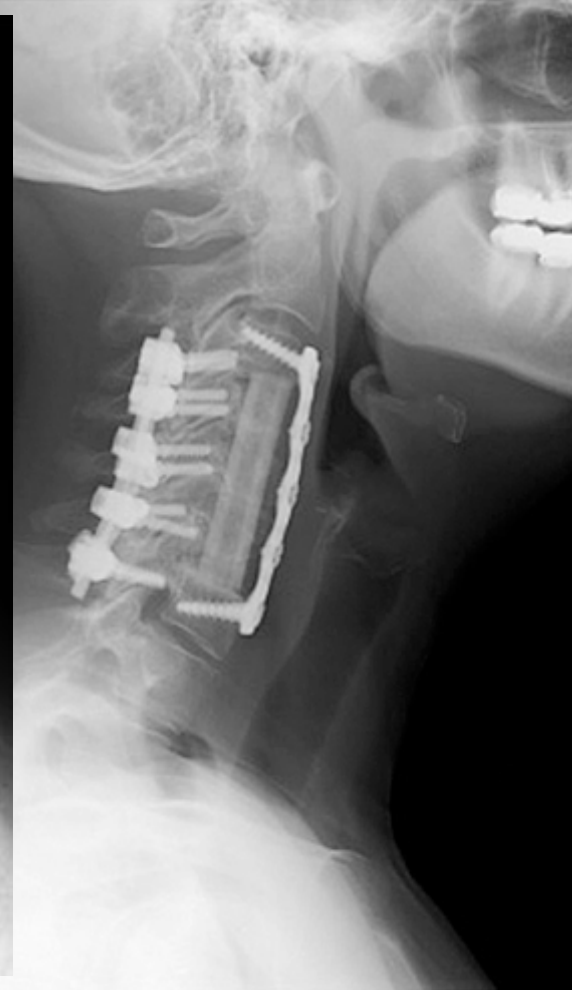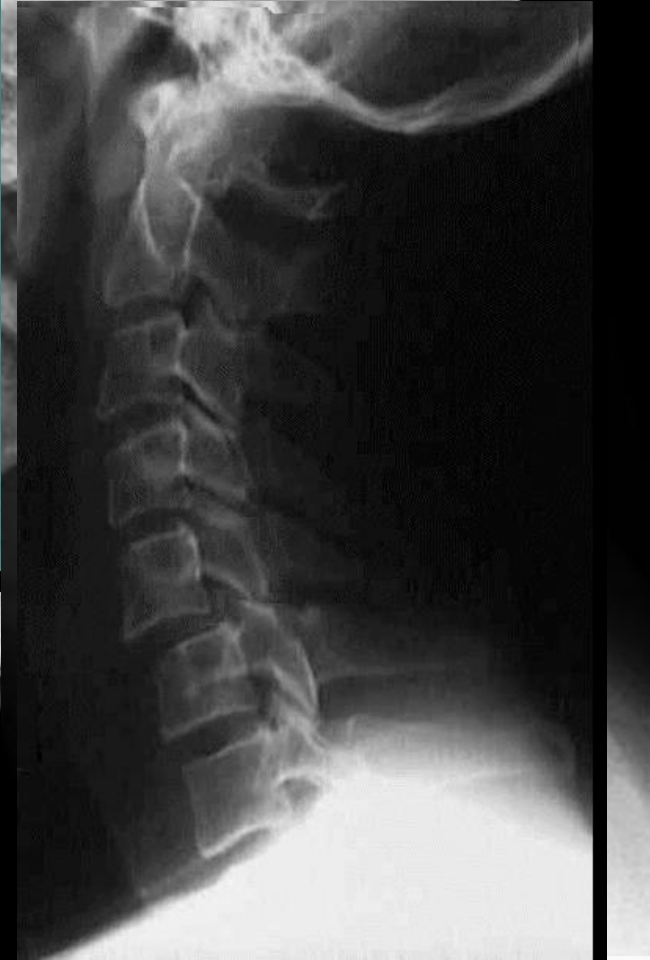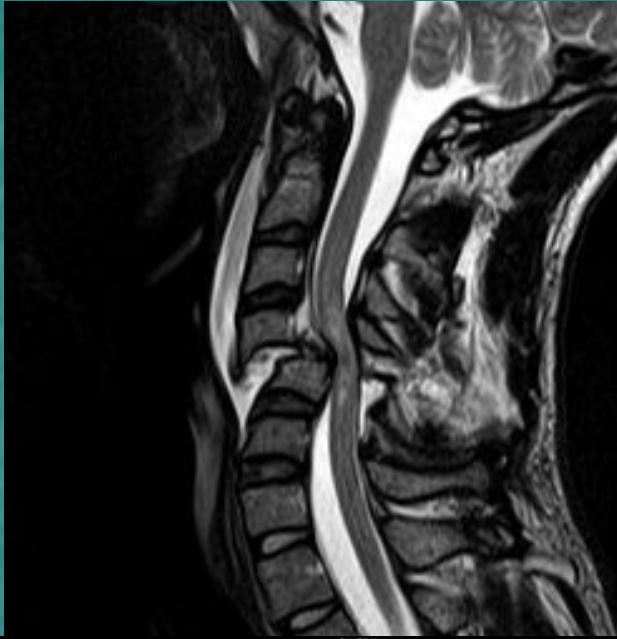Transpedikulárna stabilizácia pri úrazoch chrbtice

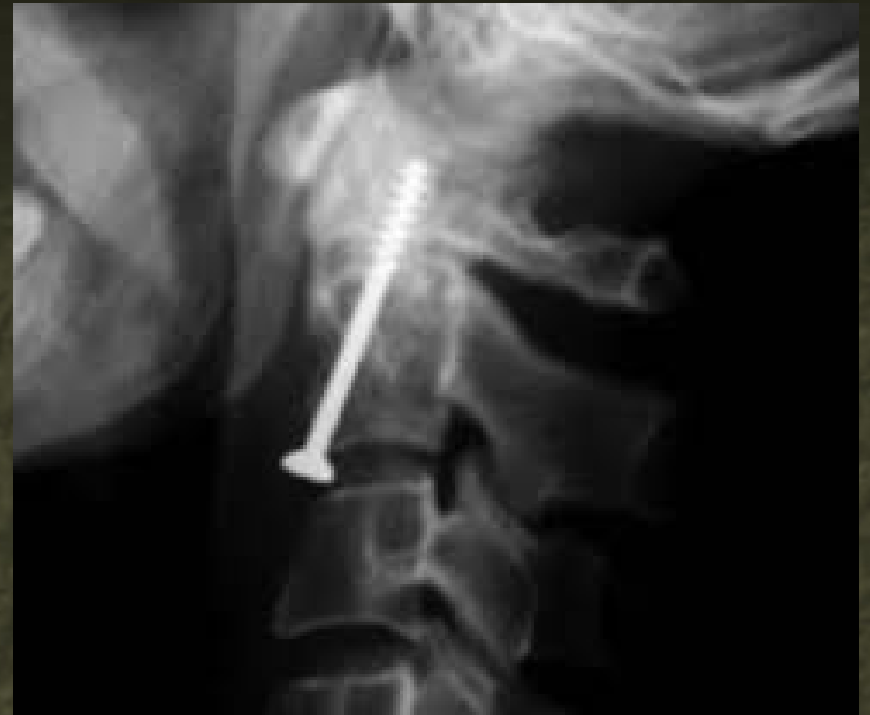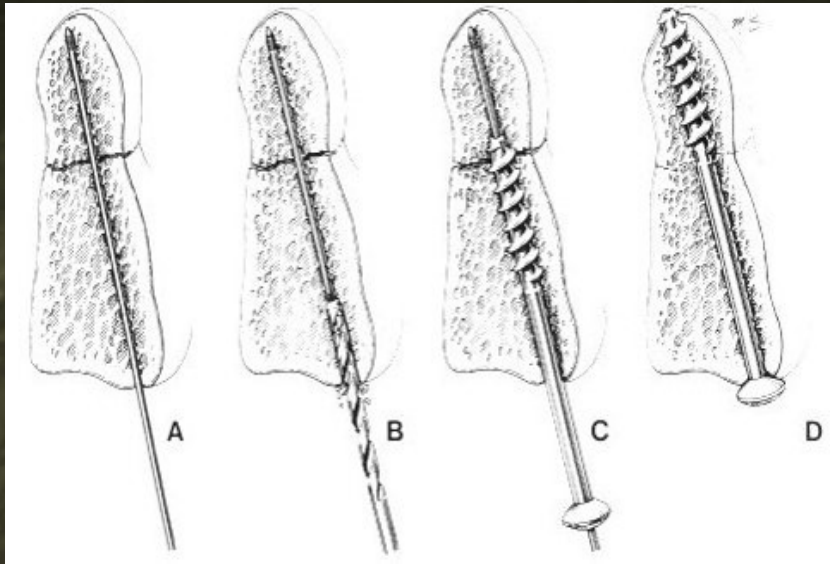


360 st. stabilizácia a spondylodéza

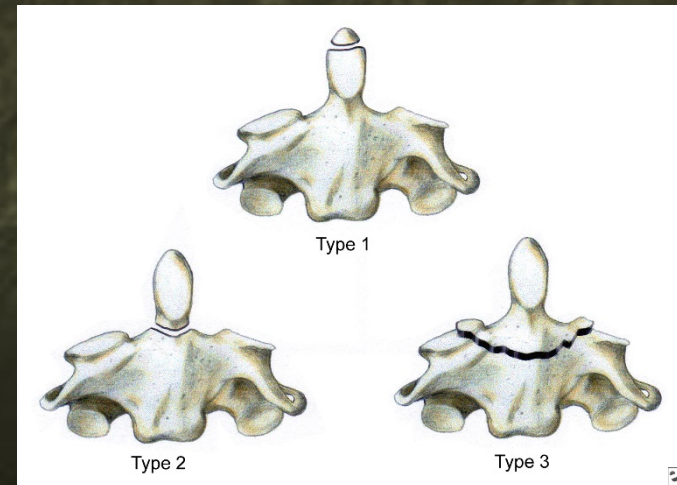
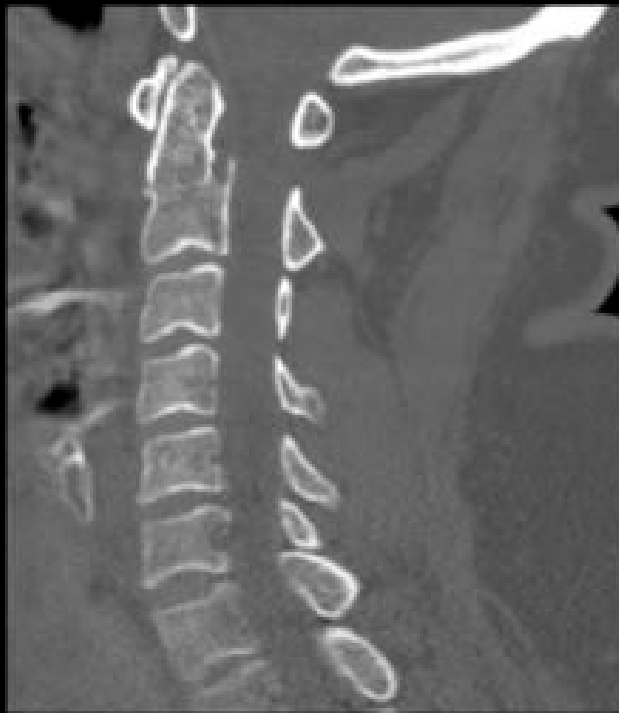

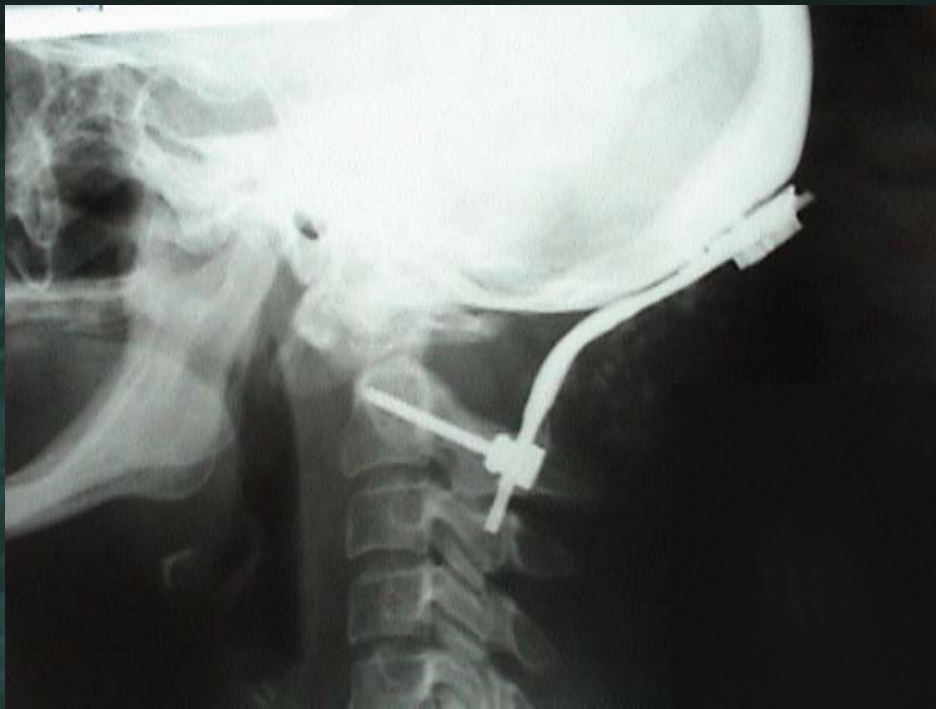Poranenia subaxiálnej krčnej chrbtice



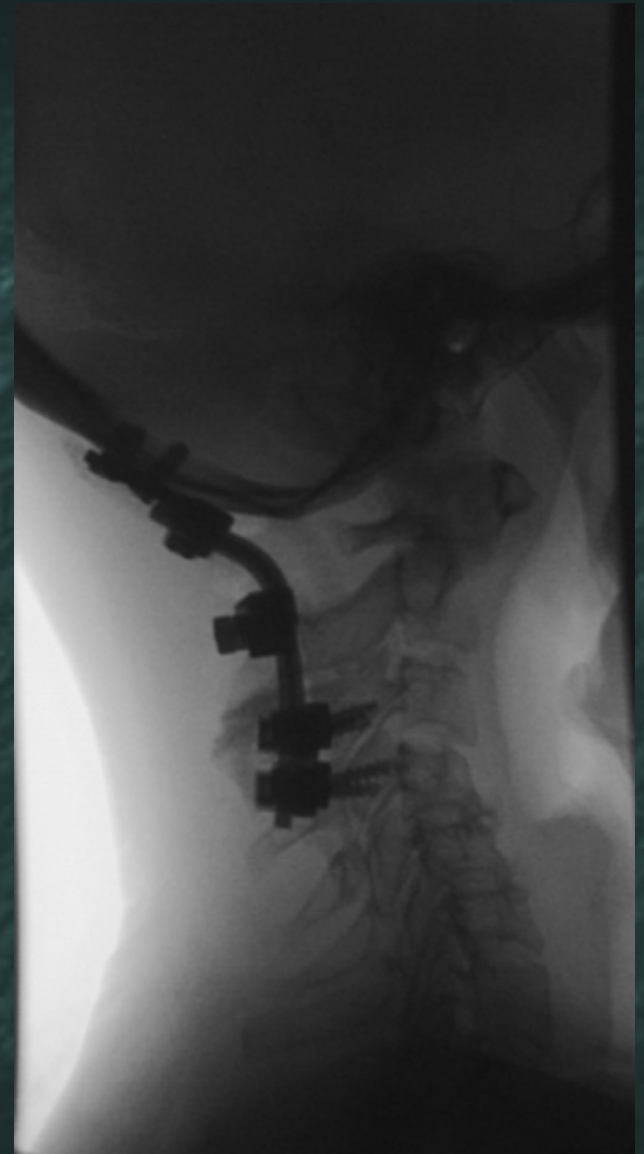
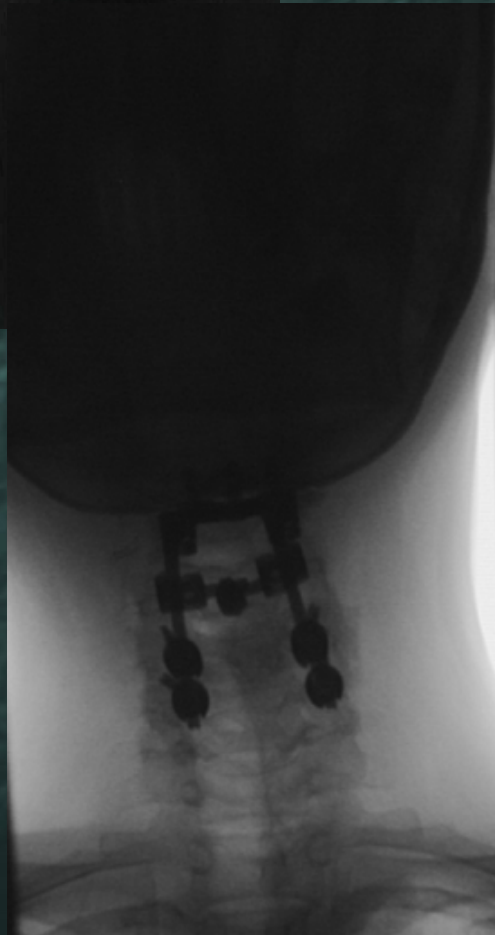


Kompresívna osteosyntéza densu podľa Boehlera





Cerviko-okcipitálna
stabilizácia



Ďakujem za pozornosť

