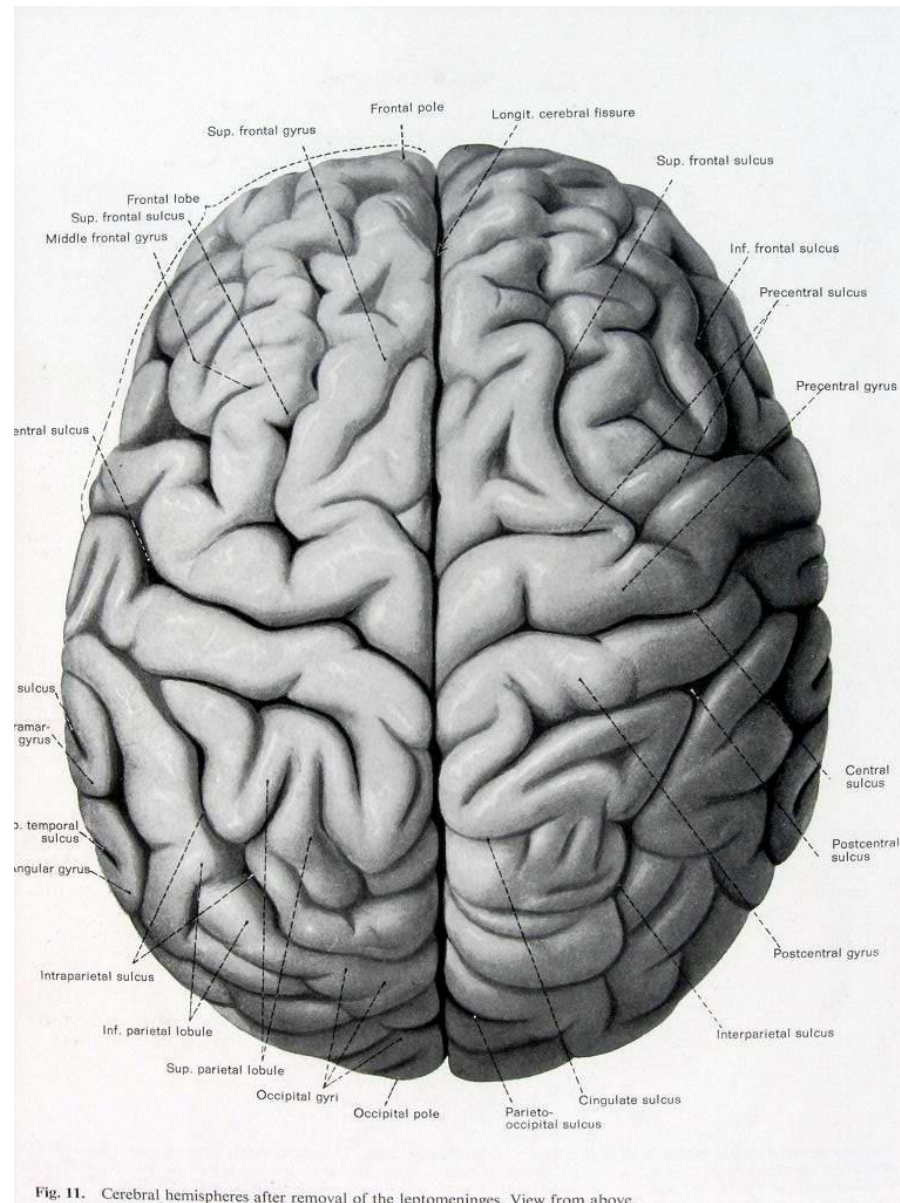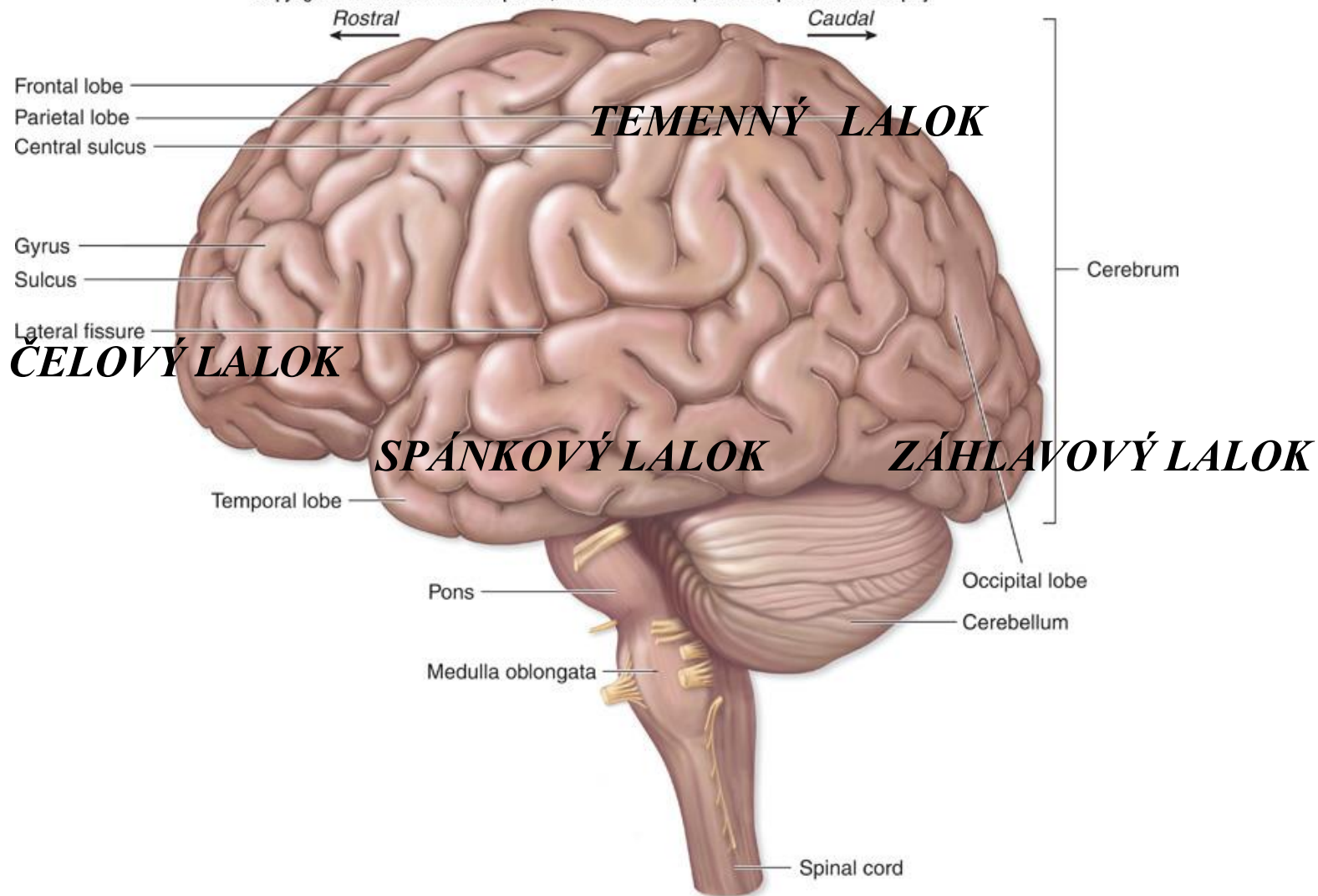


Fig. 11. Cerebral hemispheres after removal of the leptomeninges. View from above.

Copyright © The McGraw-Hill Companies, Inc. Permission required for reproduction or display.



(a) Left lateral view

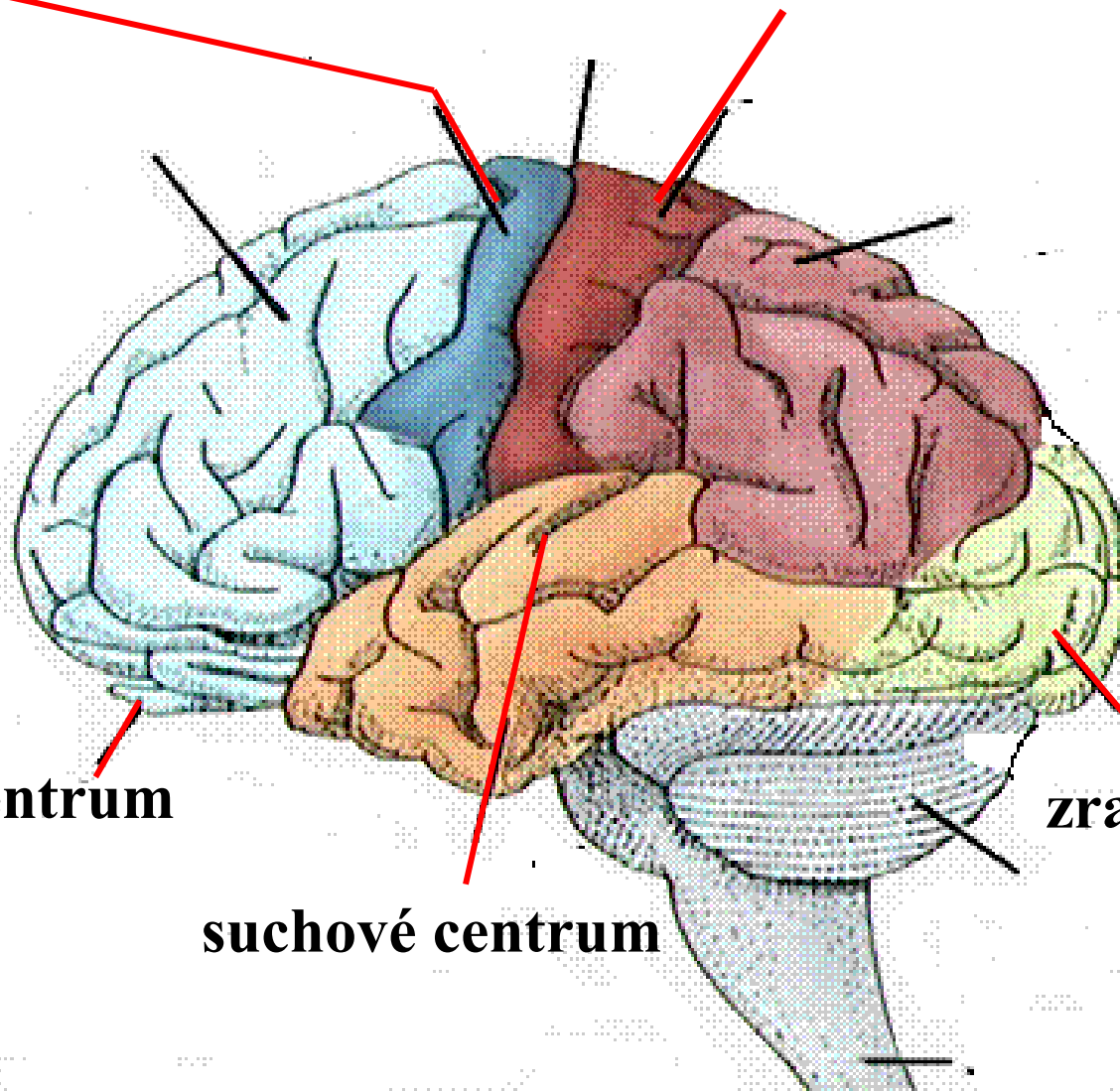
centrum hybnosti

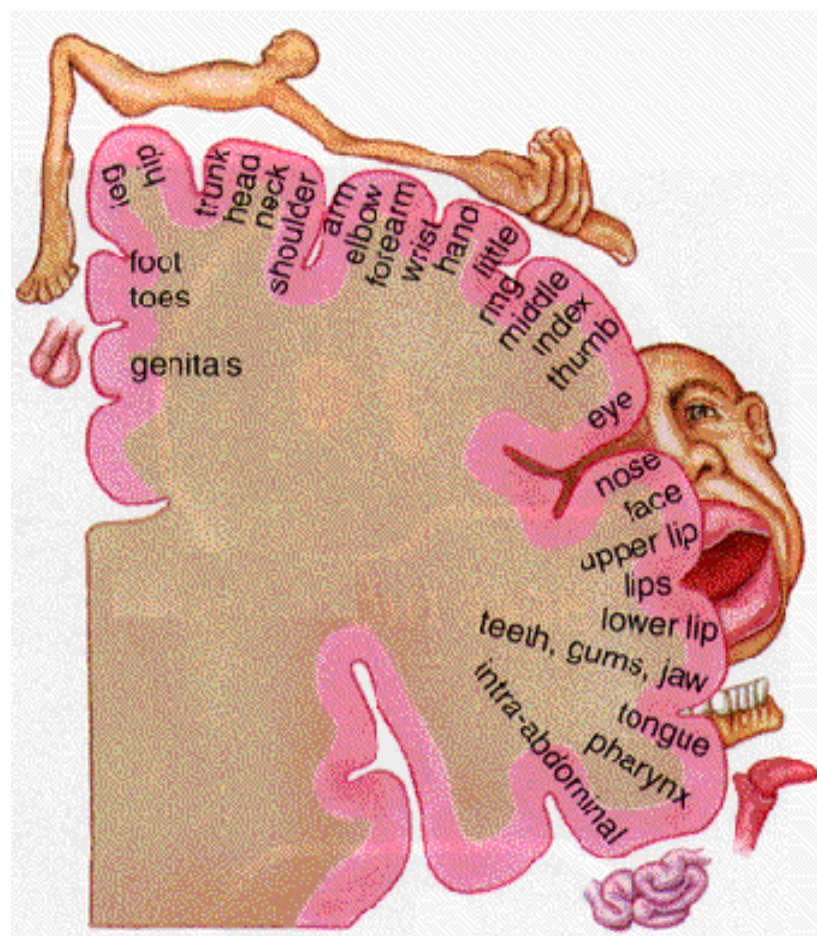
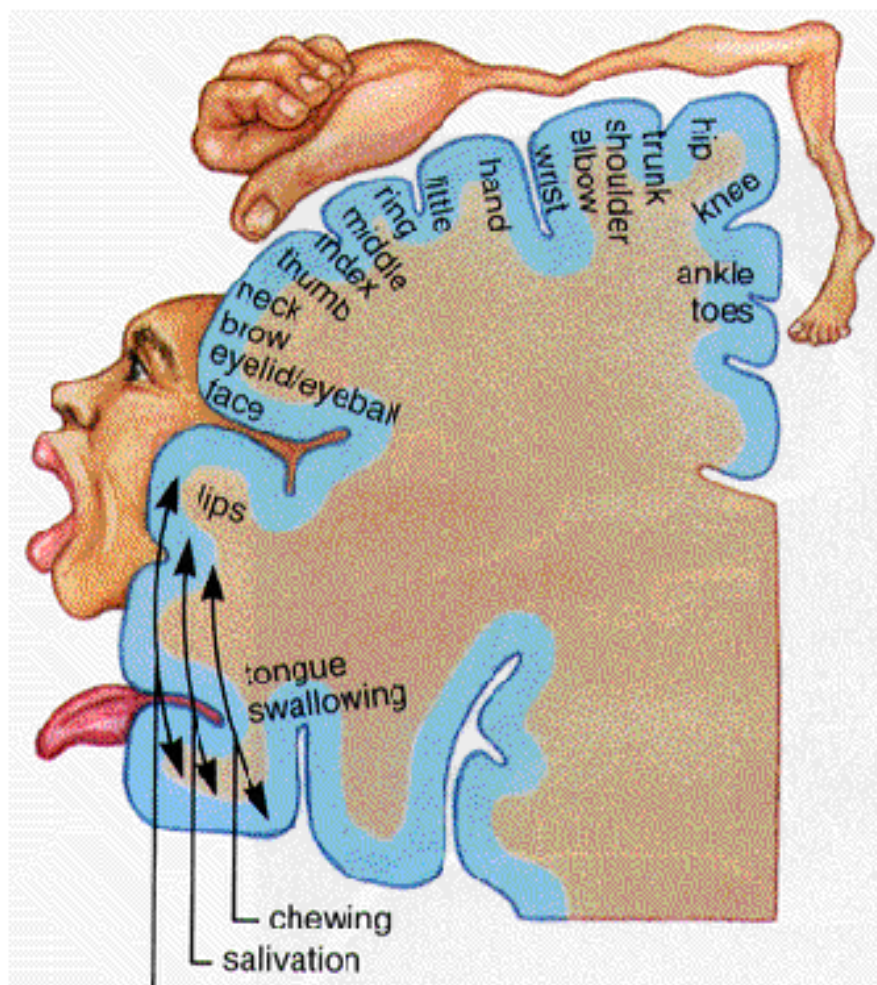
centrum kožnej citlivosti a bolesti

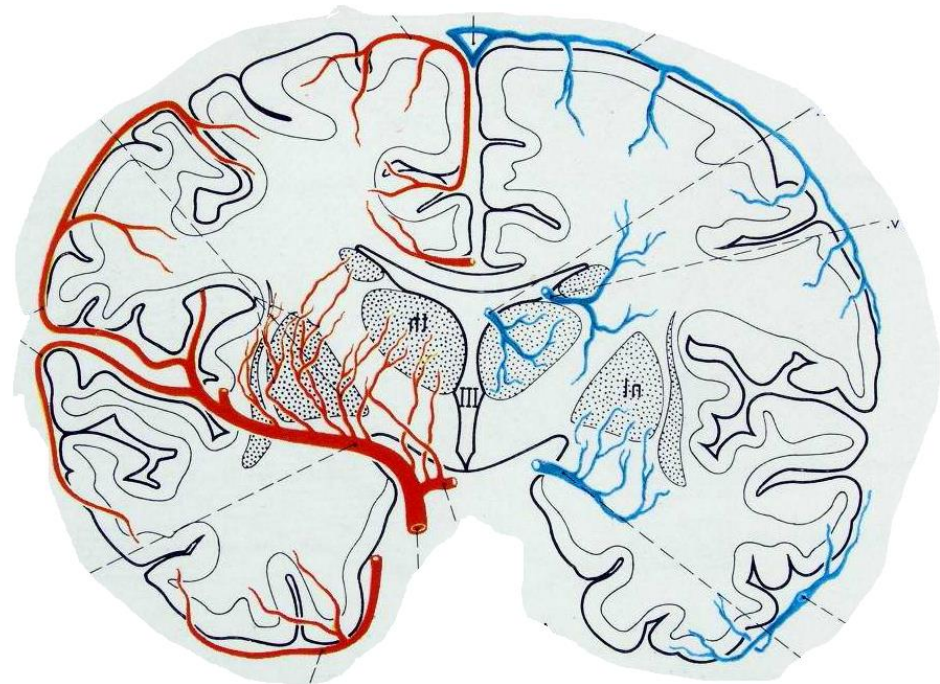
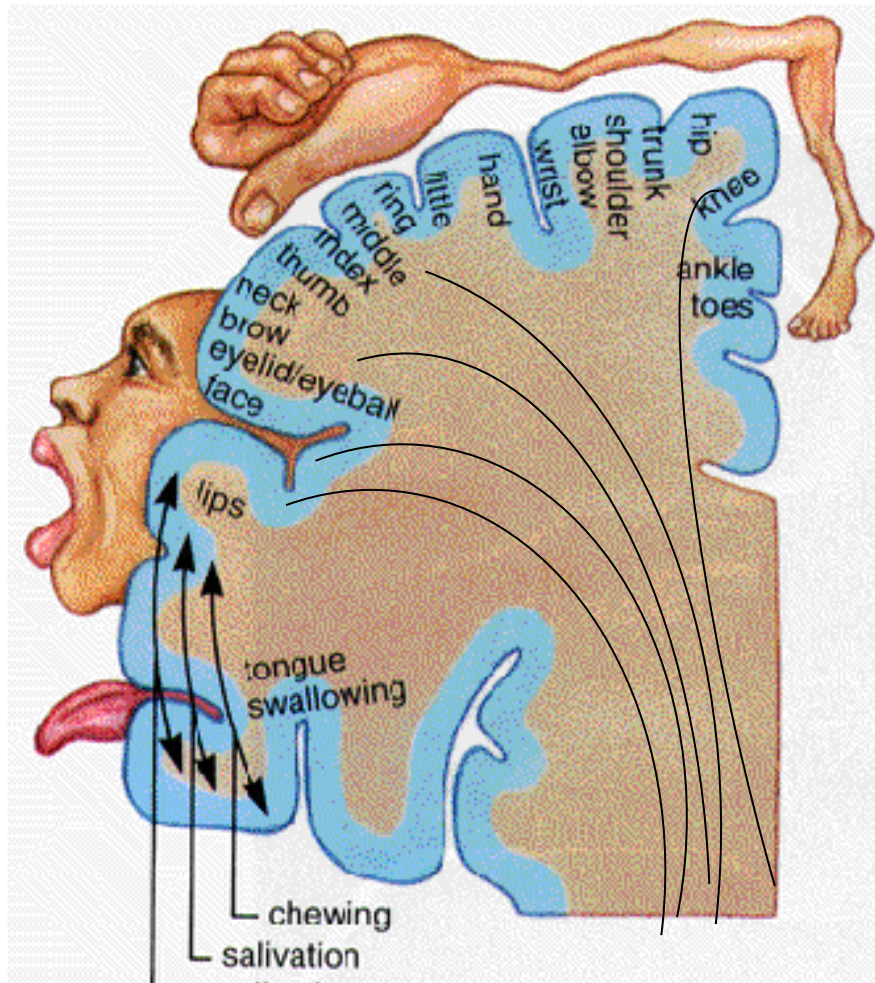
čuchové centrum

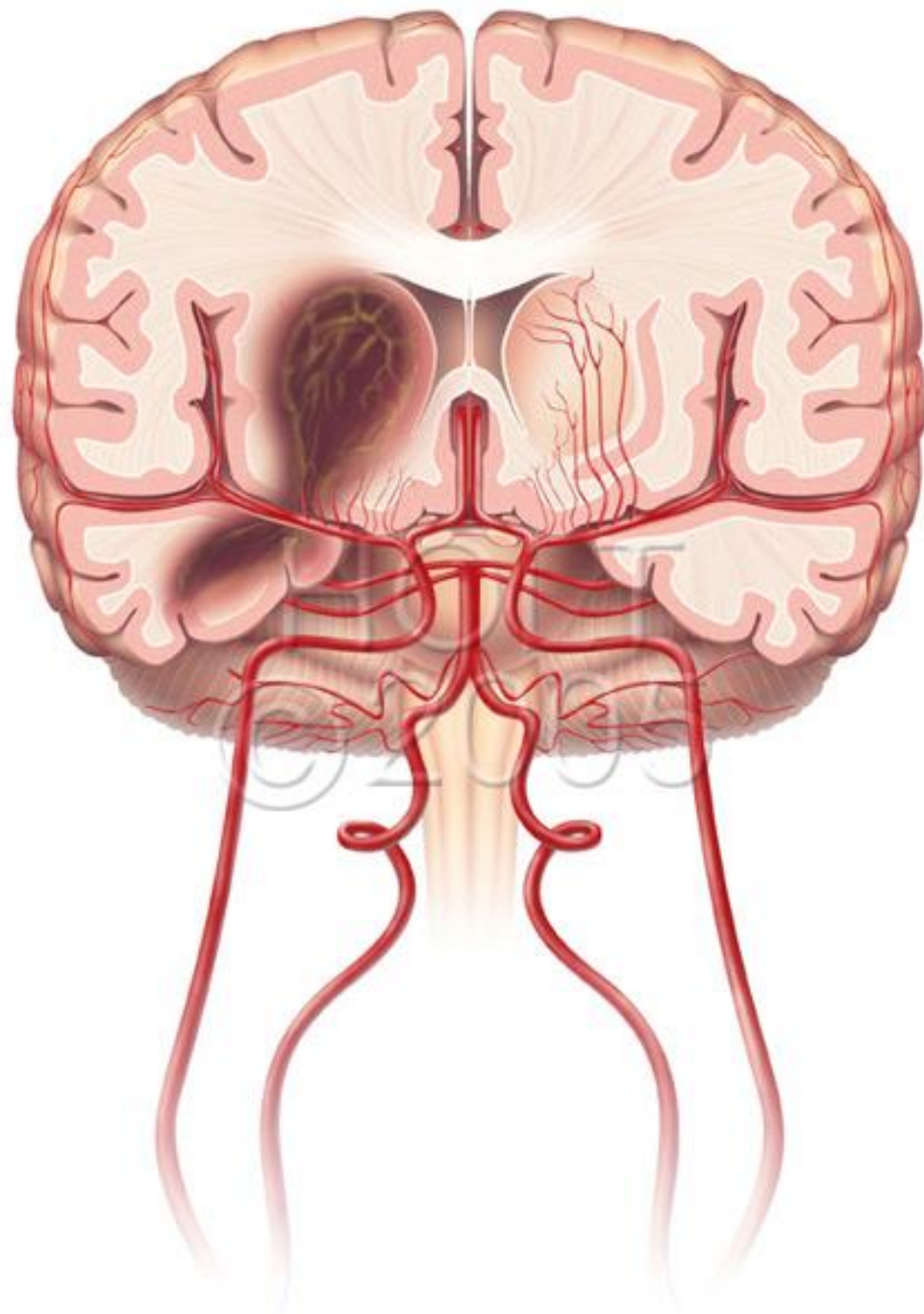
suchové centrum

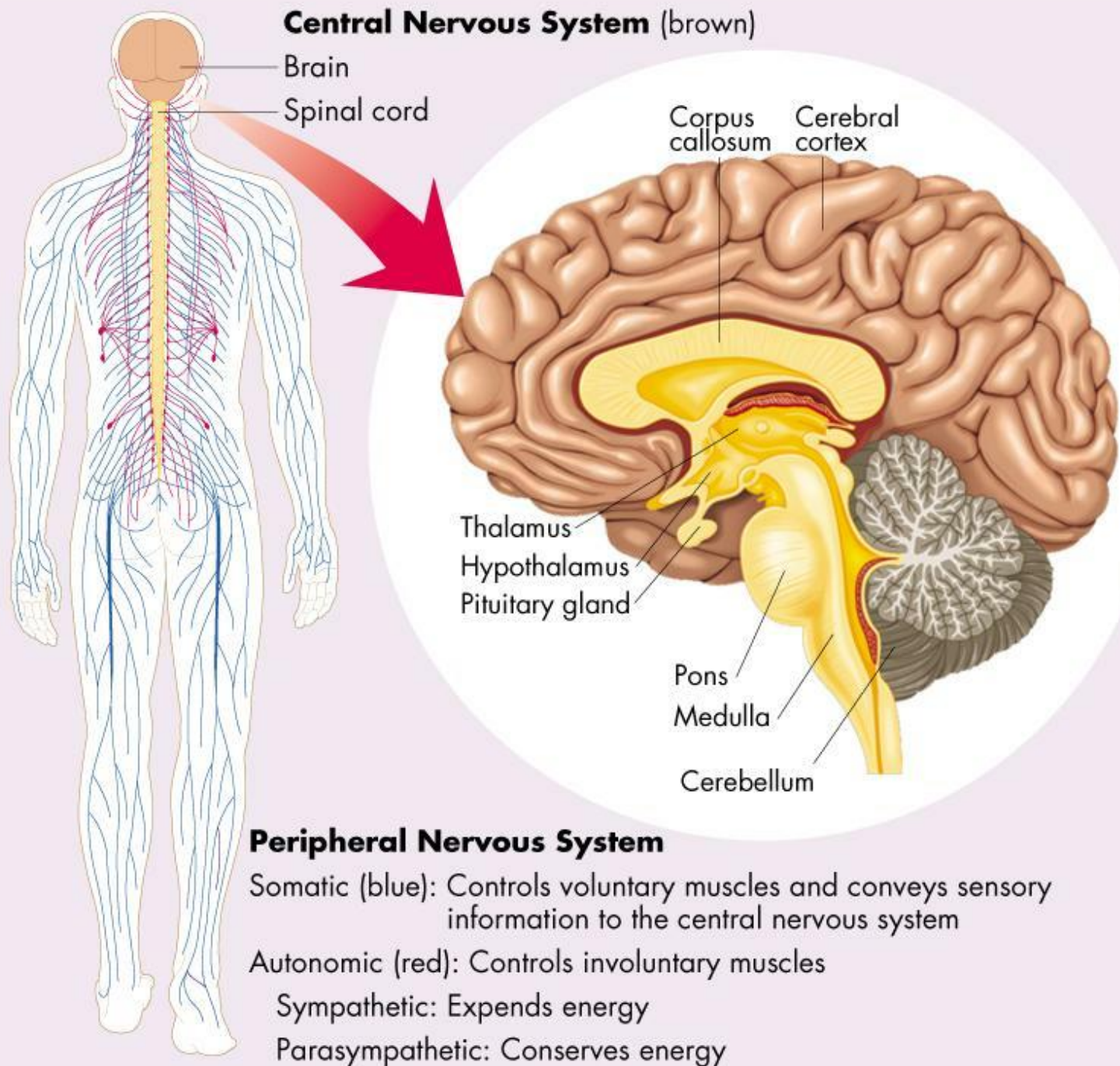
zrakové centrum

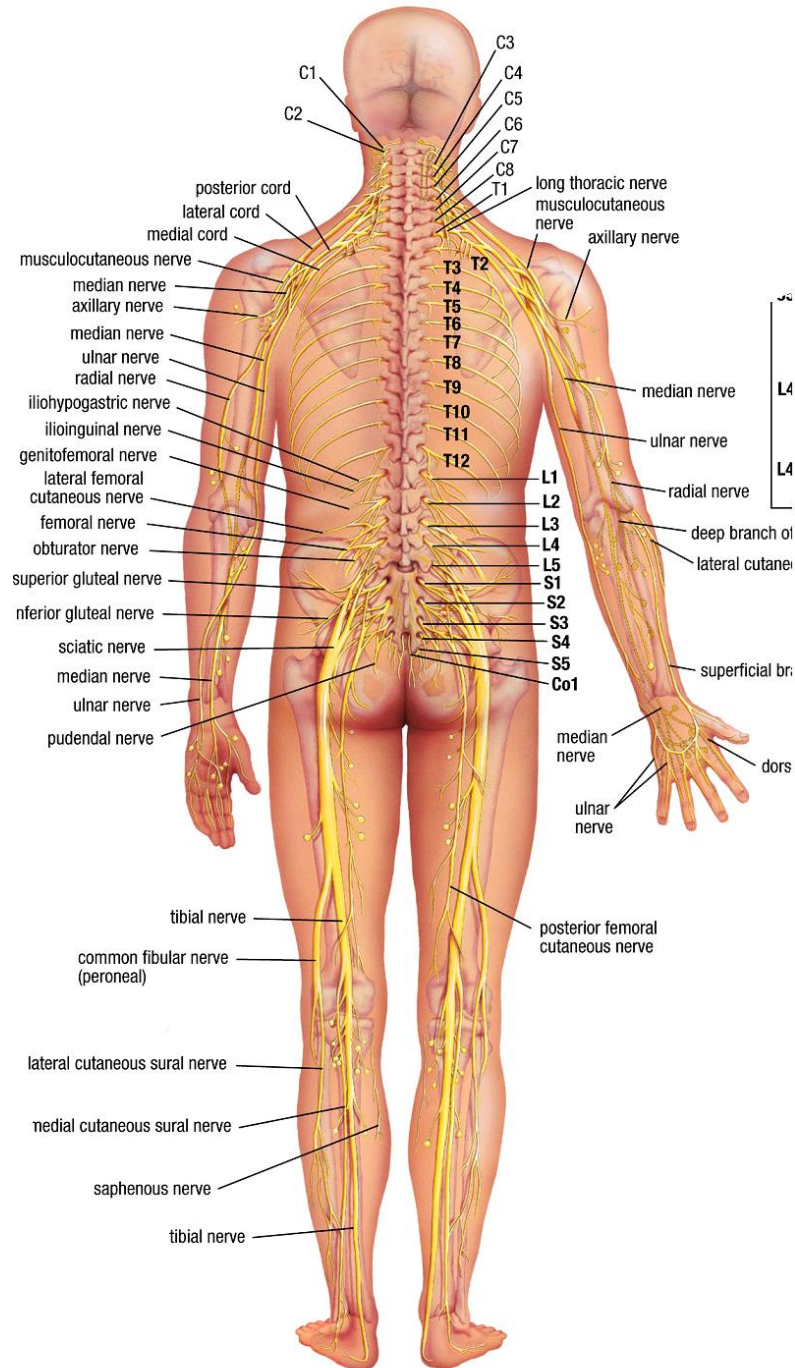


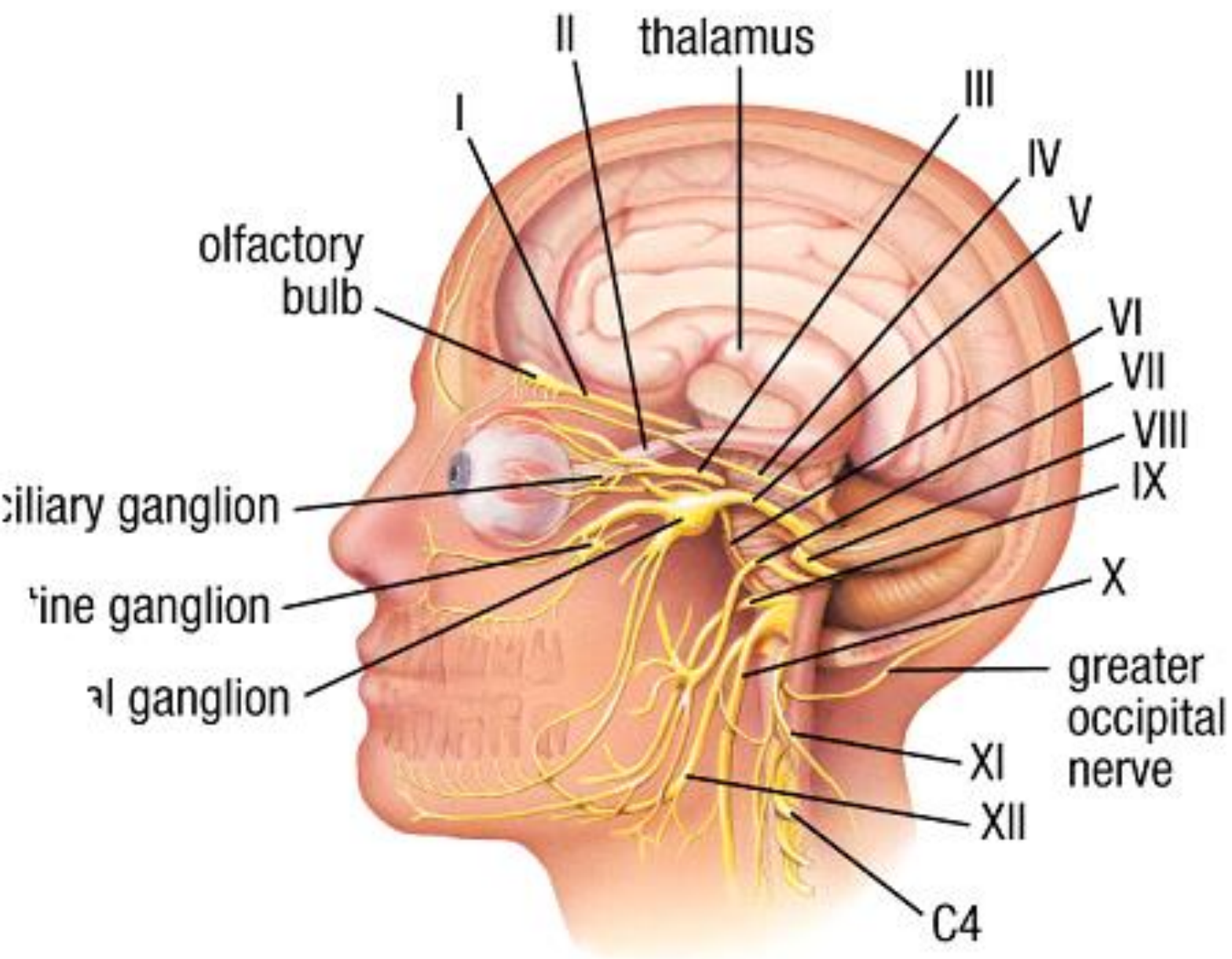




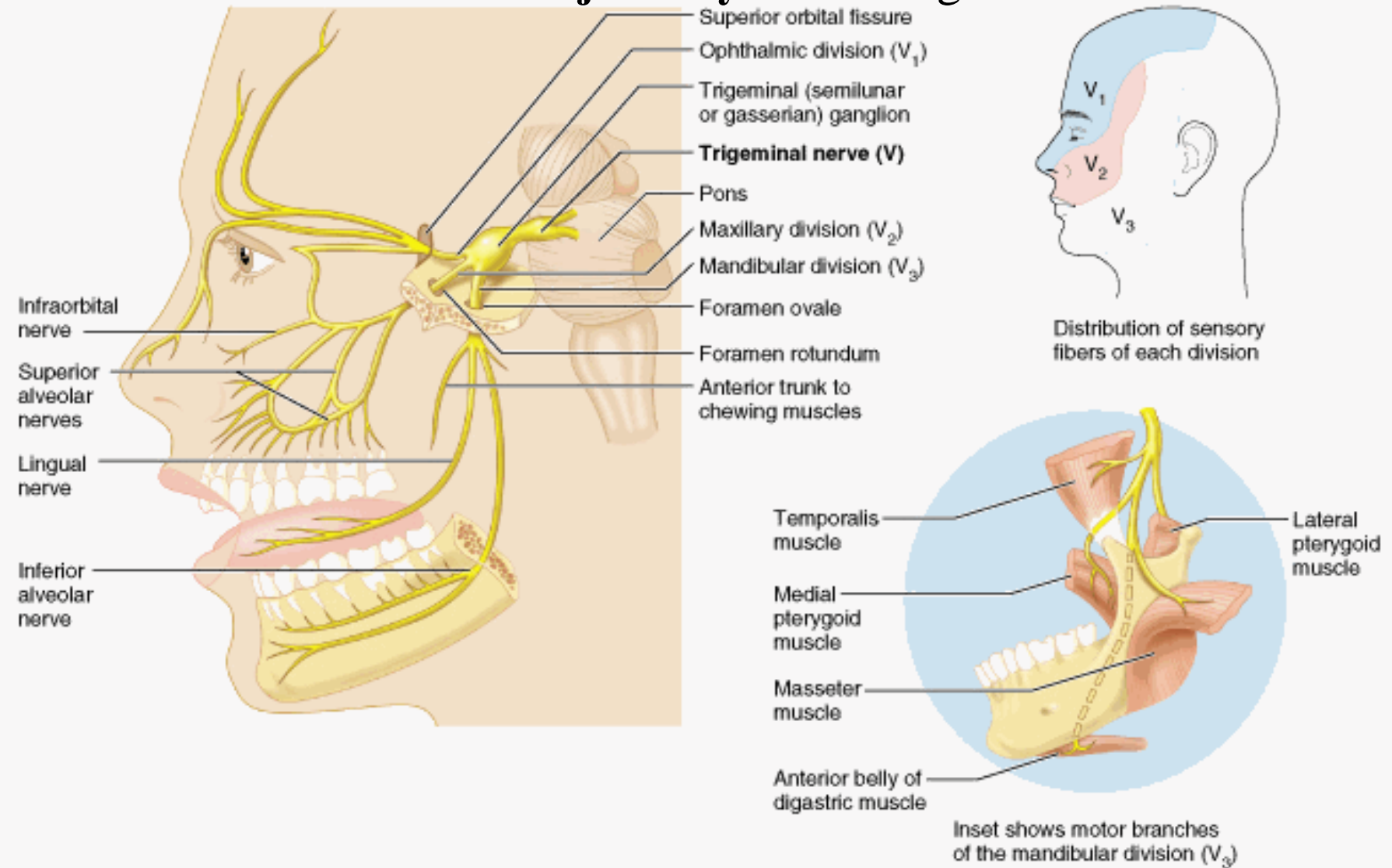


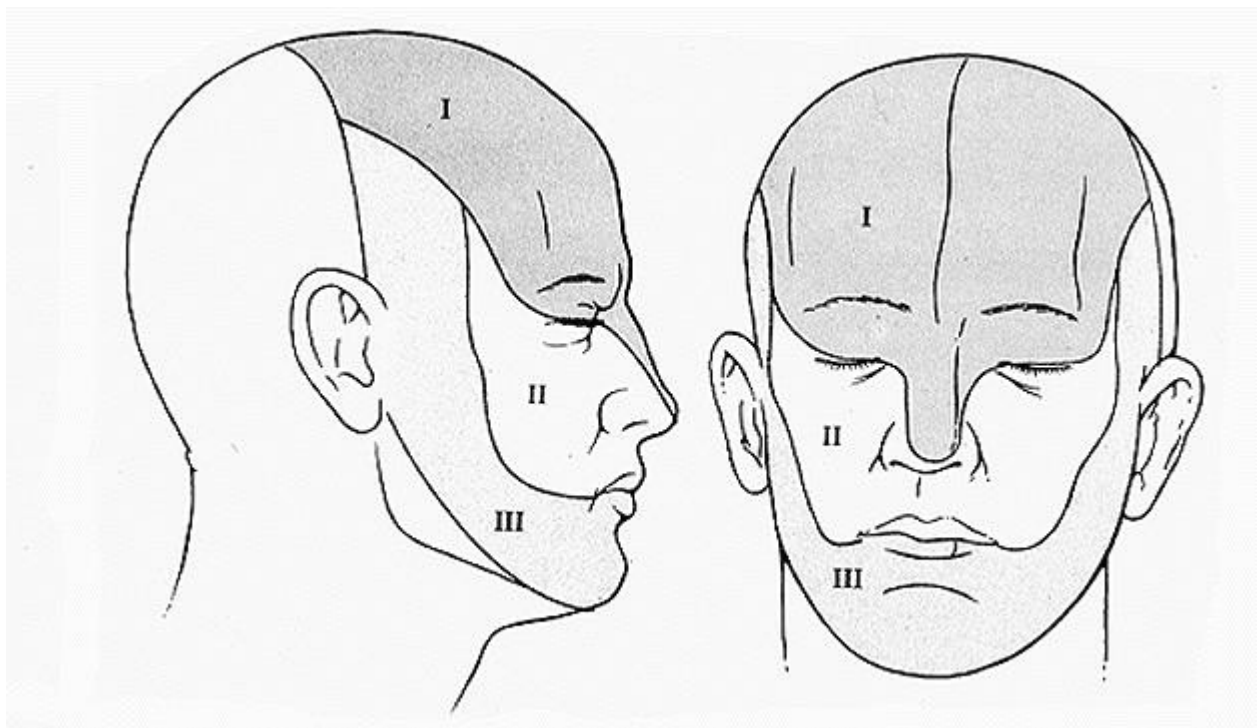






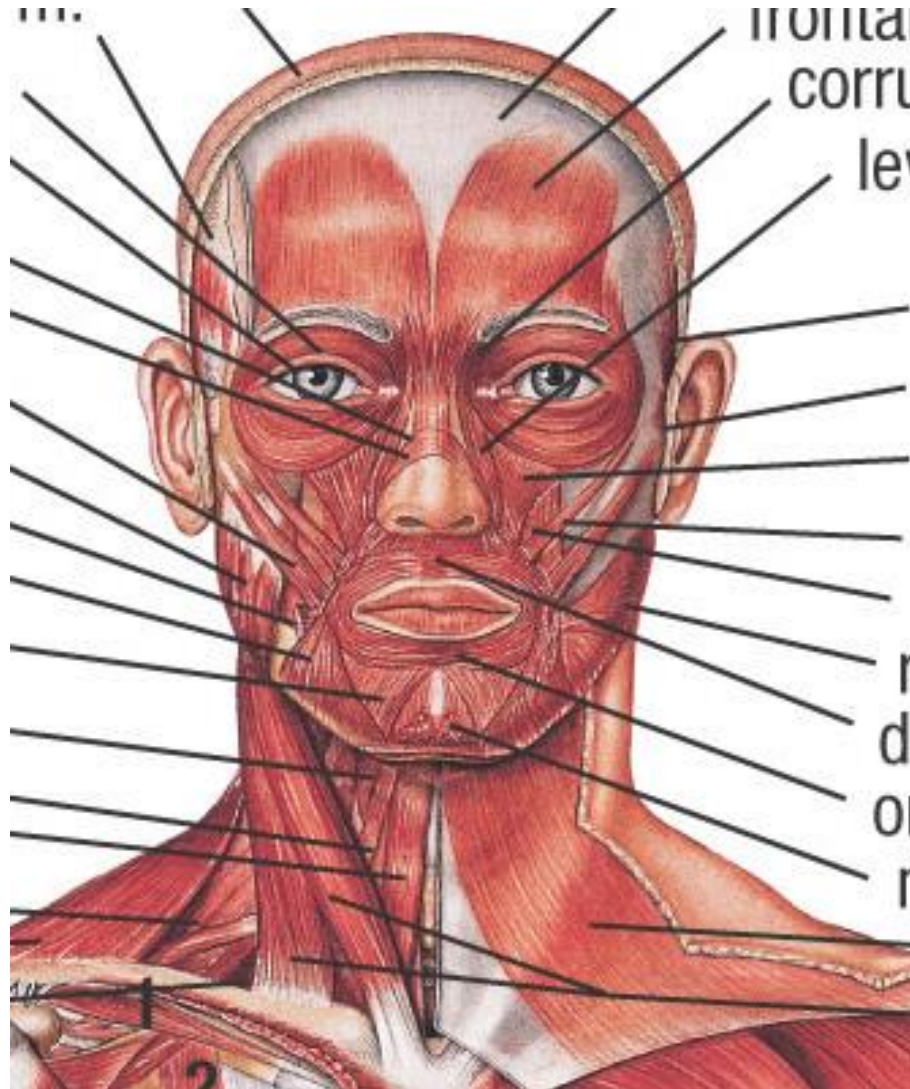
Trojklanný nerv - trigeminus





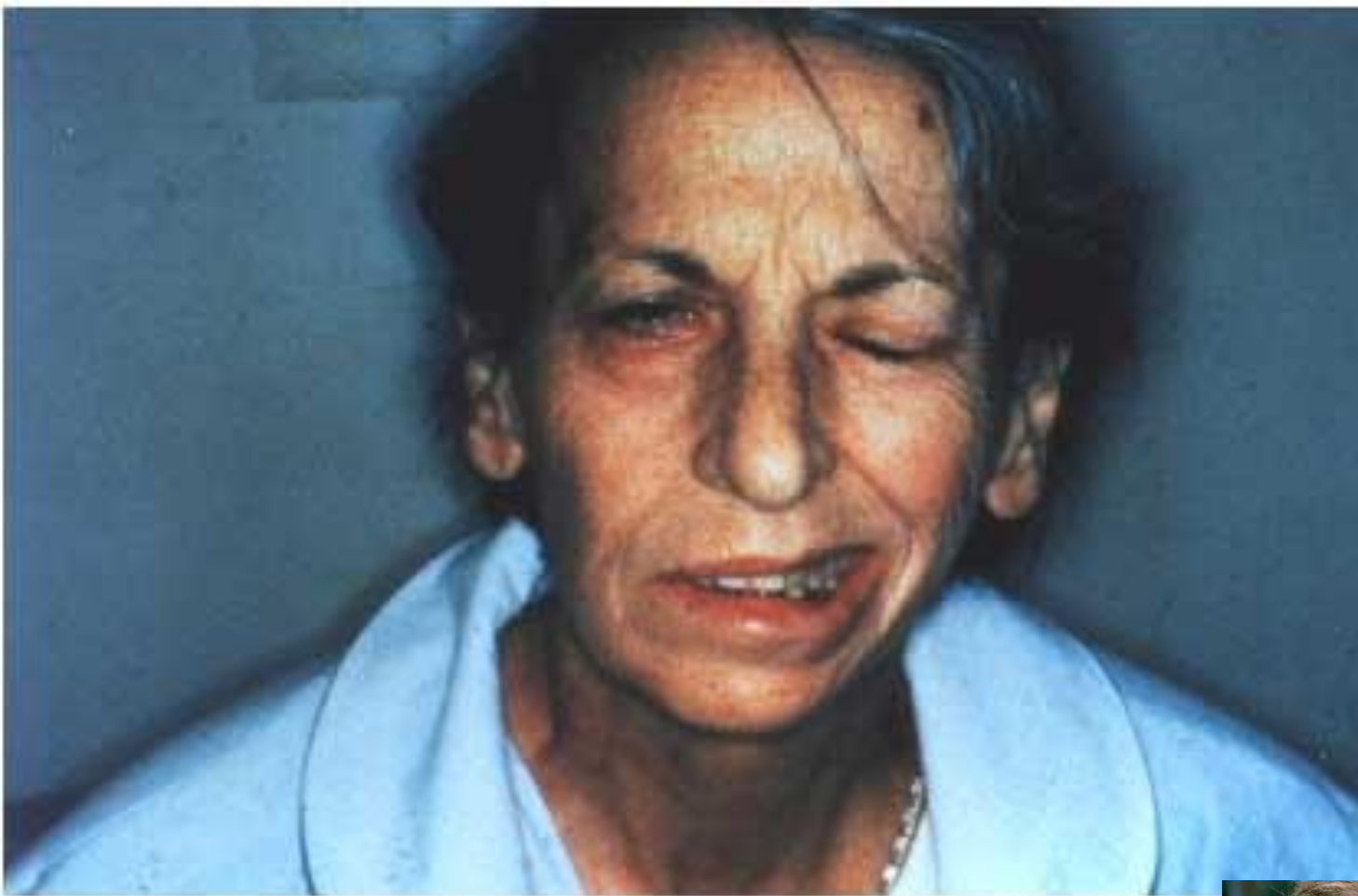Trojklanný nerv - trigeminus

Tvárový nerv - facialis



Tvárový nerv - facialis

Schwartzberg



Podjazykový nerv - hypoglossus

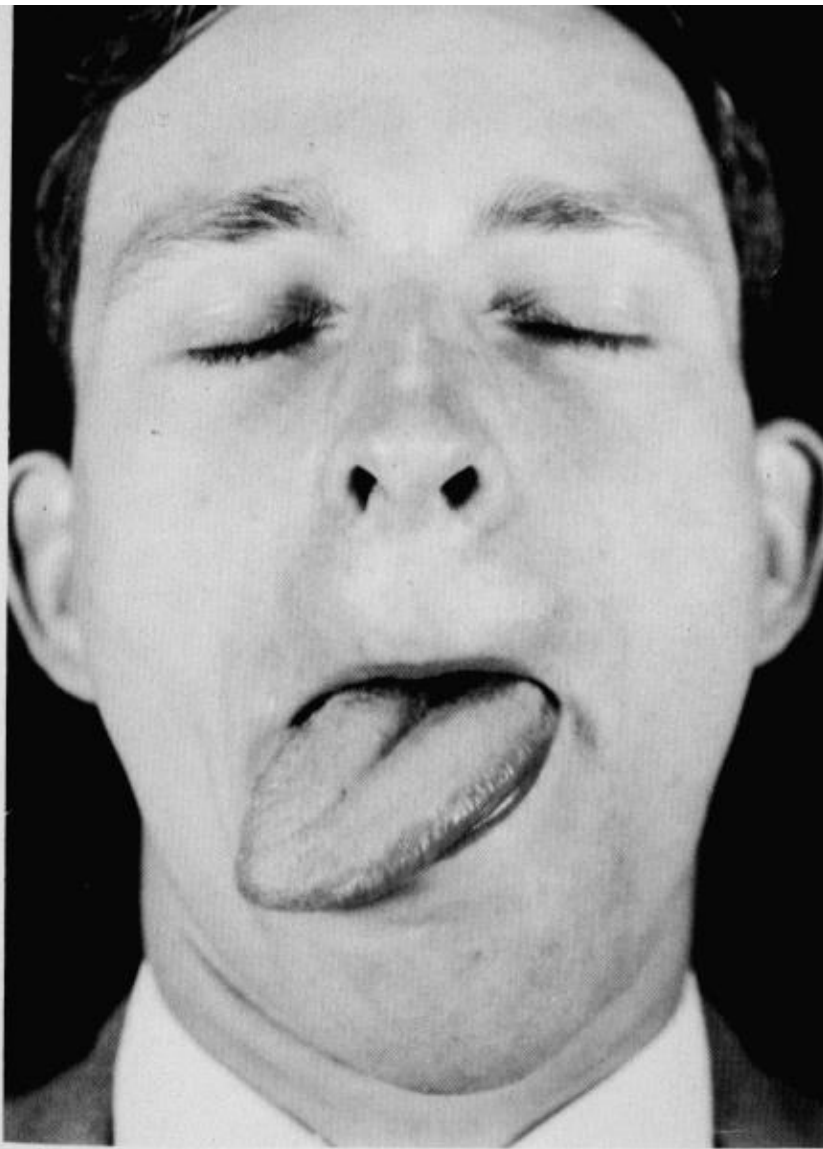
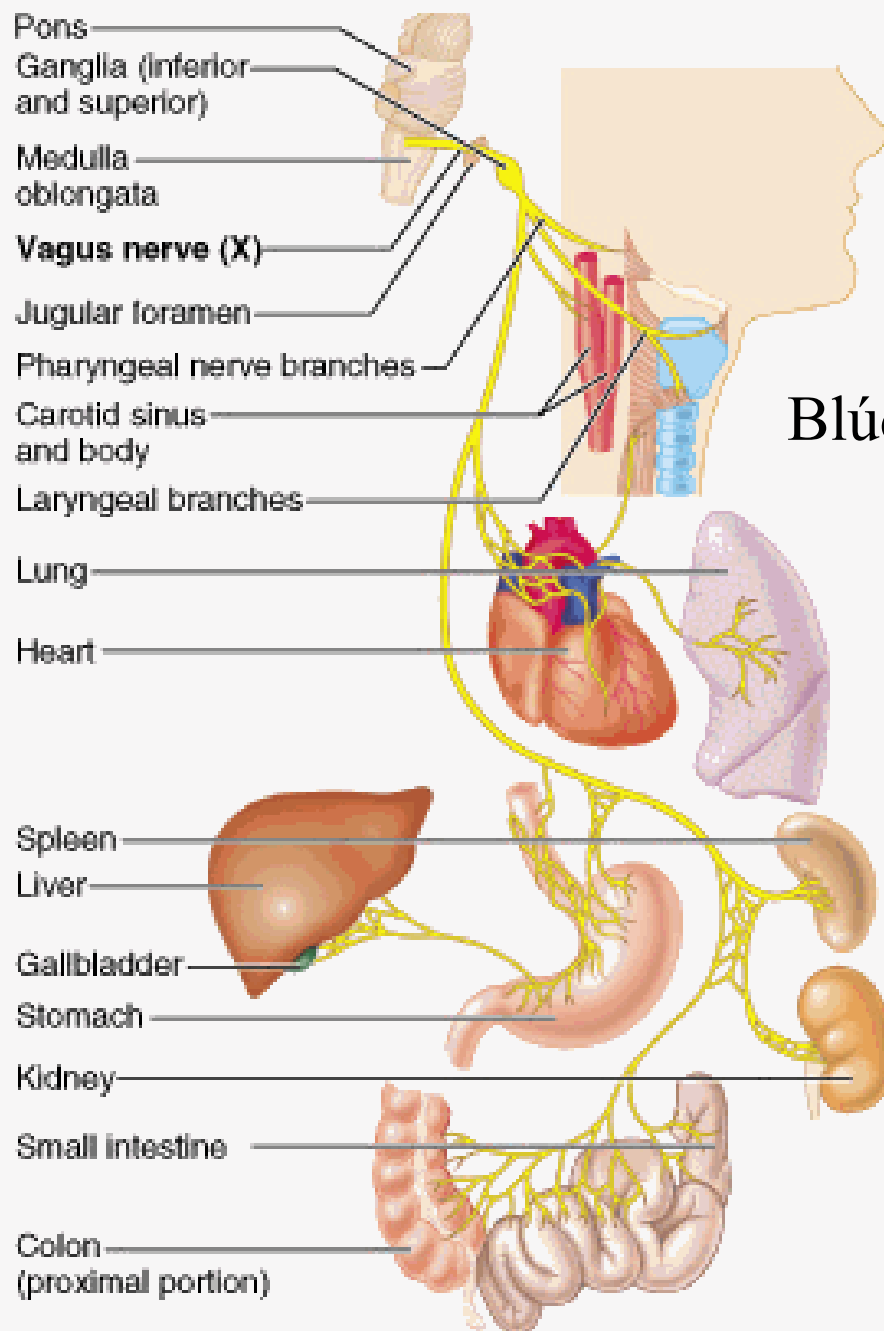
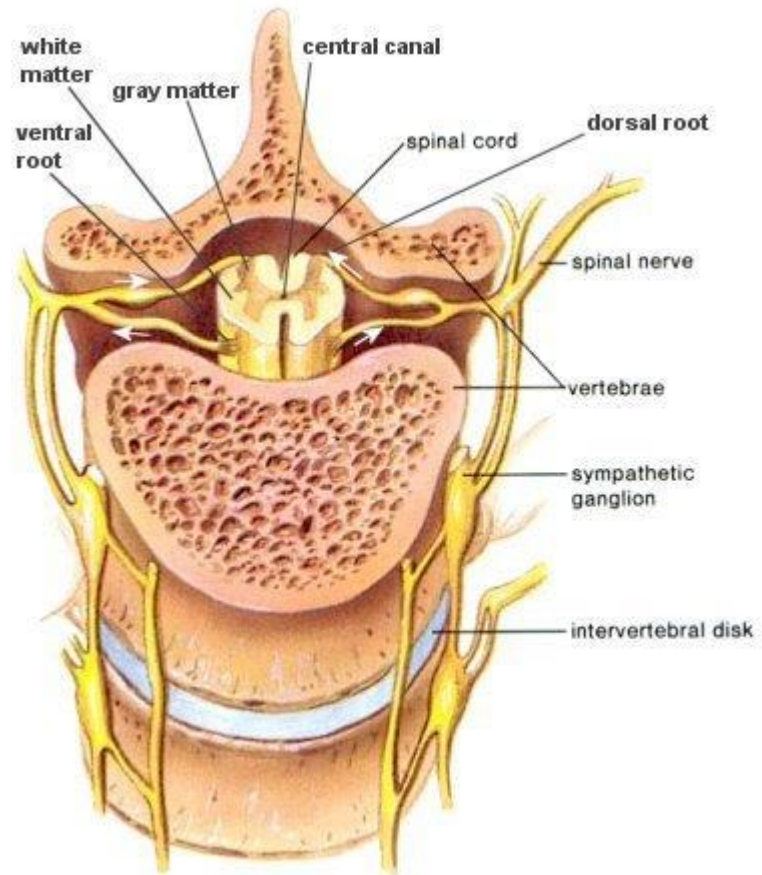
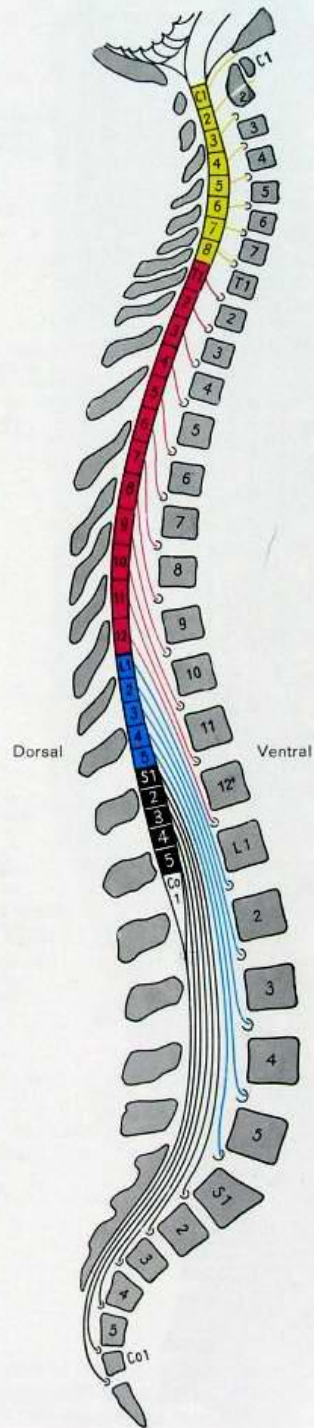


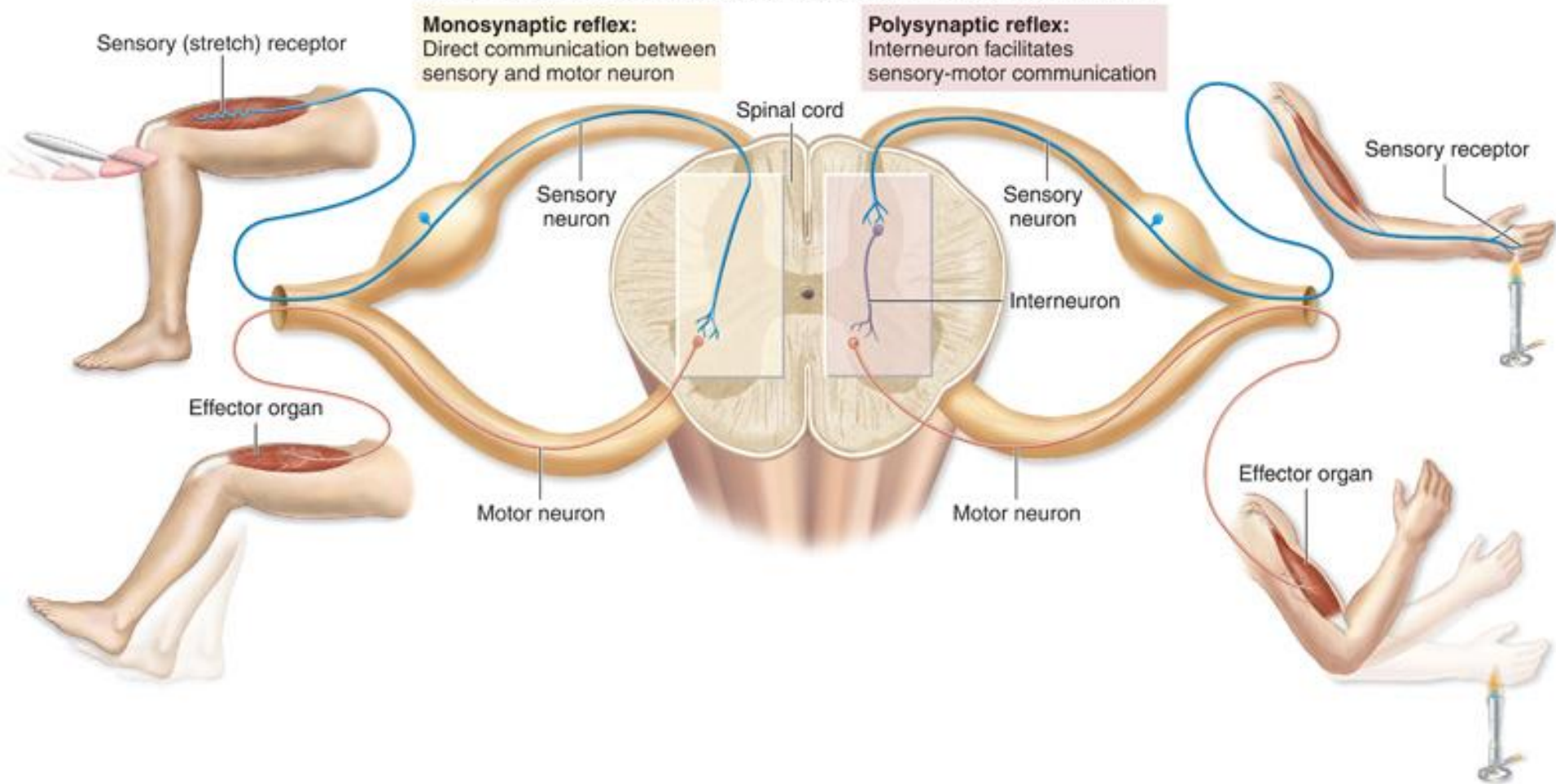
FIG. 17-3. Nuclear paralysis of muscles supplied by the hypoglossal nerve: atrophy and fasciculations of the tongue in a patient with amyotrophic lateral sclerosis.

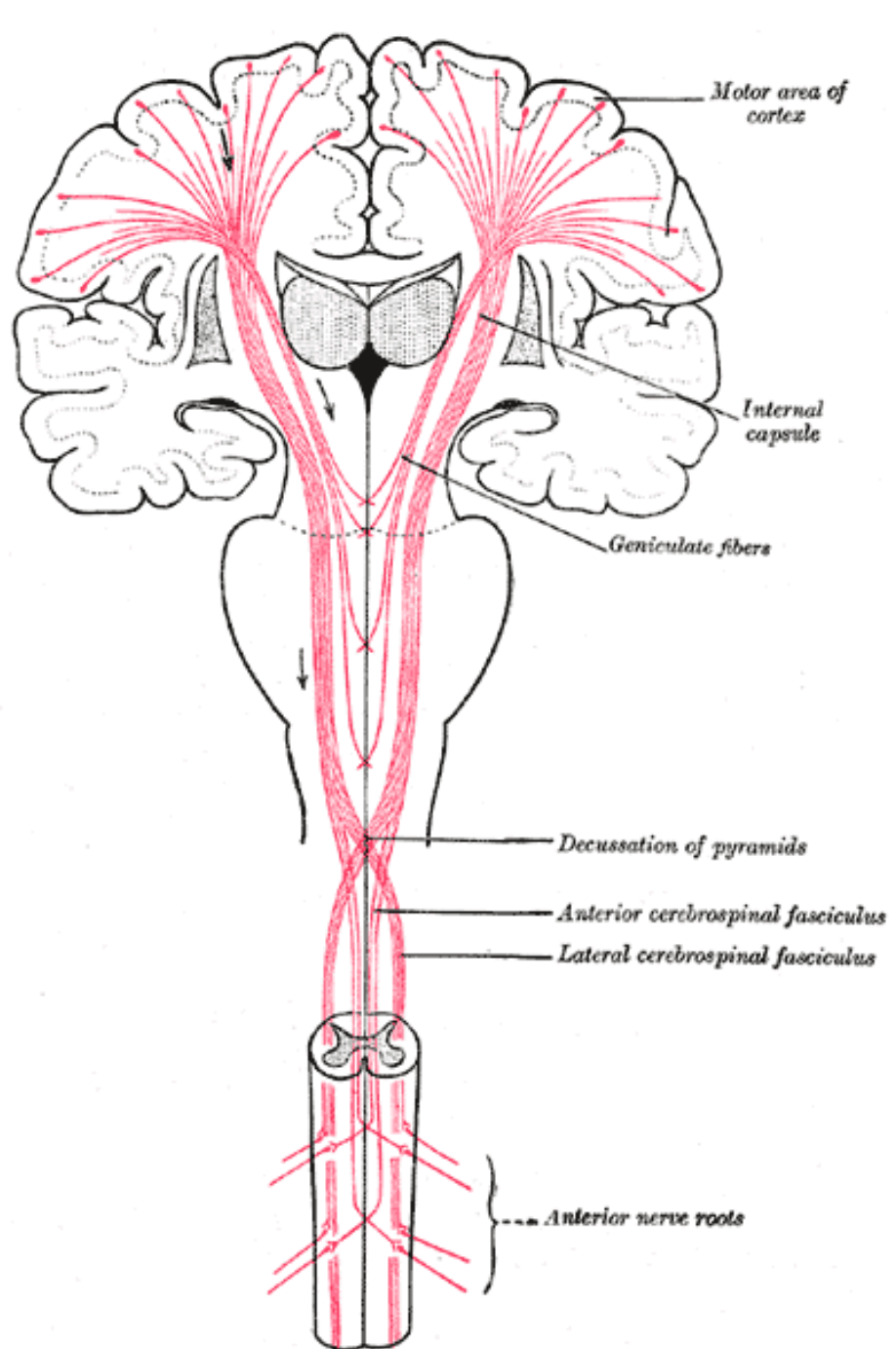
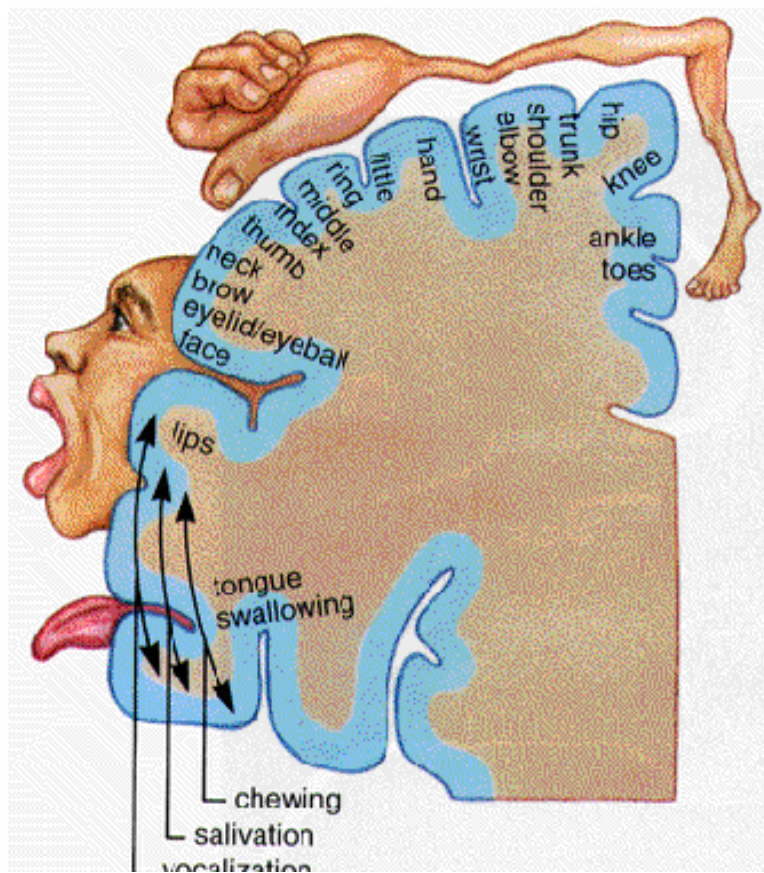


Blúdivý nerv – nervus vagus



Copyright © The McGraw-Hill Companies, Inc. Permission required for reproduction or display.





Rostral
←

Caudal
→

Frontal lobe

Parietal lobe

Central sulcus

Gyrus

Sulcus

Lateral fissure

Temporal lobe

Pons

Medulla oblongata

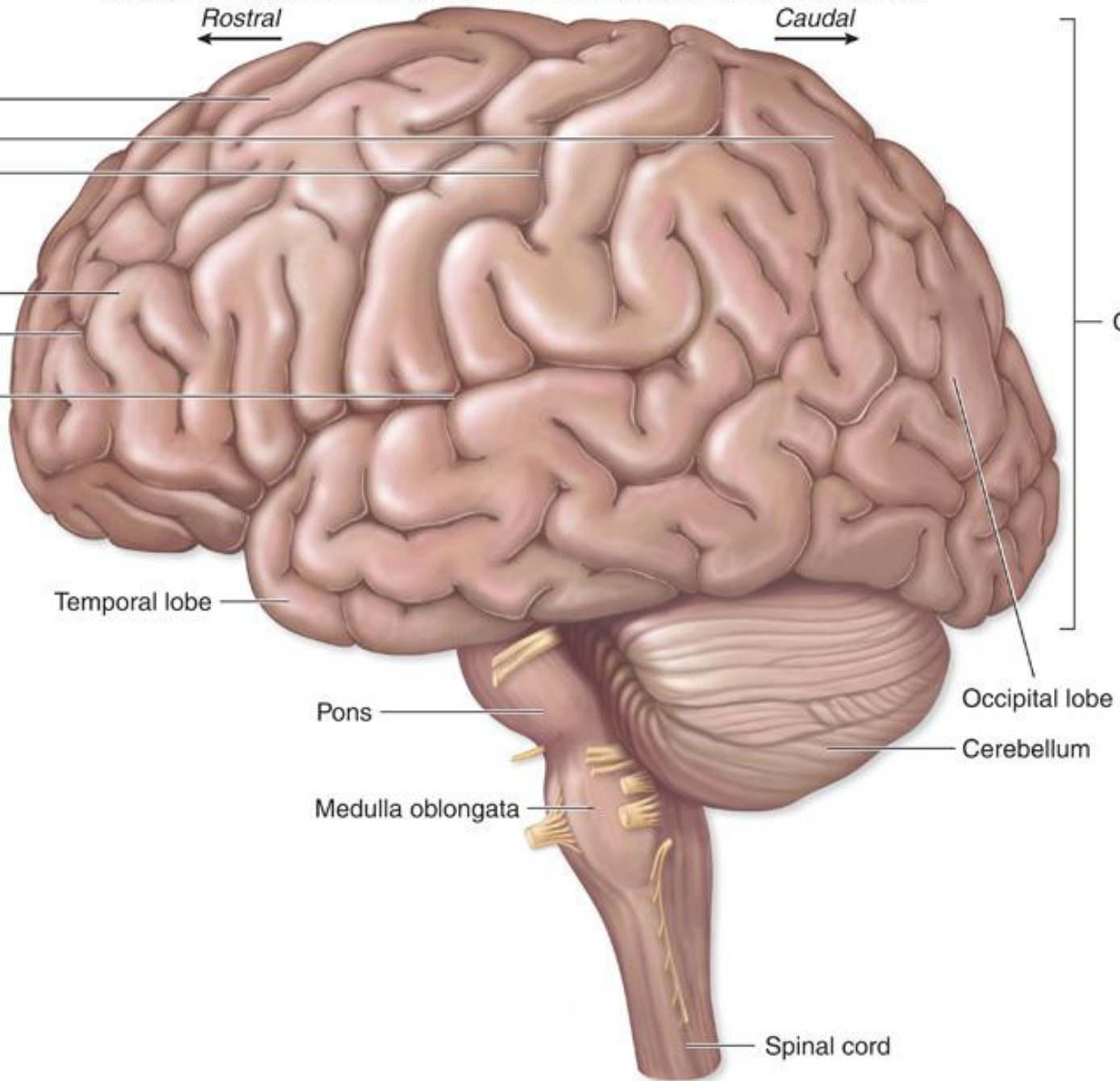
Spinal cord

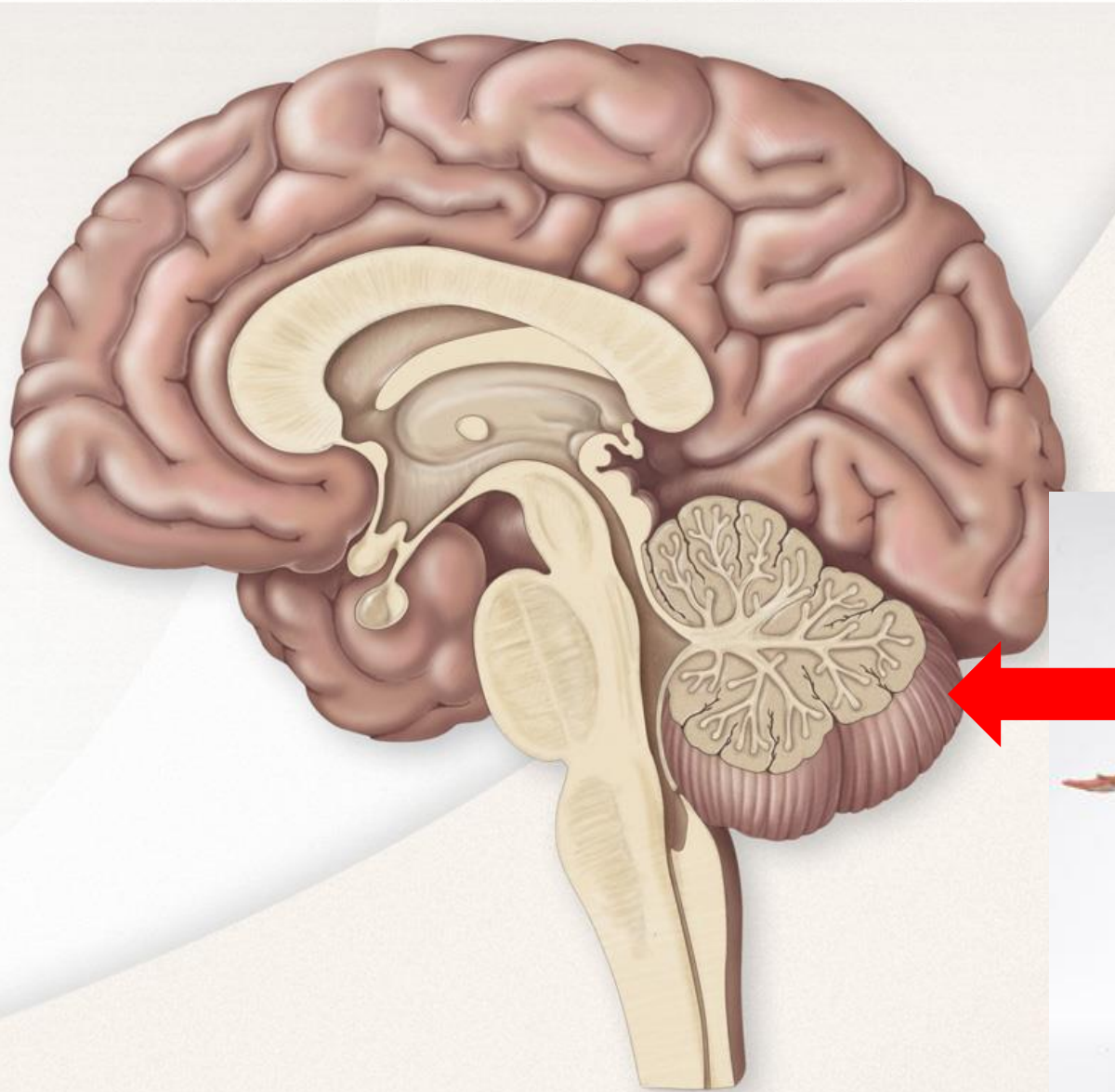
Cerebrum


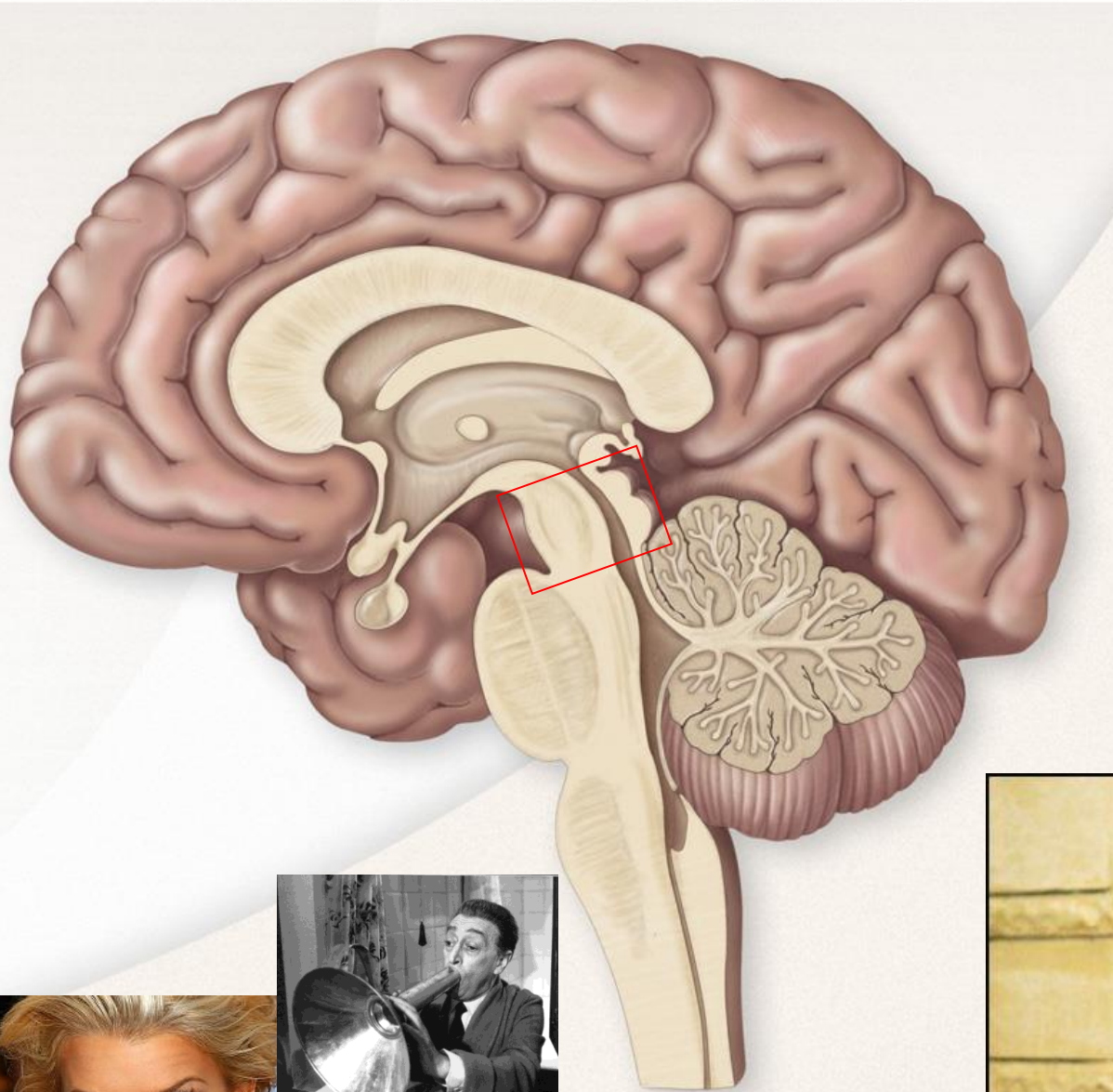
Occipital lobe

Cerebellum

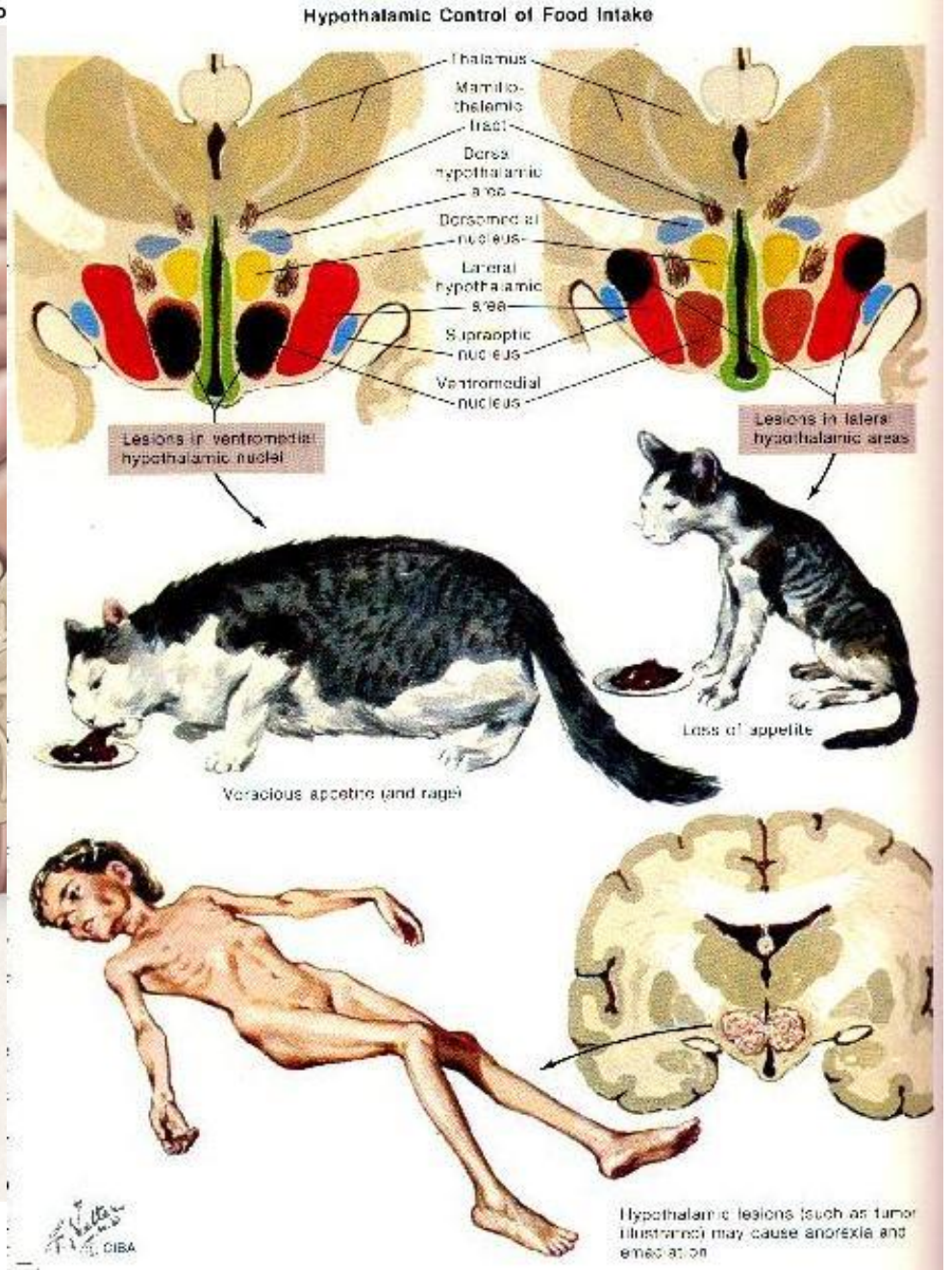
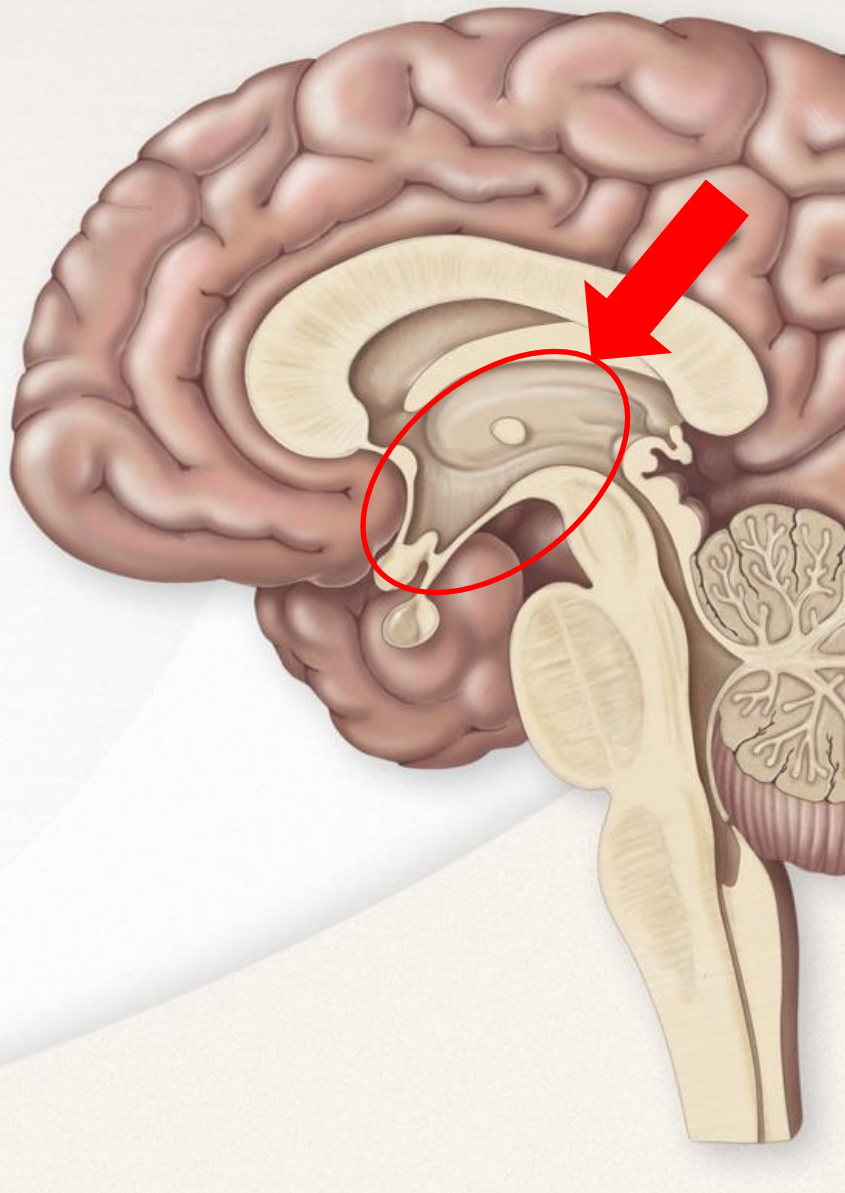
(a) Left lateral view

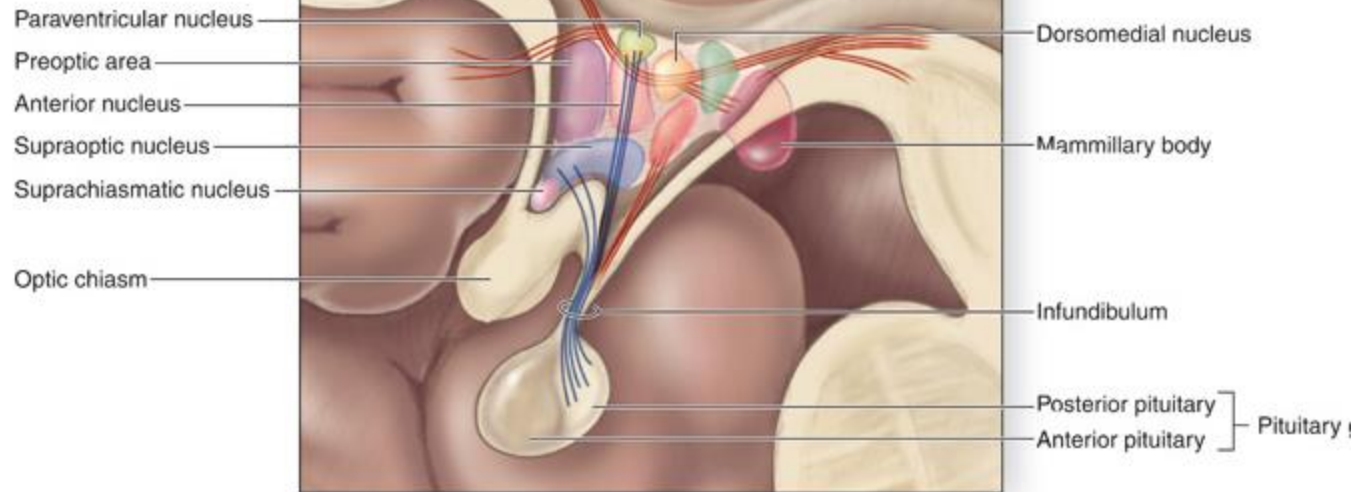
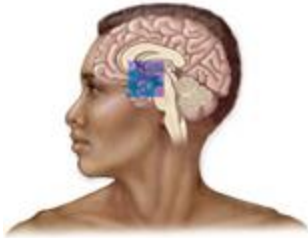



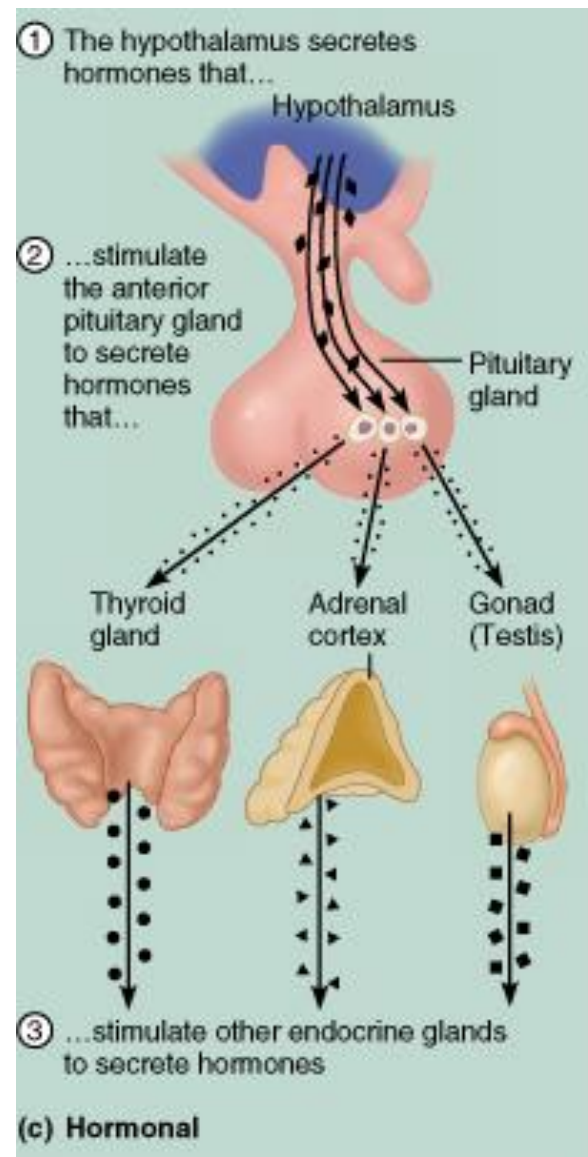
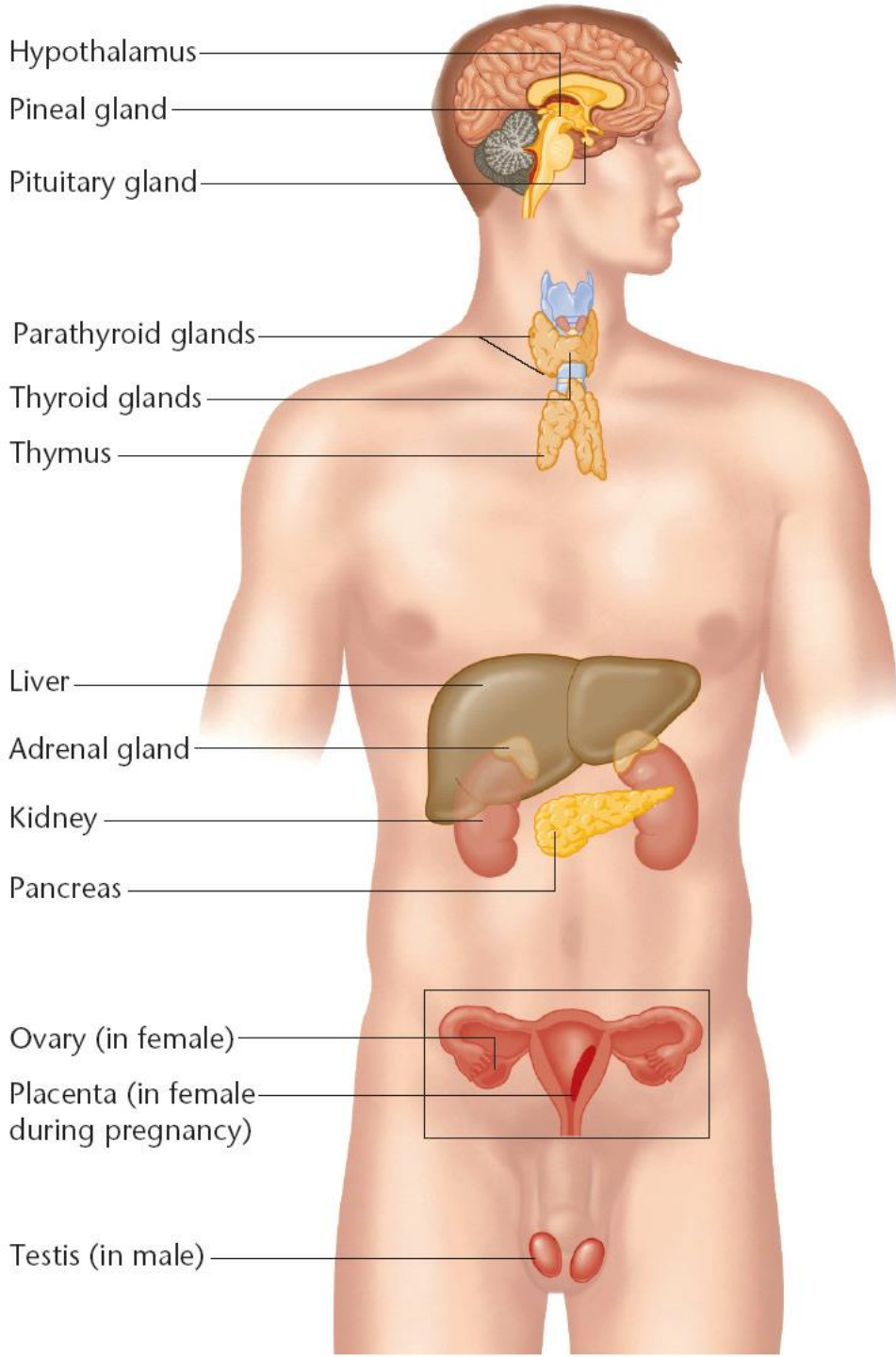


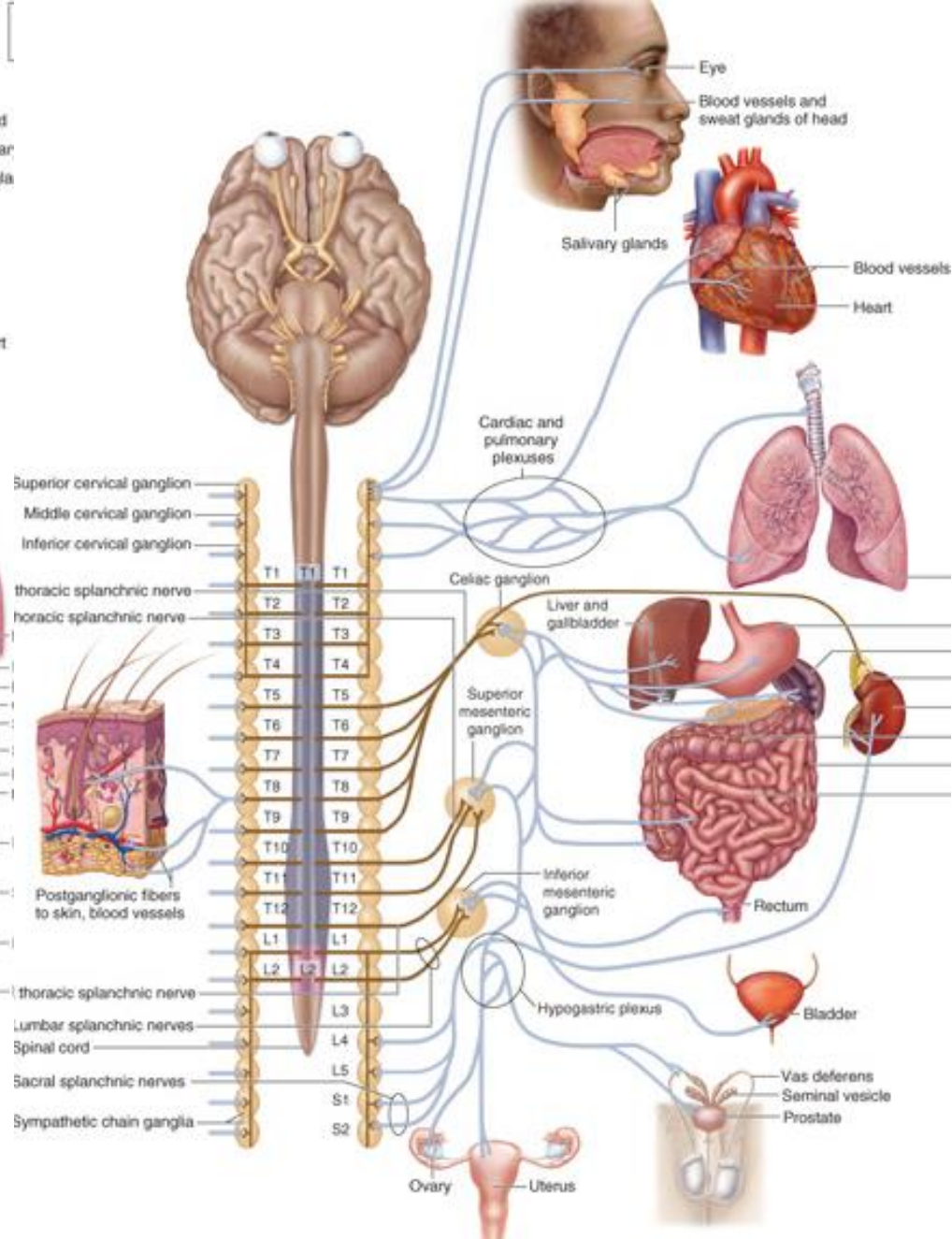
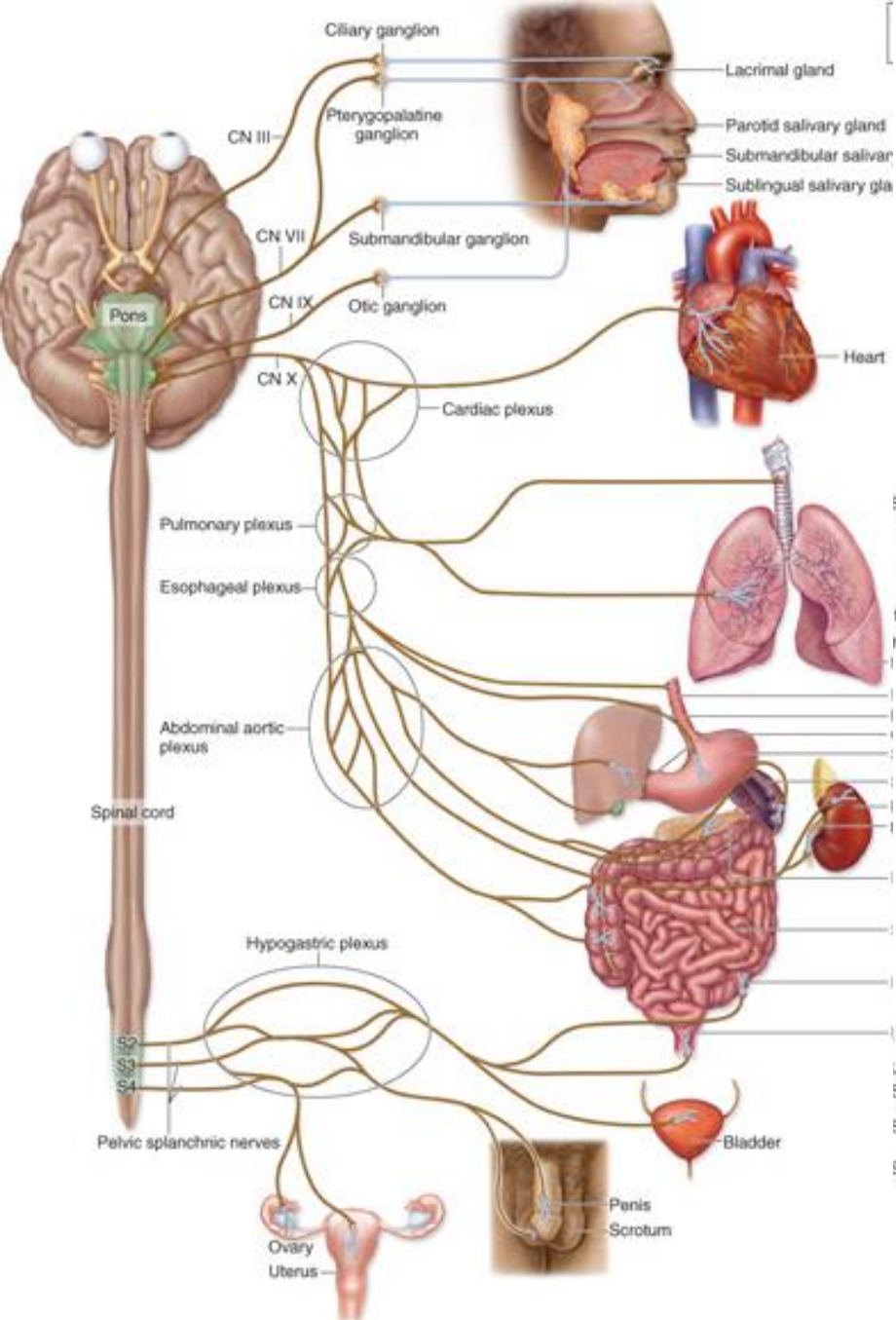
بقراءت: صدر راج عراقی وزیراعظم نوری المالکی کے ساتھ نواکریس کا غرض کے دوران عراقی صحافی کی جانب سے پھینکے جانے والے جوتے سے بچنے کی کوشش کر رہے ہیں

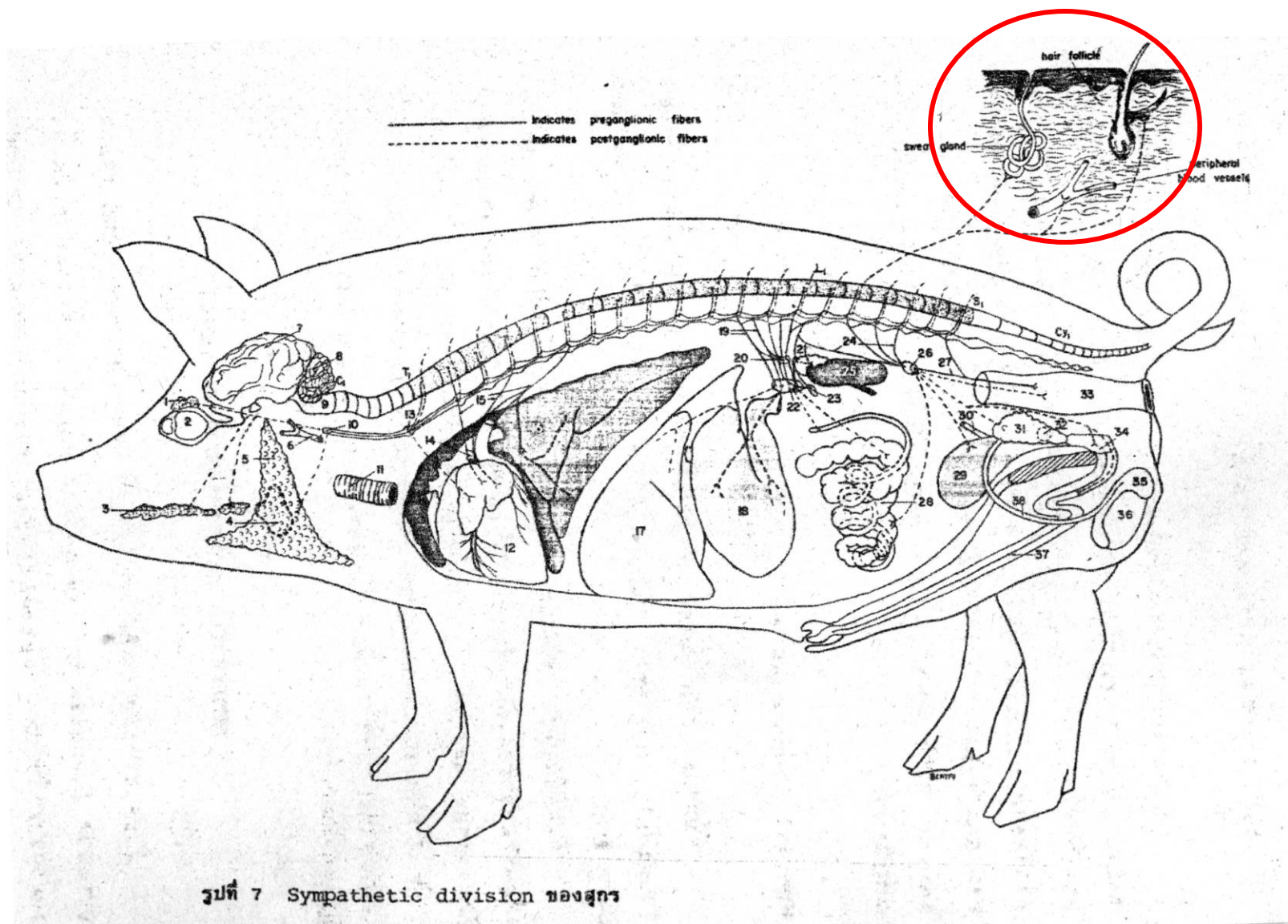




Sagittal section of hypothalamus







sympatikus

