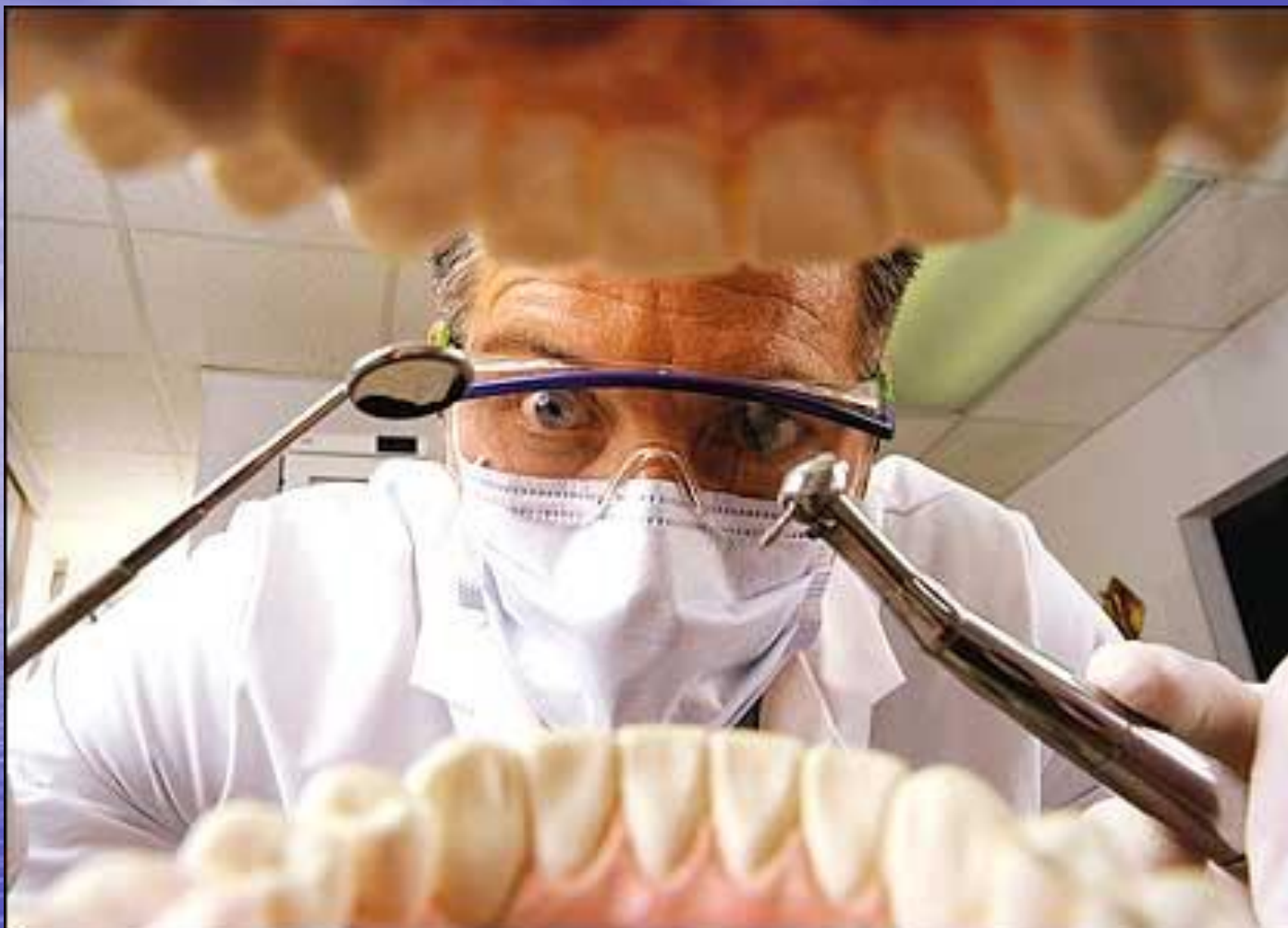



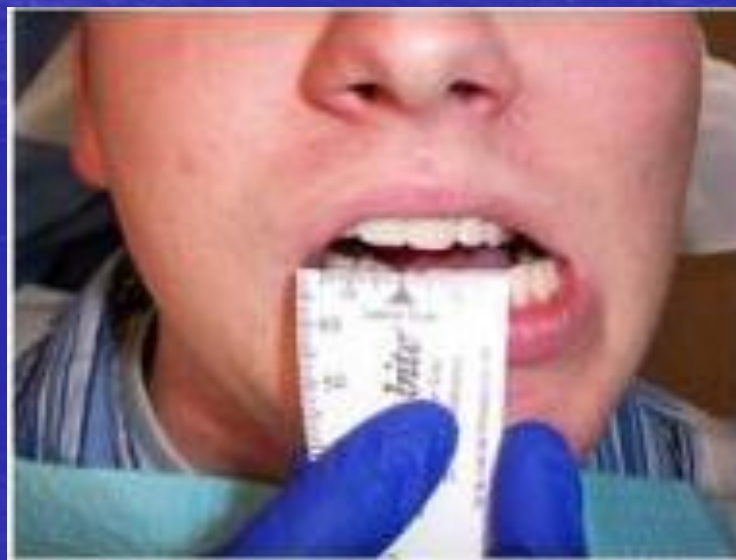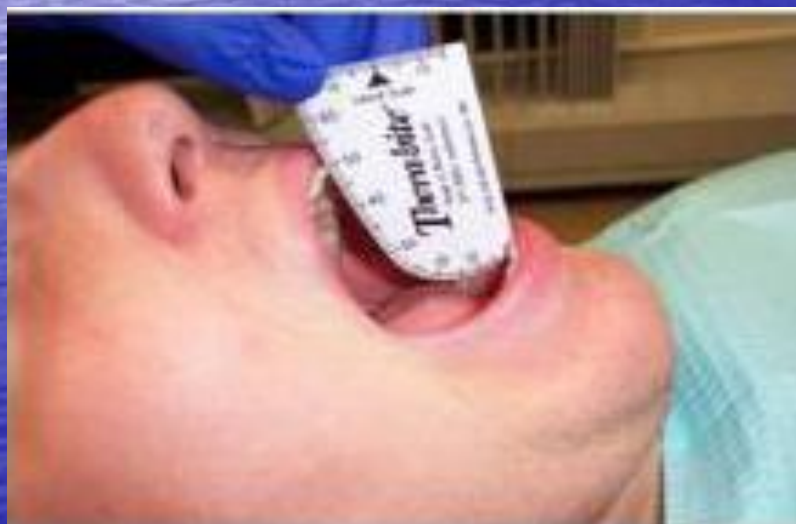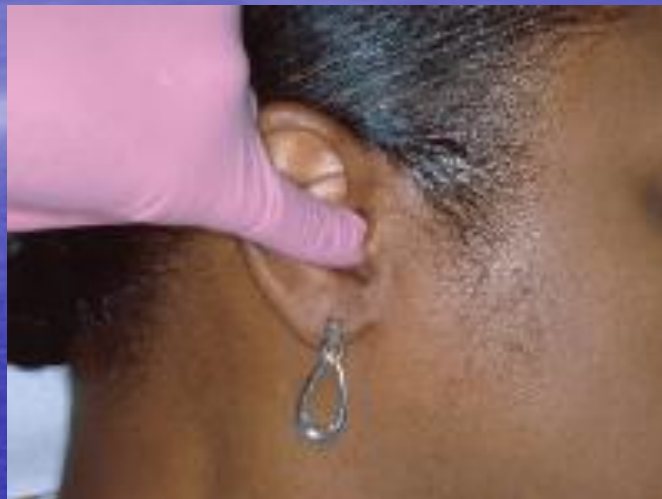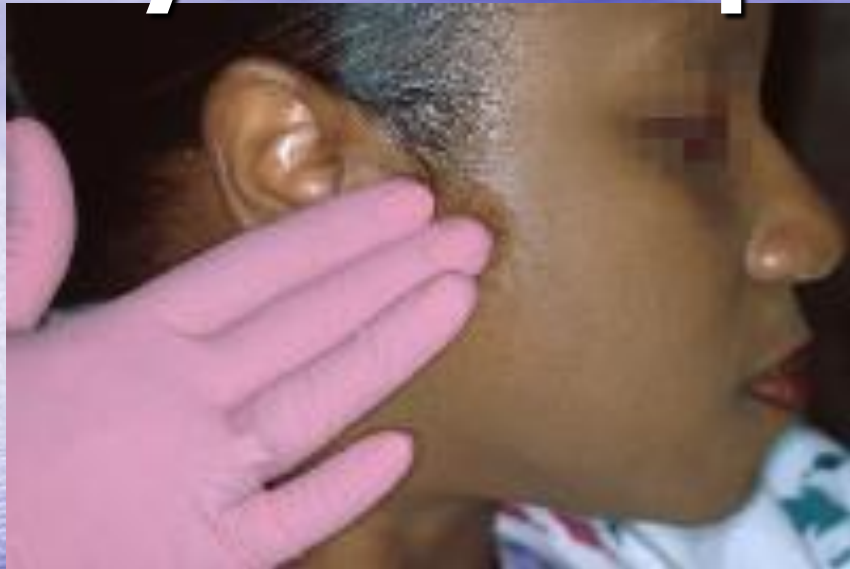MUDr. Mária Janíčková, PhD.

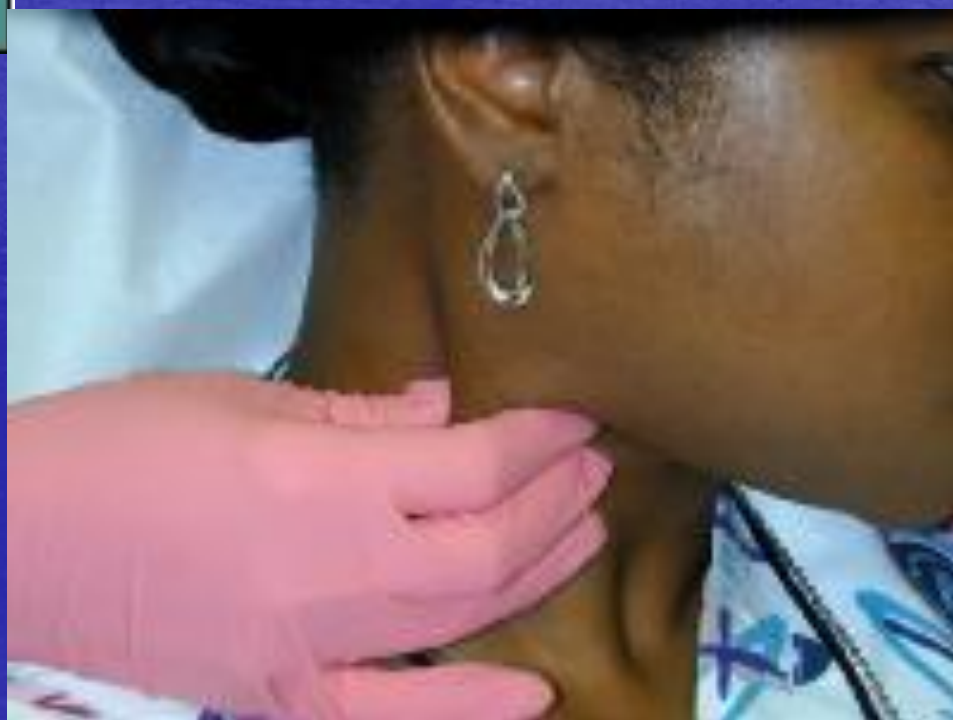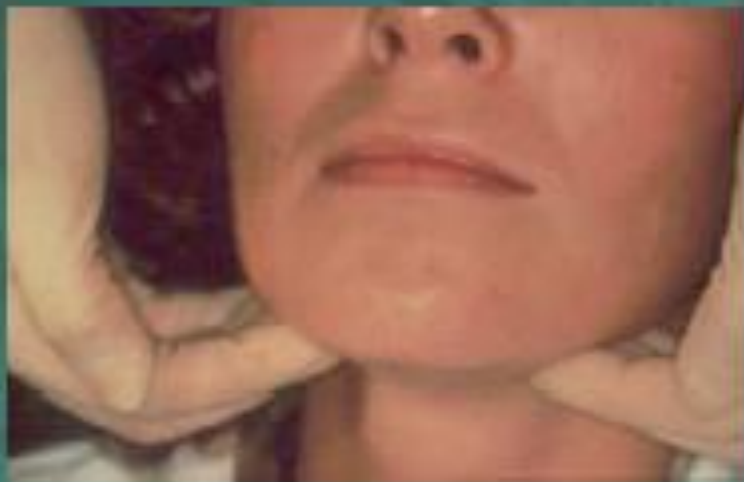Klinika stomatológie a maxilofaciálnej chirurgie
Jesseniovej Lekárskej Fakulty a Martinskej Univerzitetnej
Nemocnice v Martine

Rozdelenie odboru

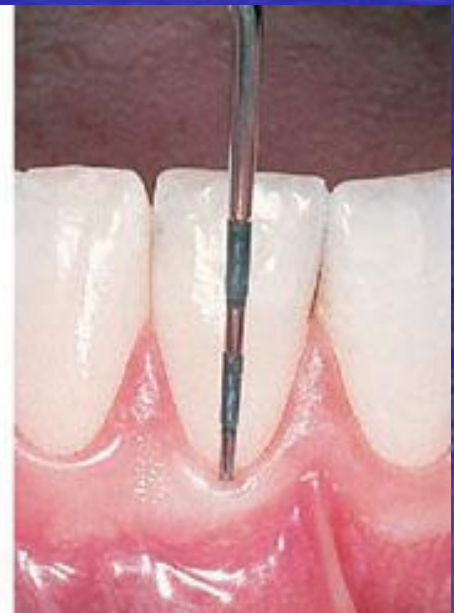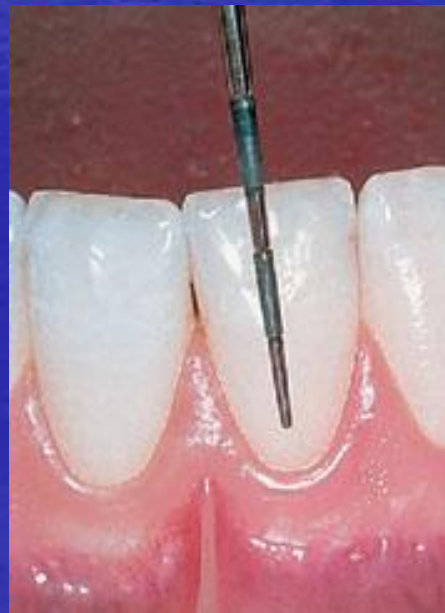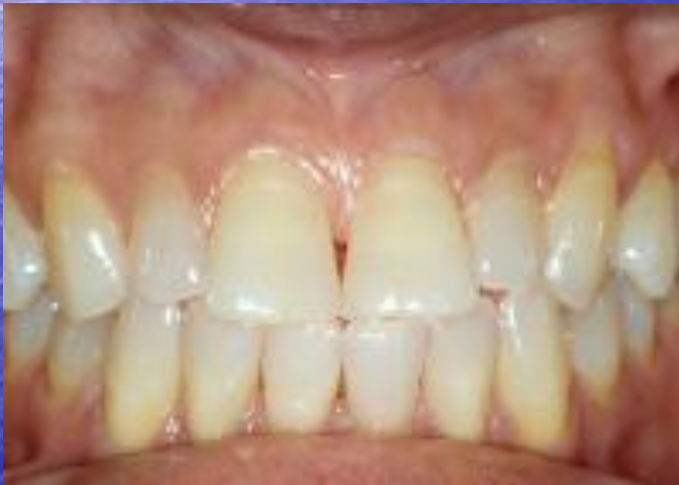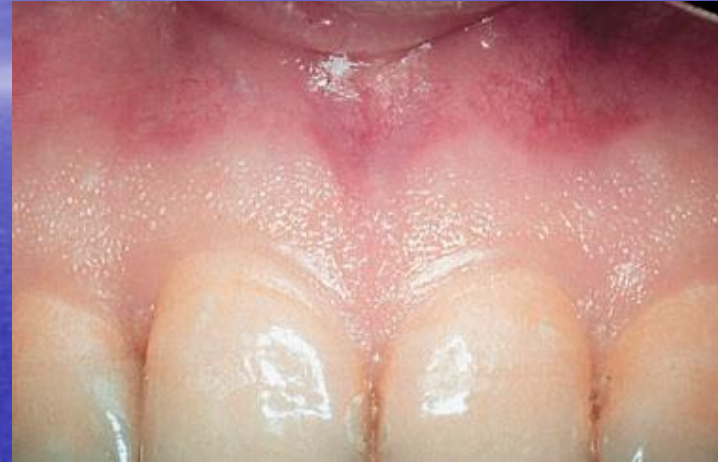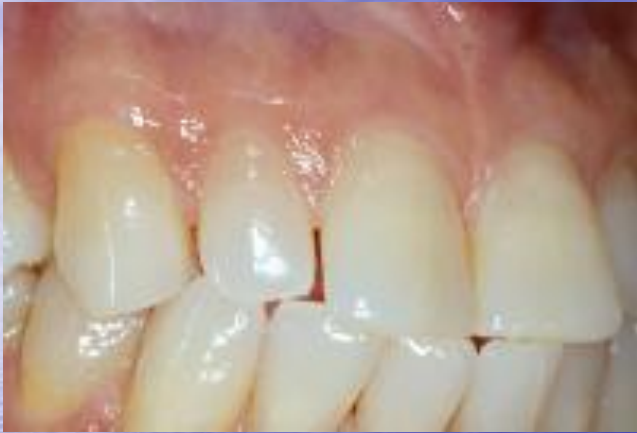- **Záchovná, terapeutická stomatológia**
Kariológia
Endodoncia
- **Parodontológia**
- **Protetika**
- **Čelústna ortopédia, ortodoncia**
- **Dentoalveolárna chirurgia**
Maxilofaciálna chirurgia

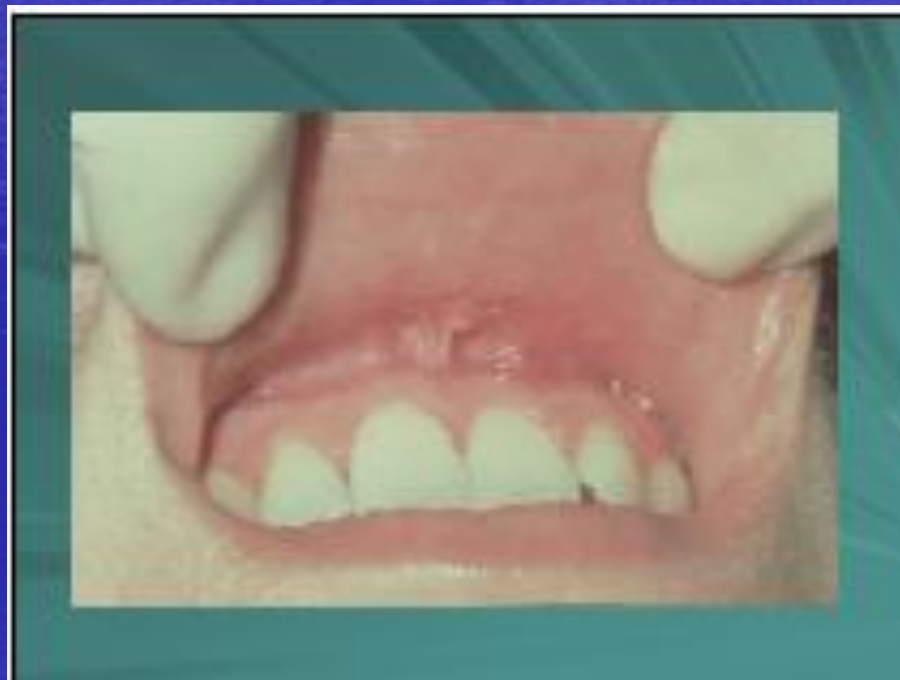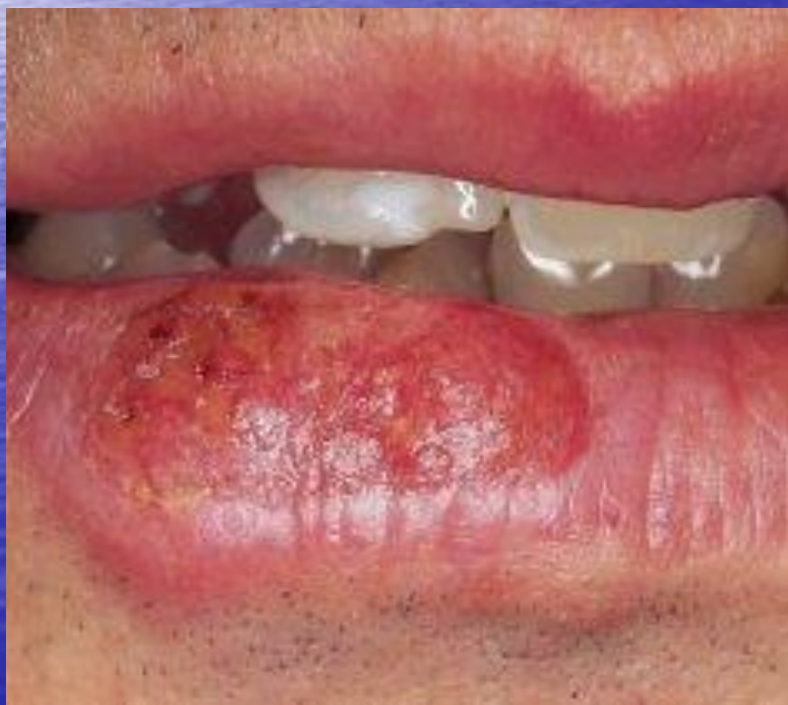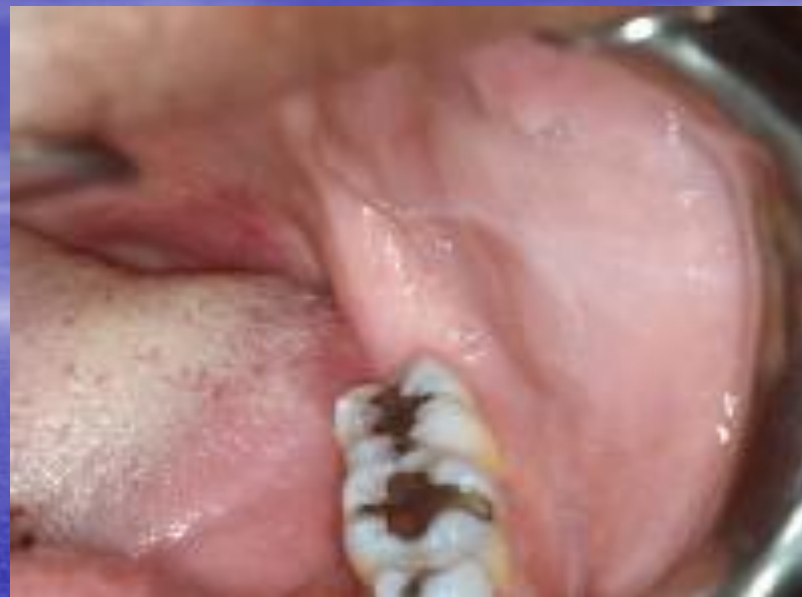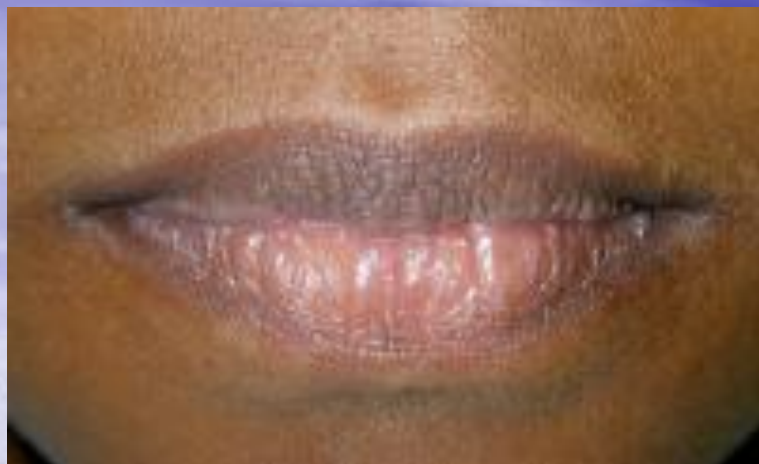Vyšetrenie pacienta

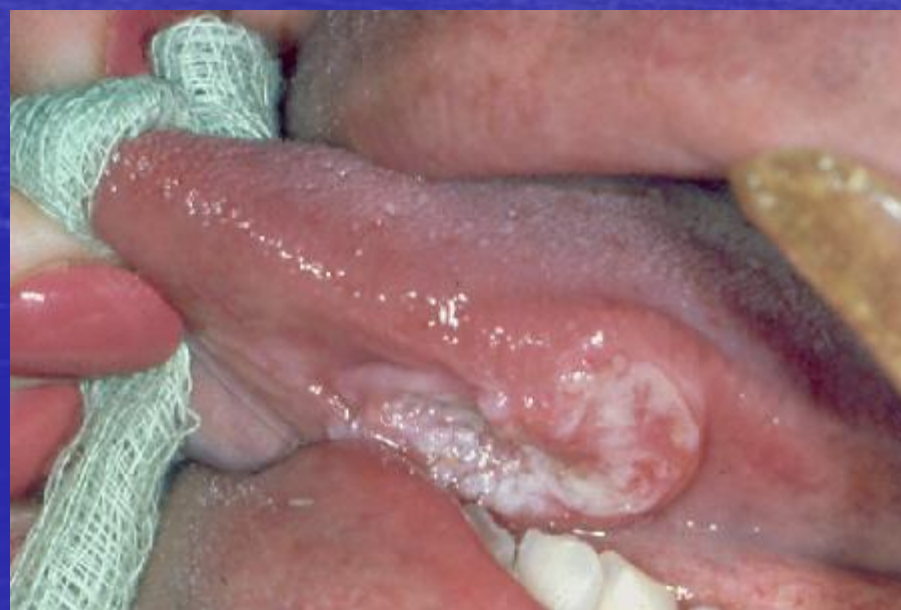
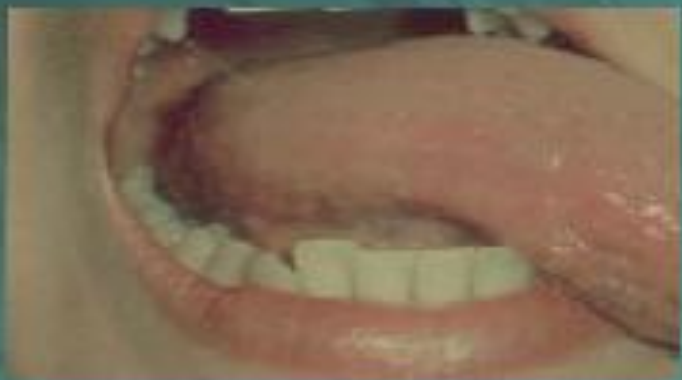
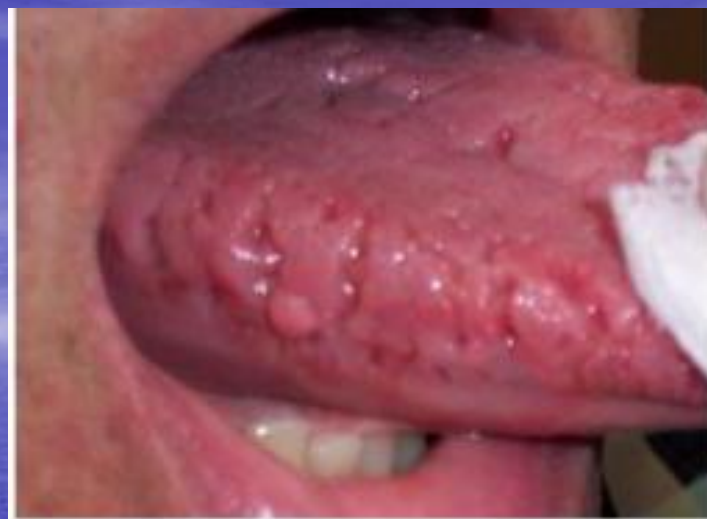
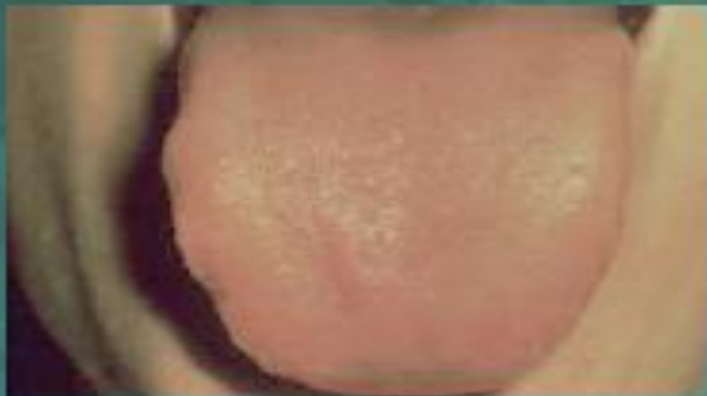
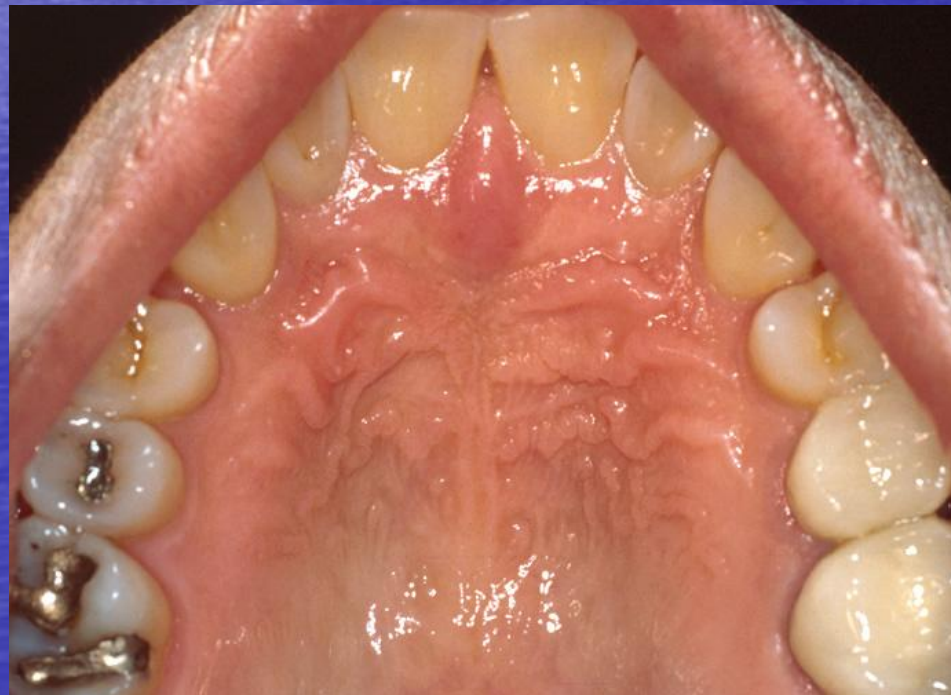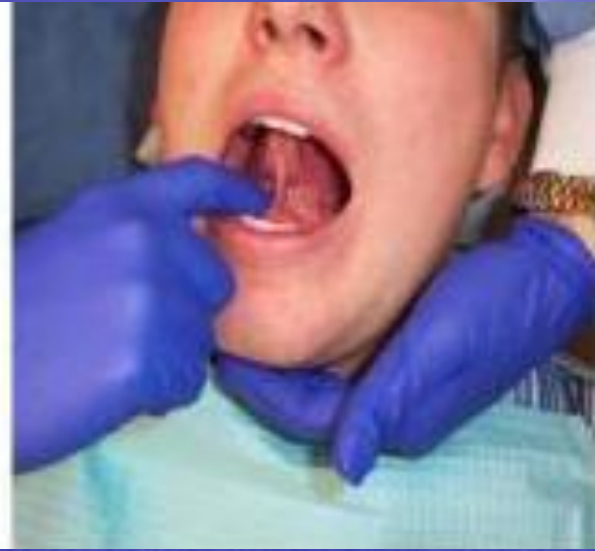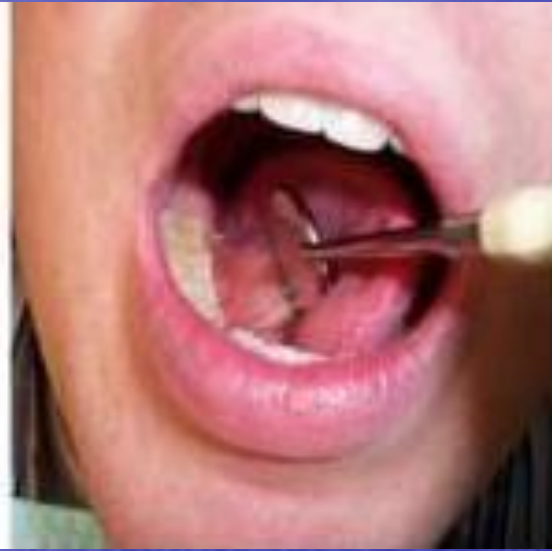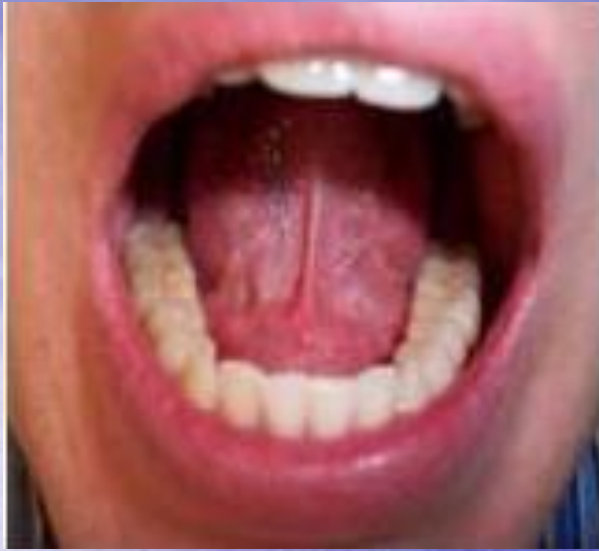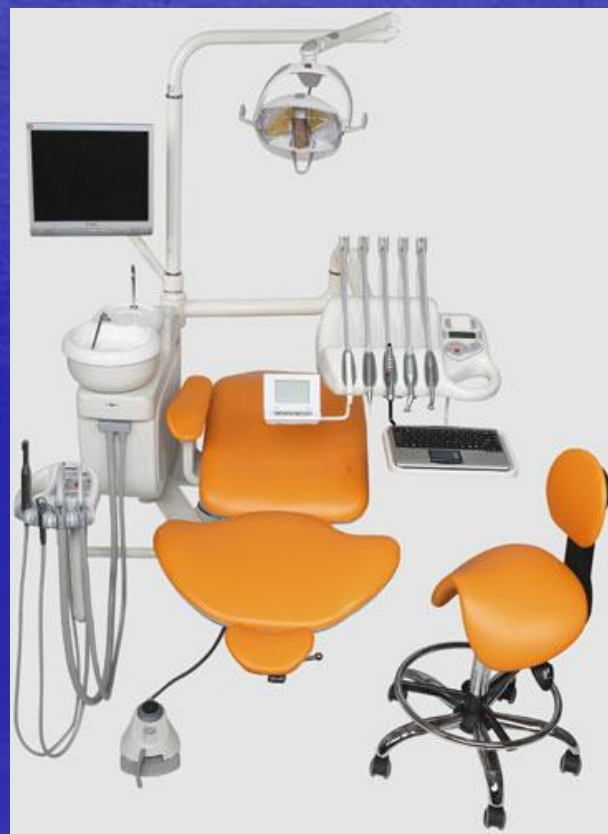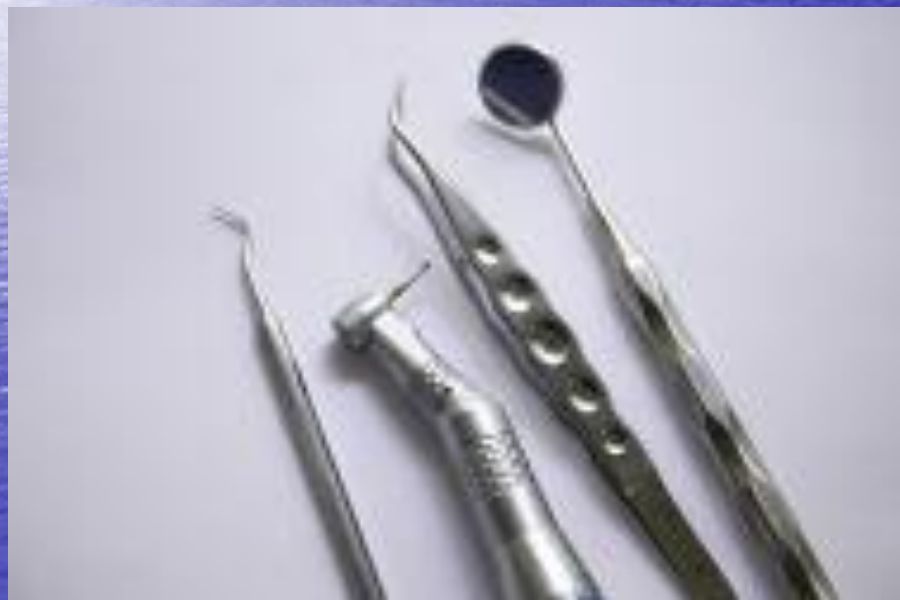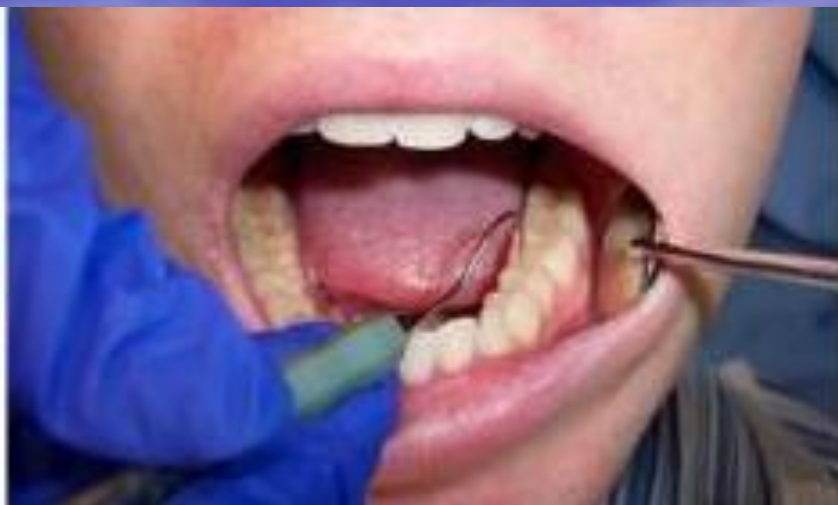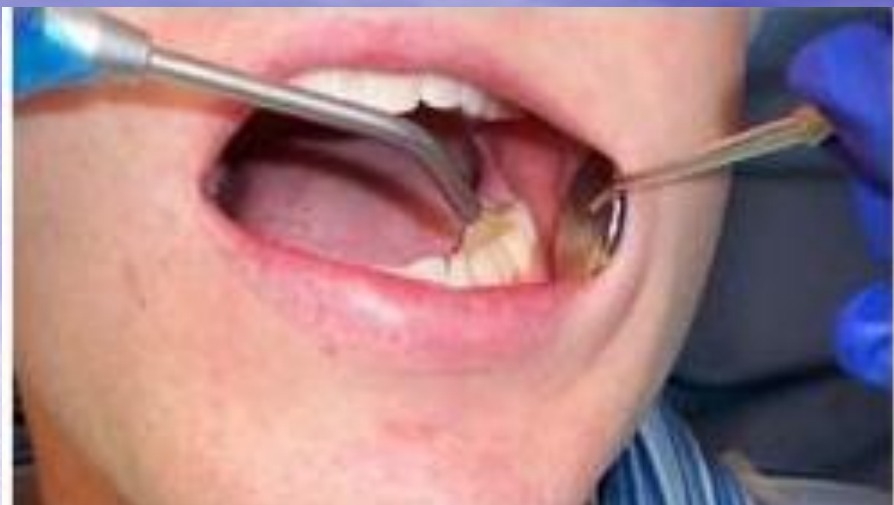Intraorálne vyšetrenie



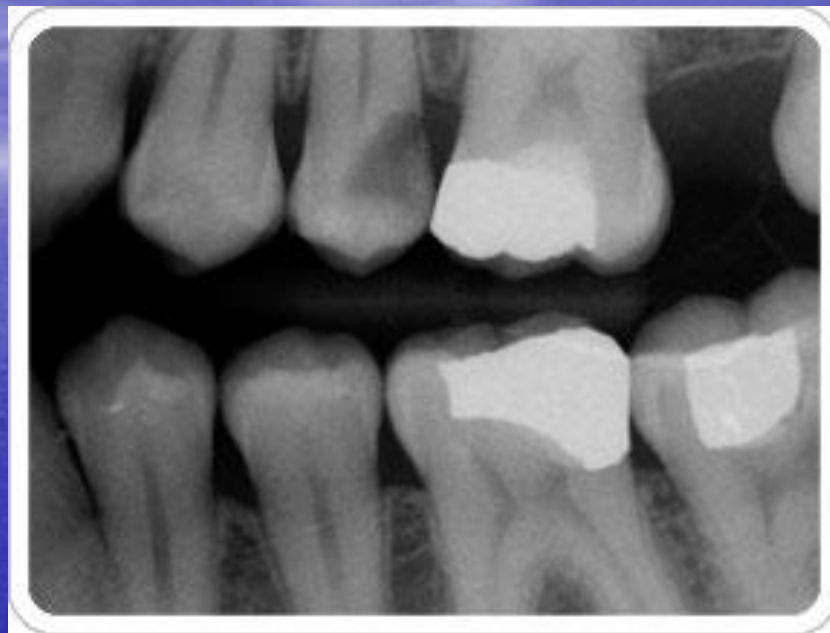
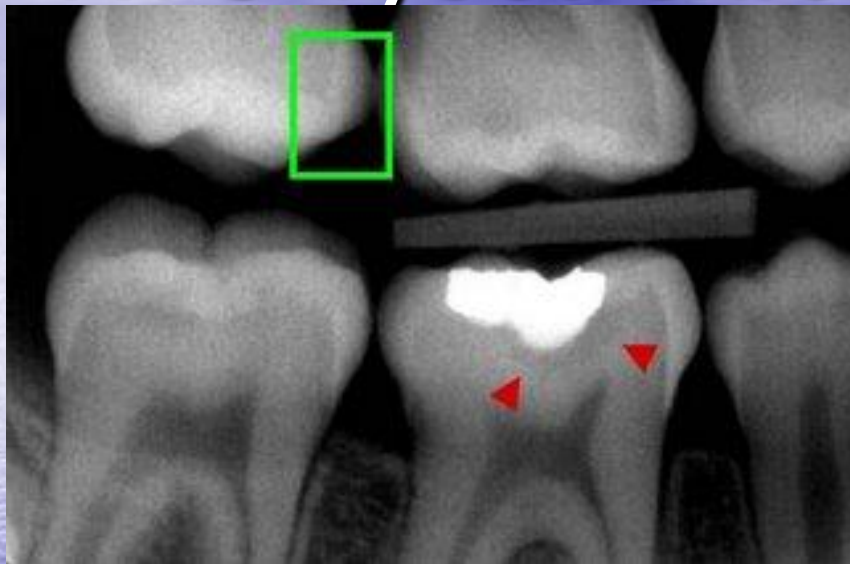


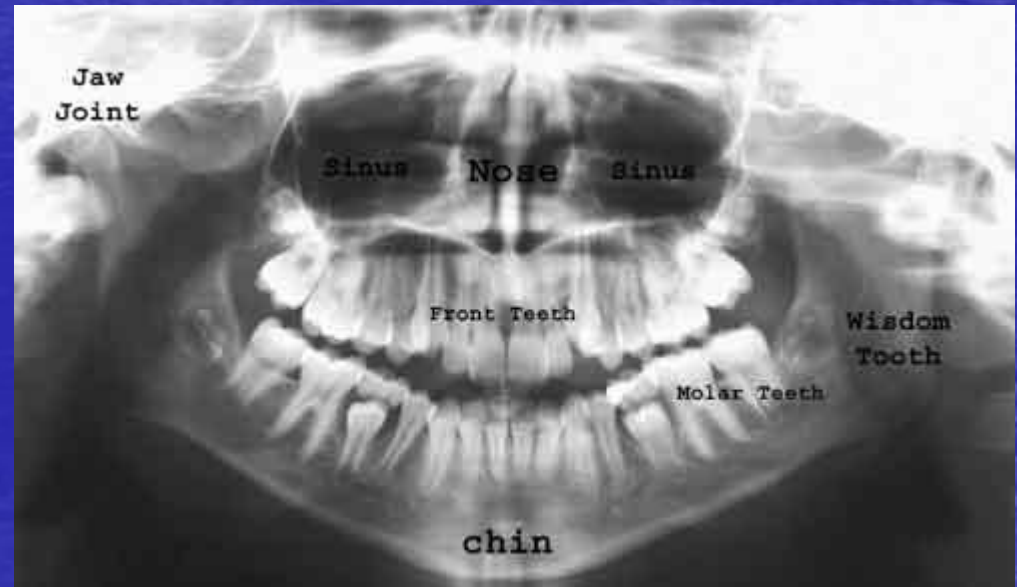
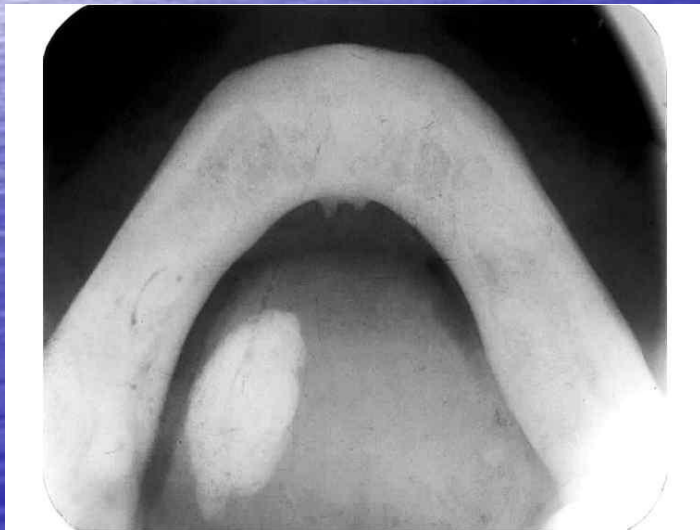
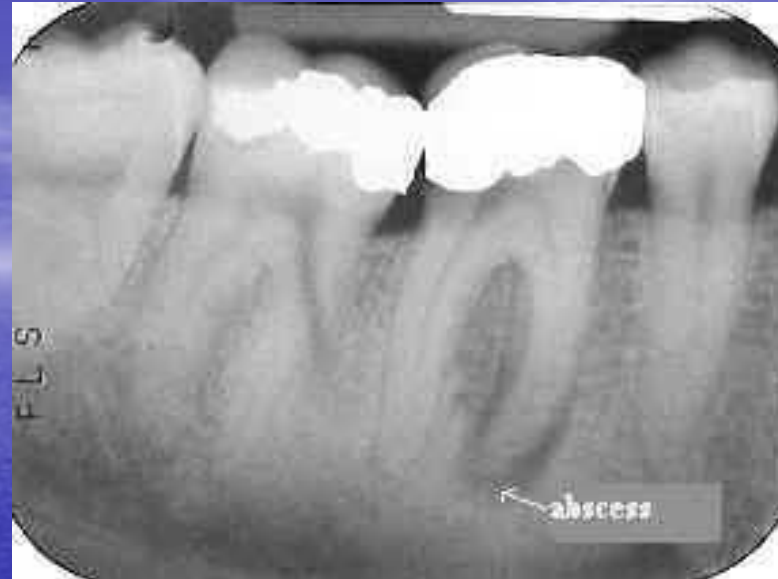
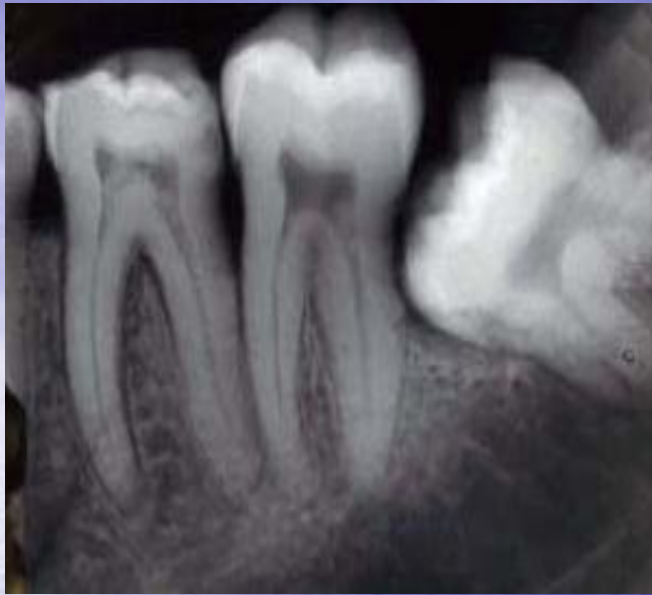


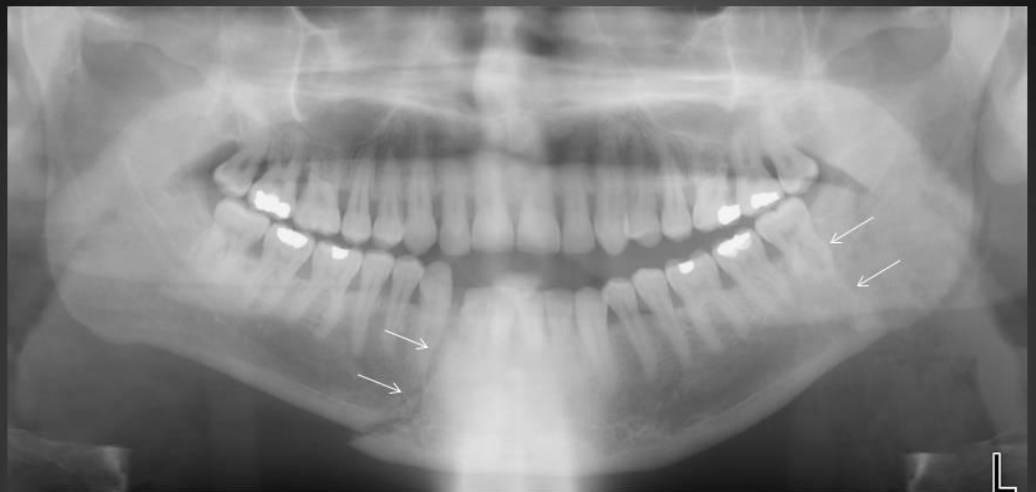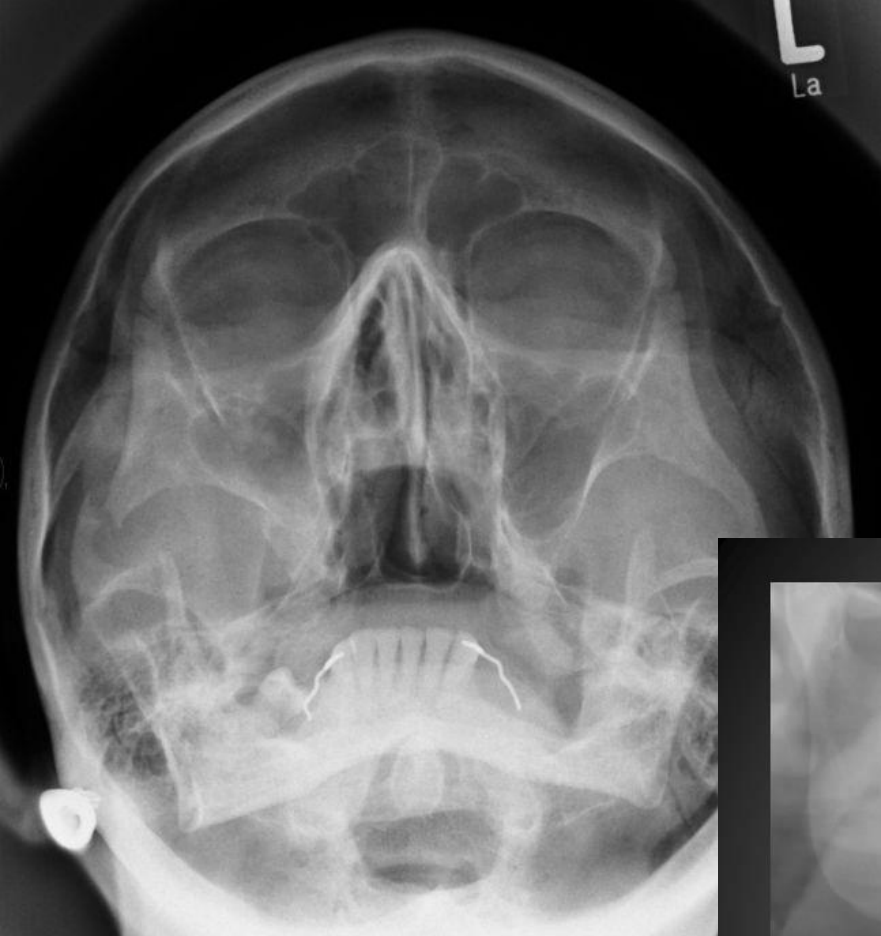RTG vyšetrenie

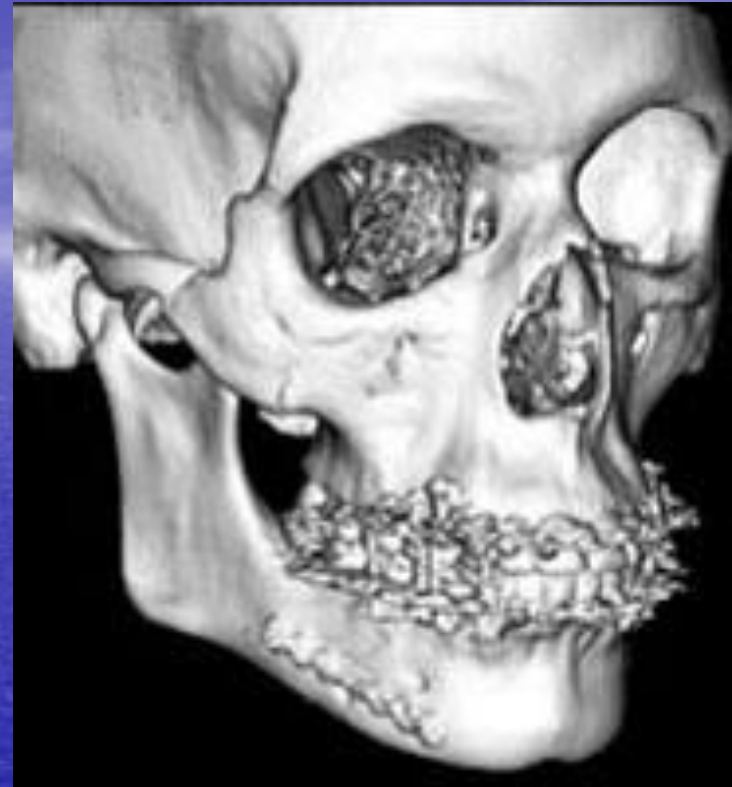
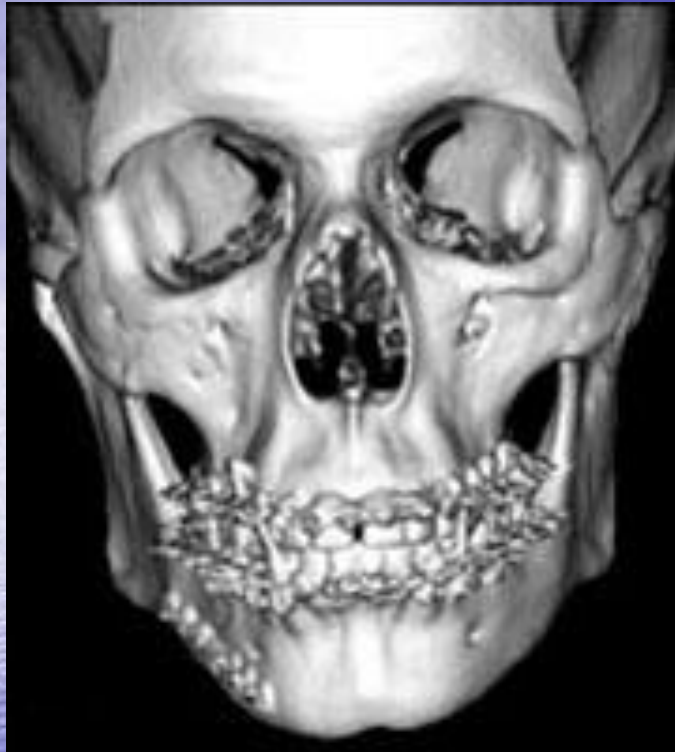

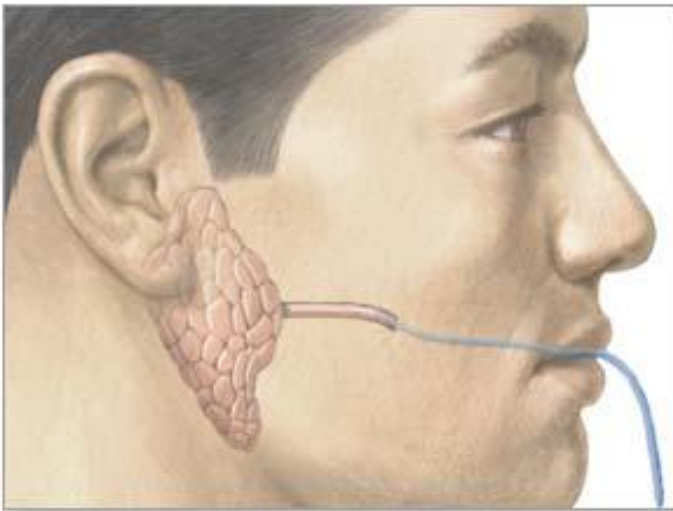




Ring Fracture

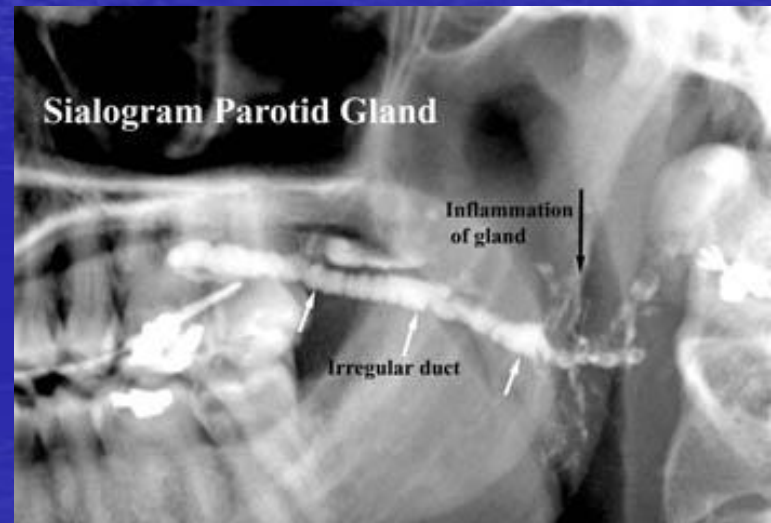
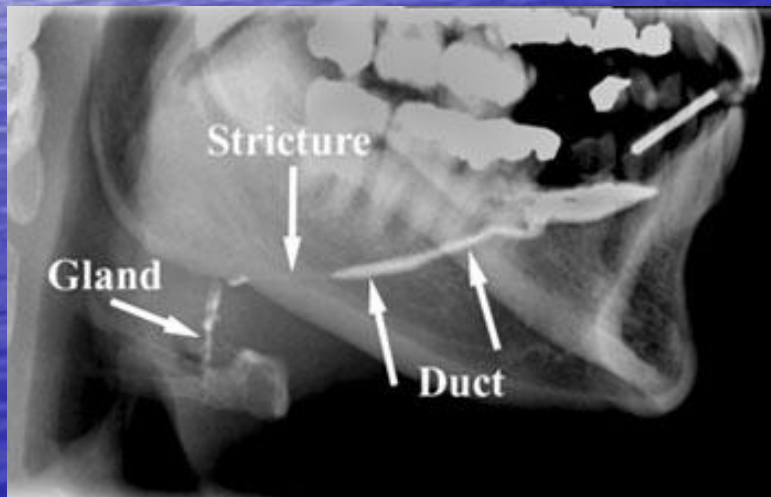
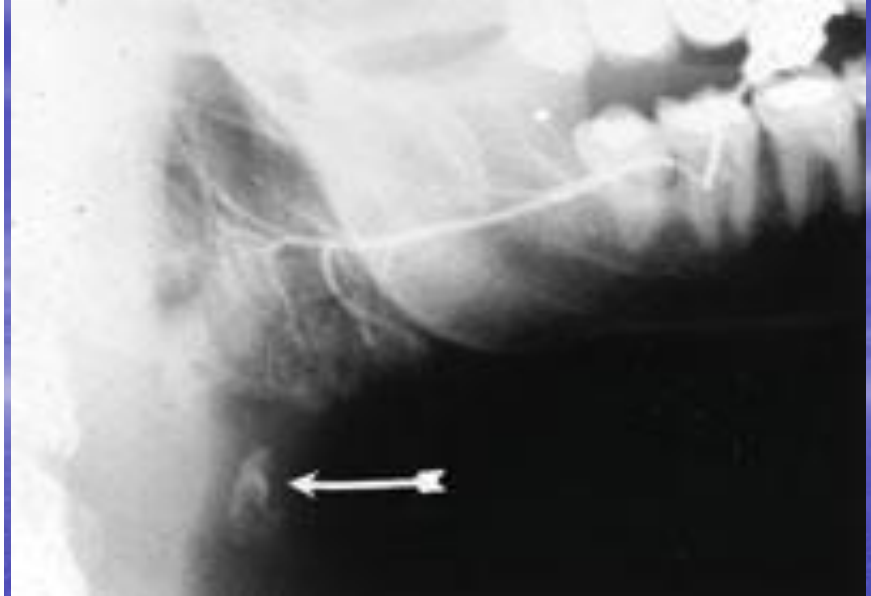
Fractures through the right mandible (partially displaced) with a fracture of the left angle of mandible (note there are overlapping fragments)

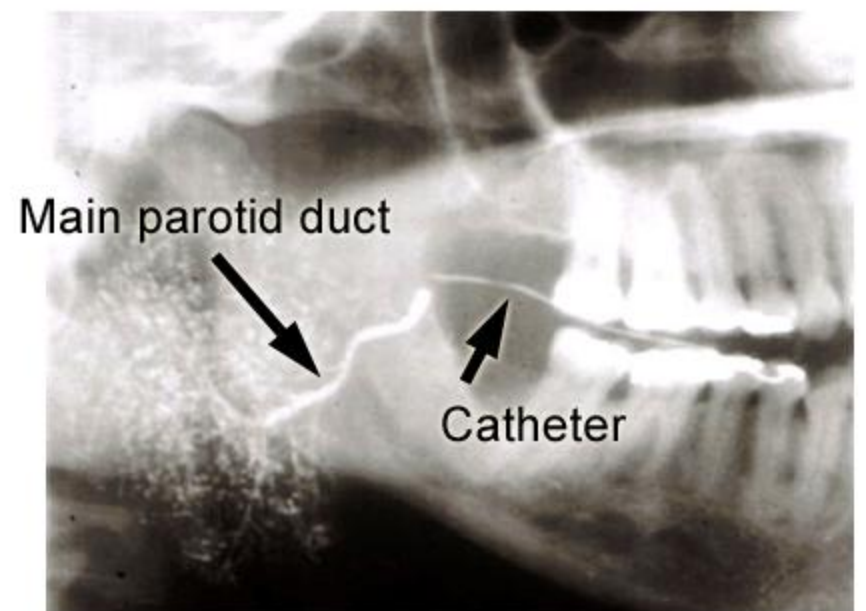
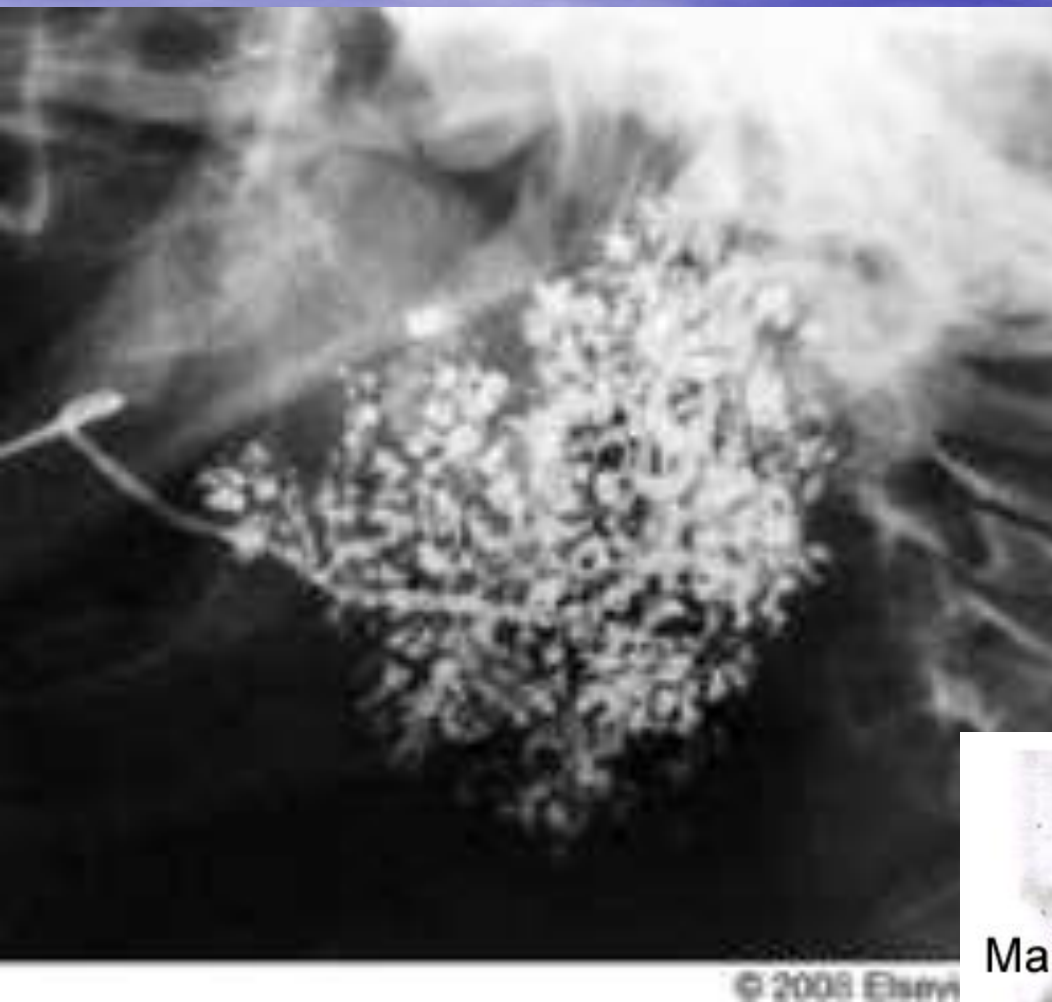




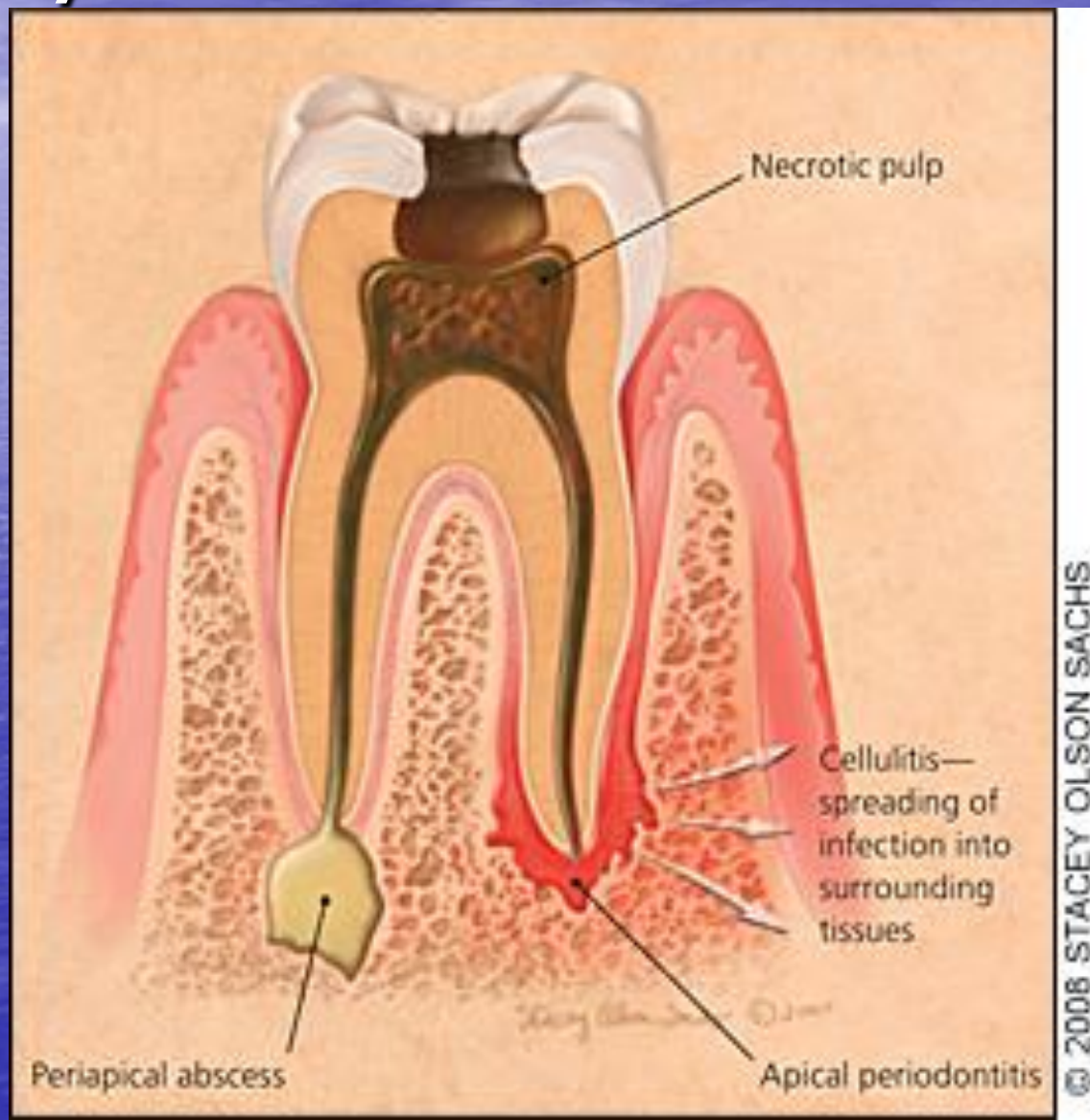
Contrast medium is injected
into the salivary gland duct

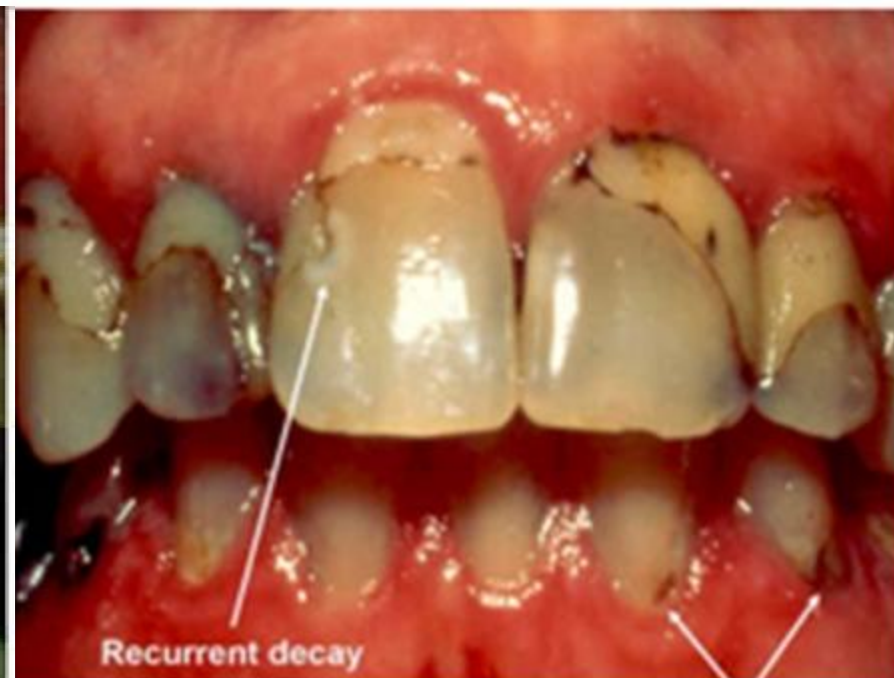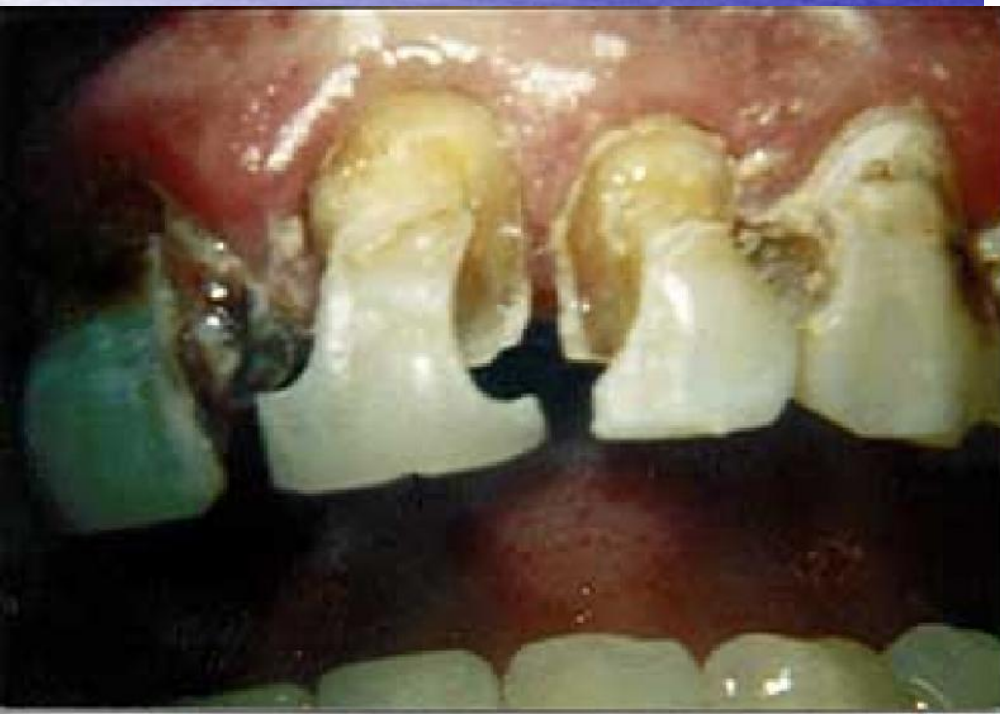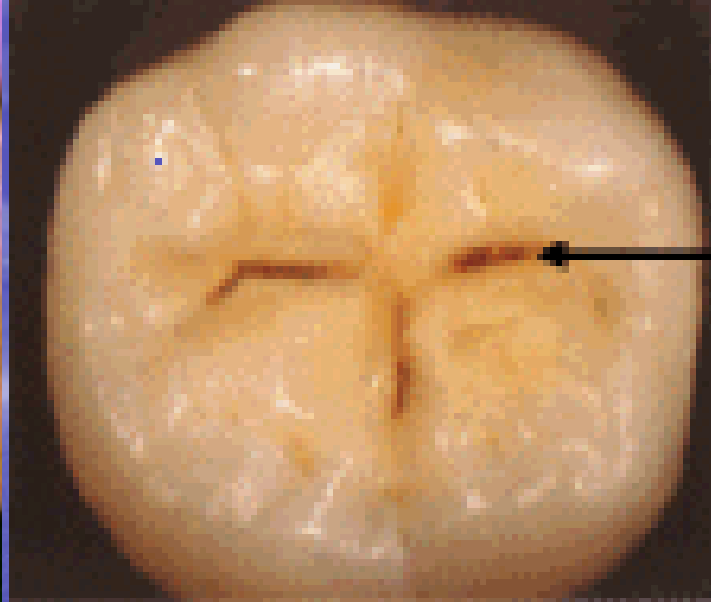
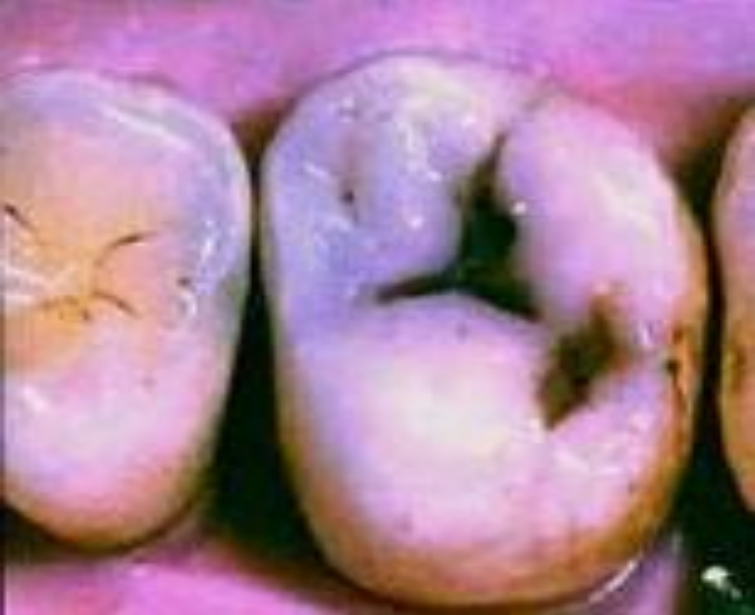ADAM.





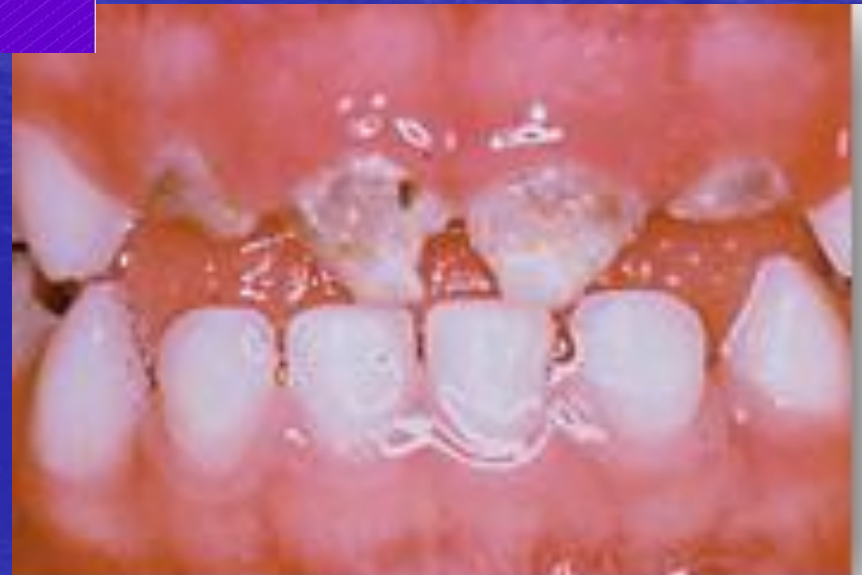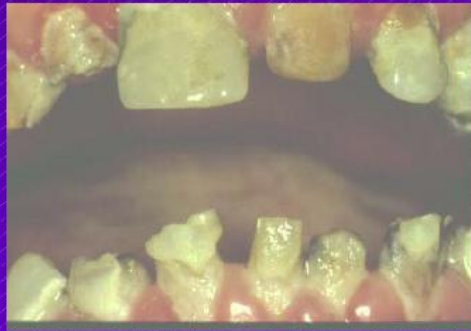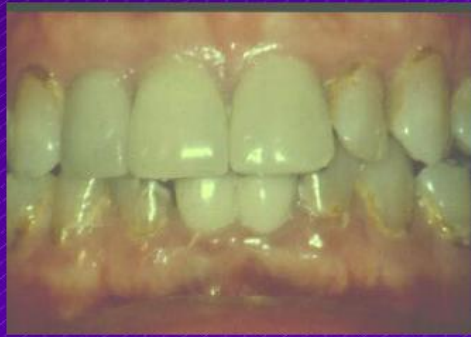Zubný kaz



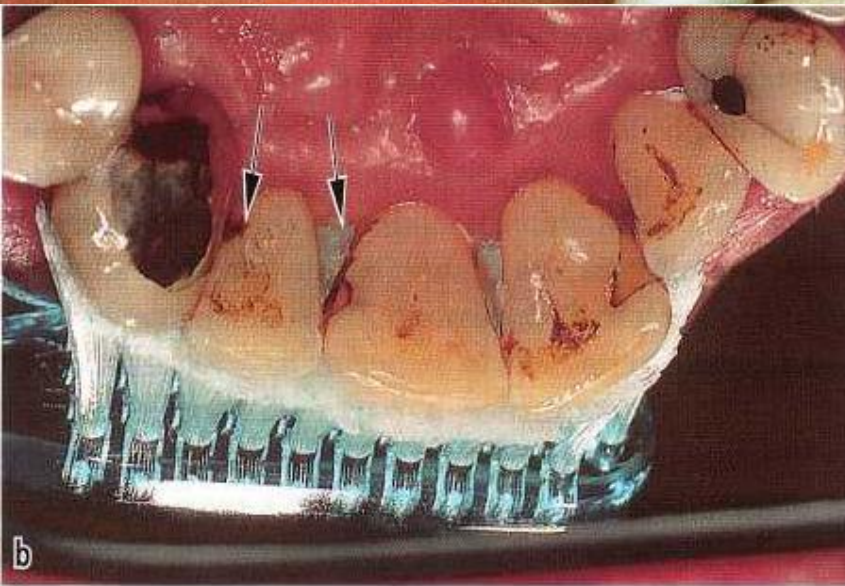
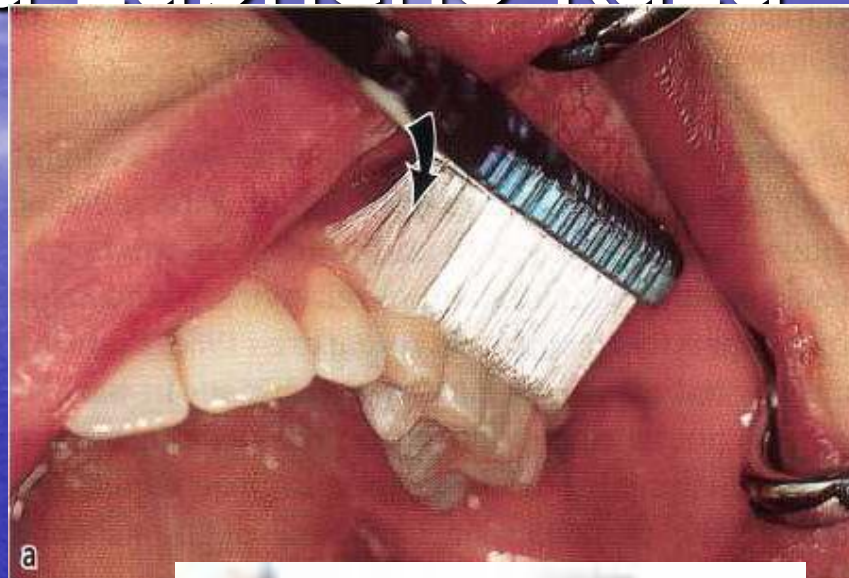
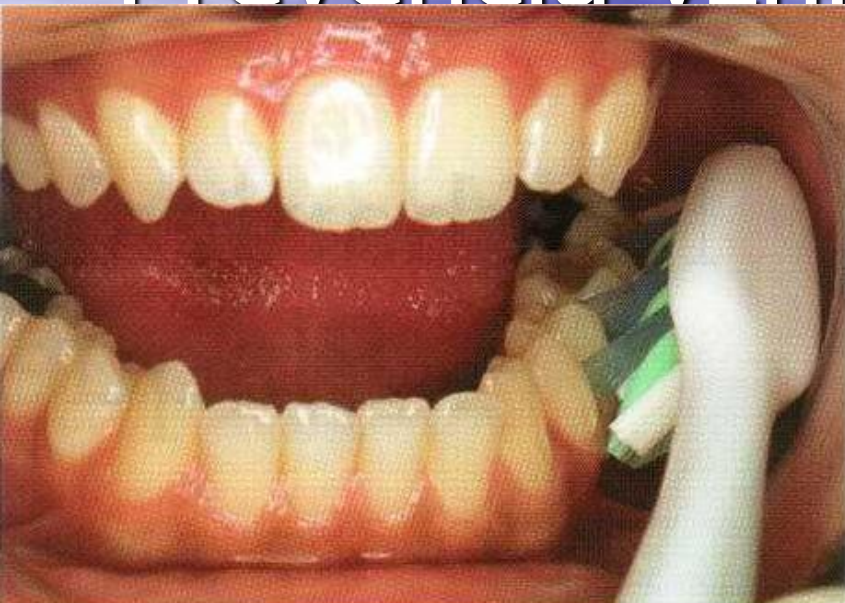

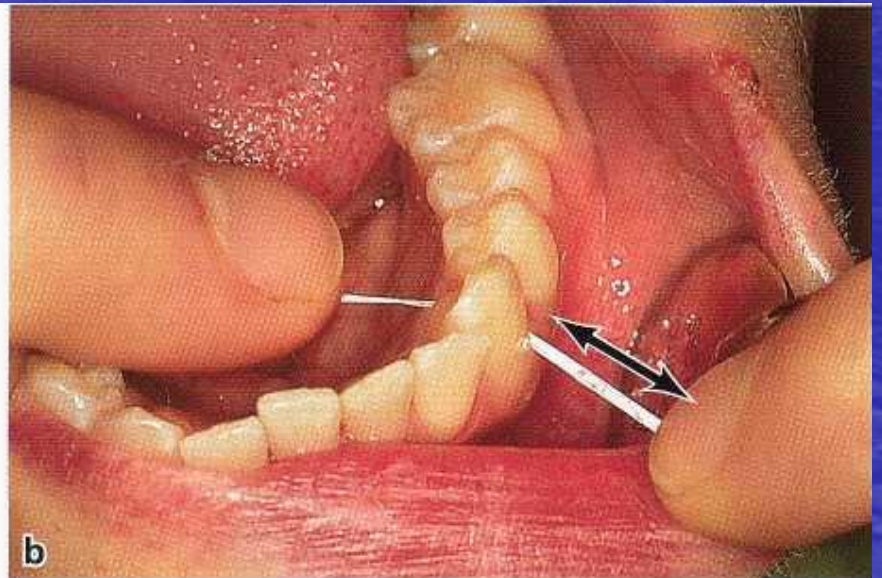
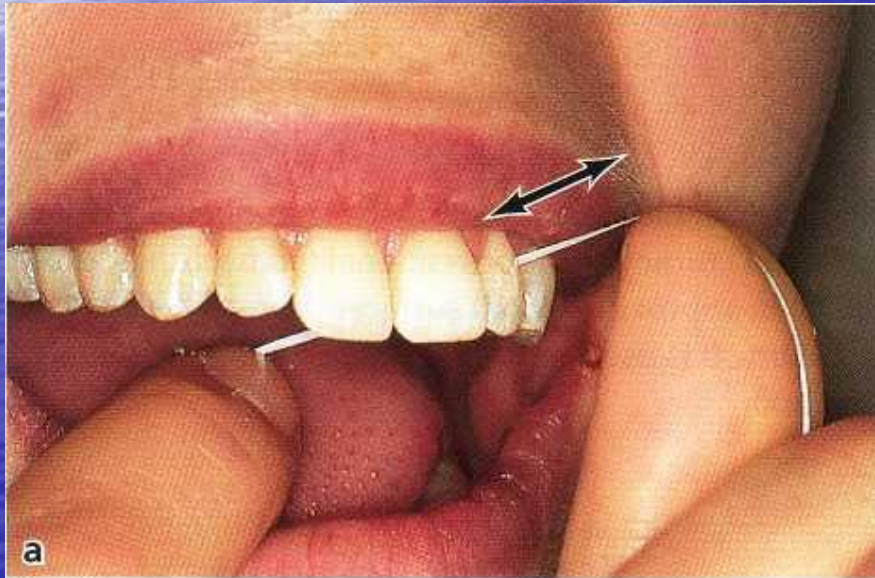
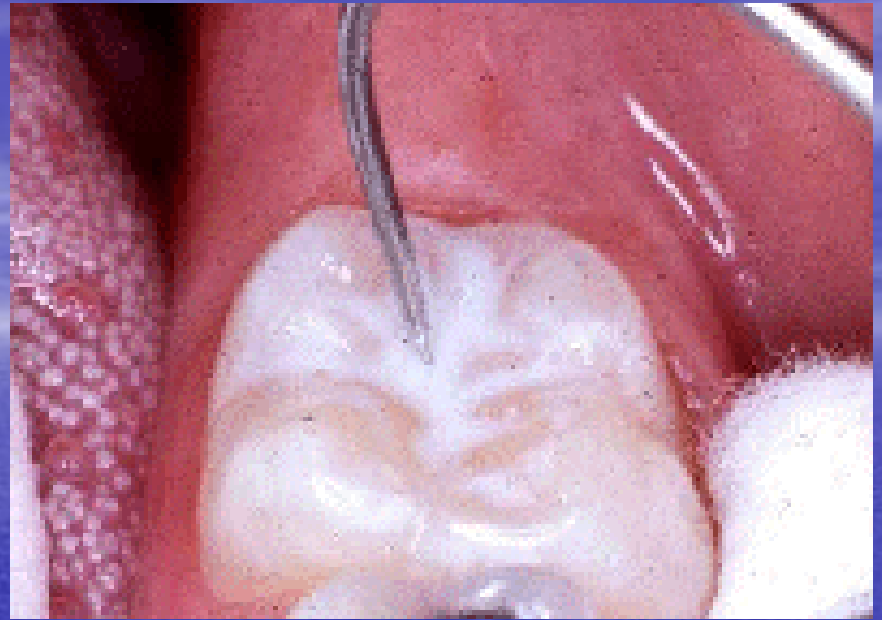
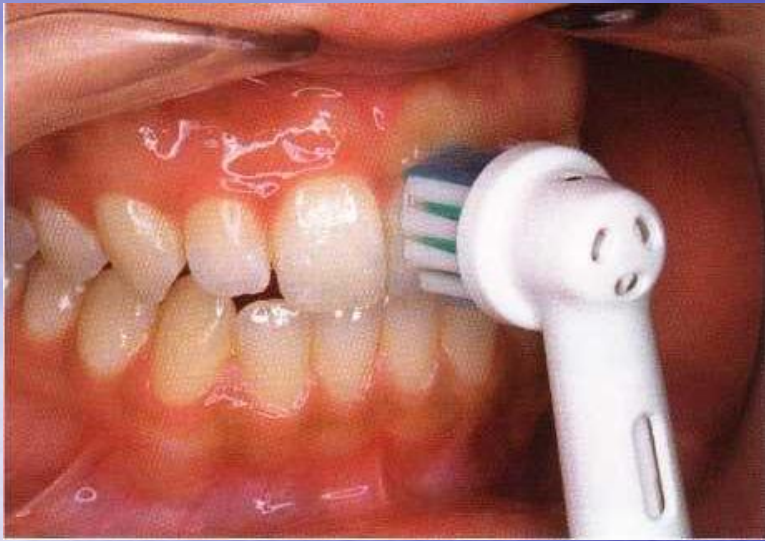
Radiation Caries

- may rapidly develop within 18 months

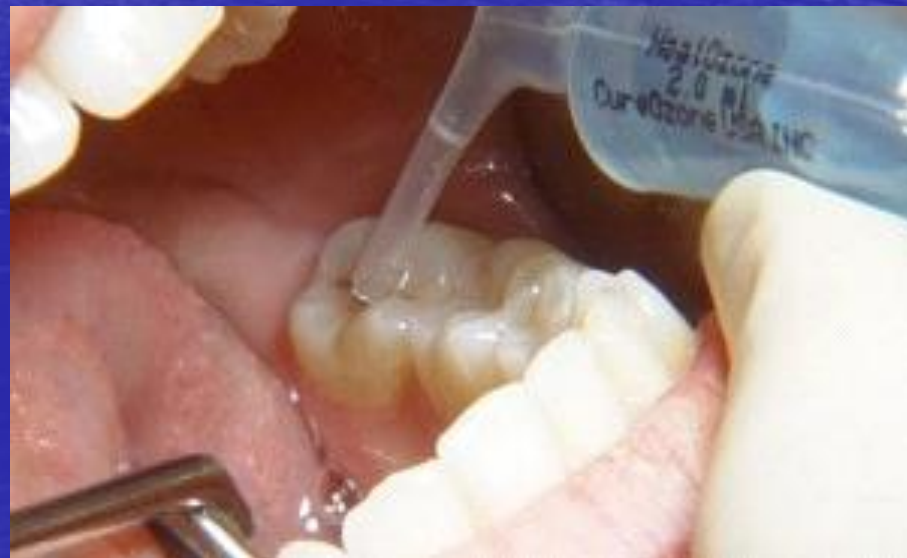
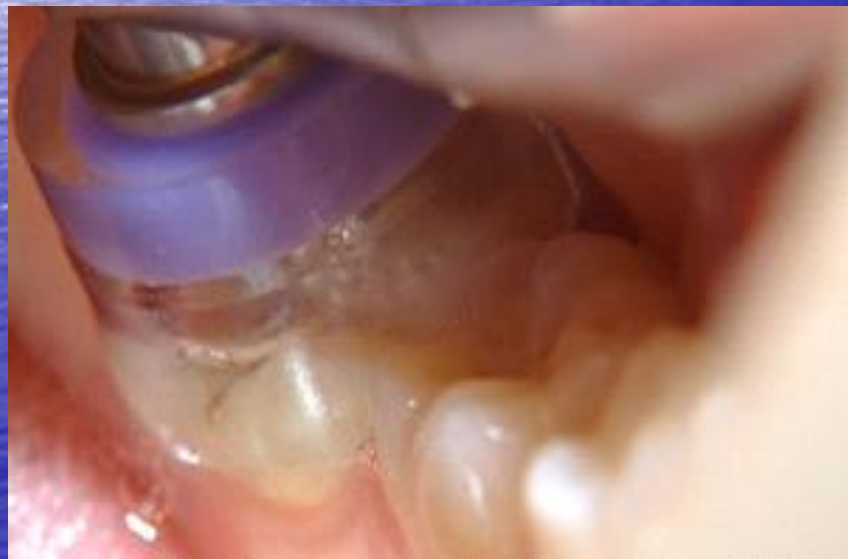
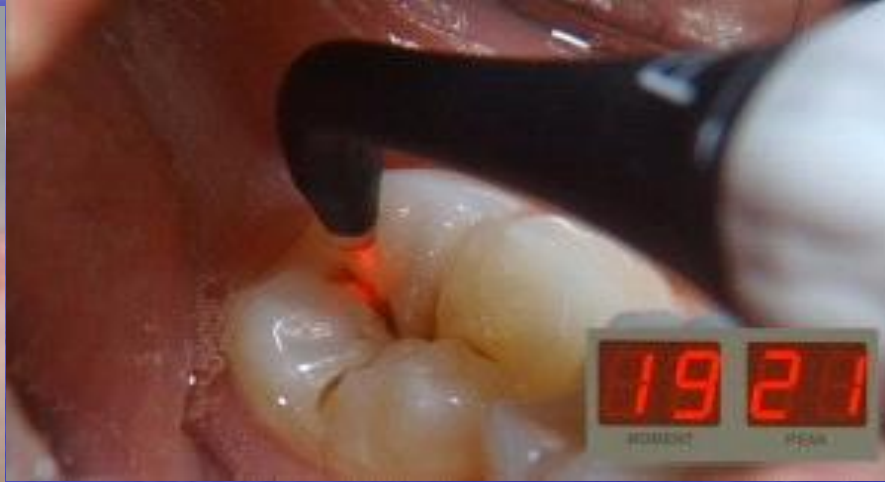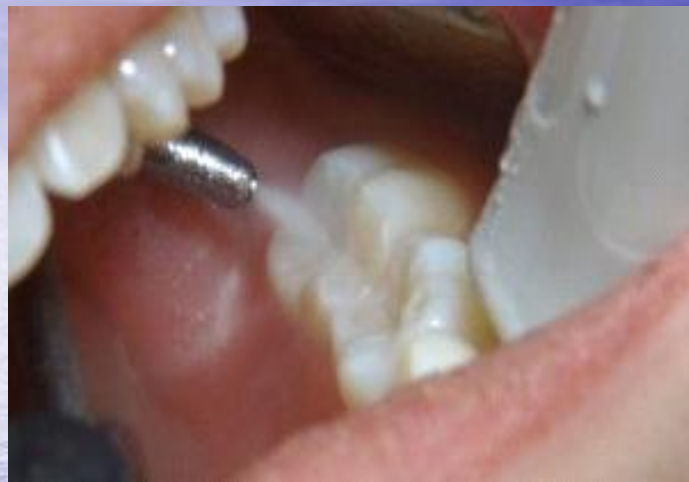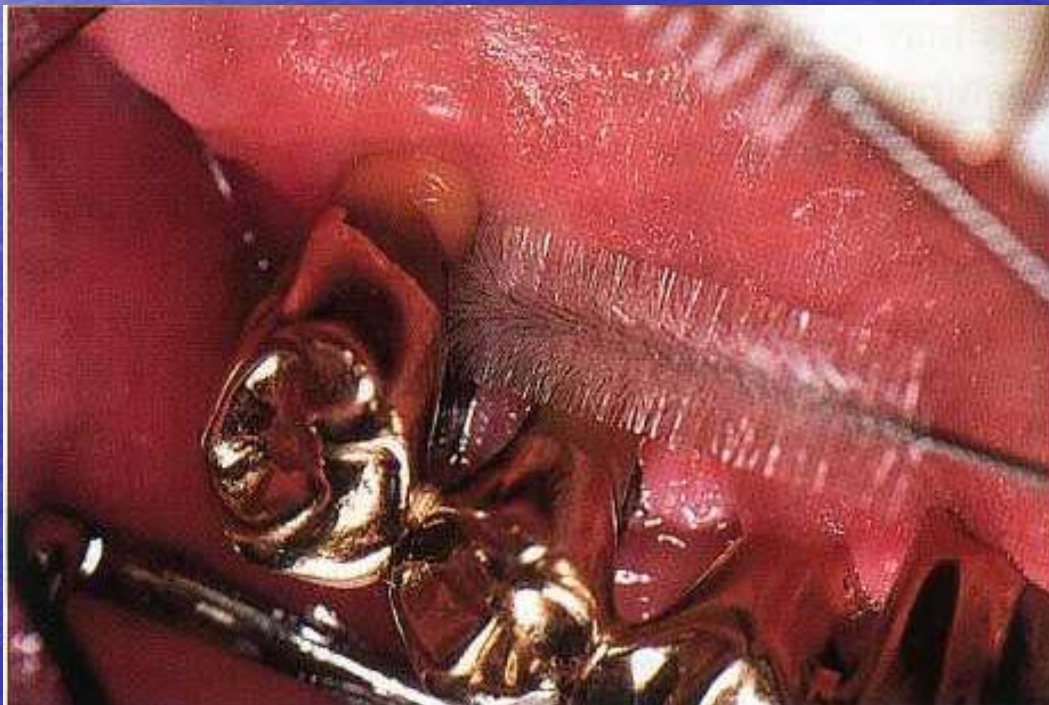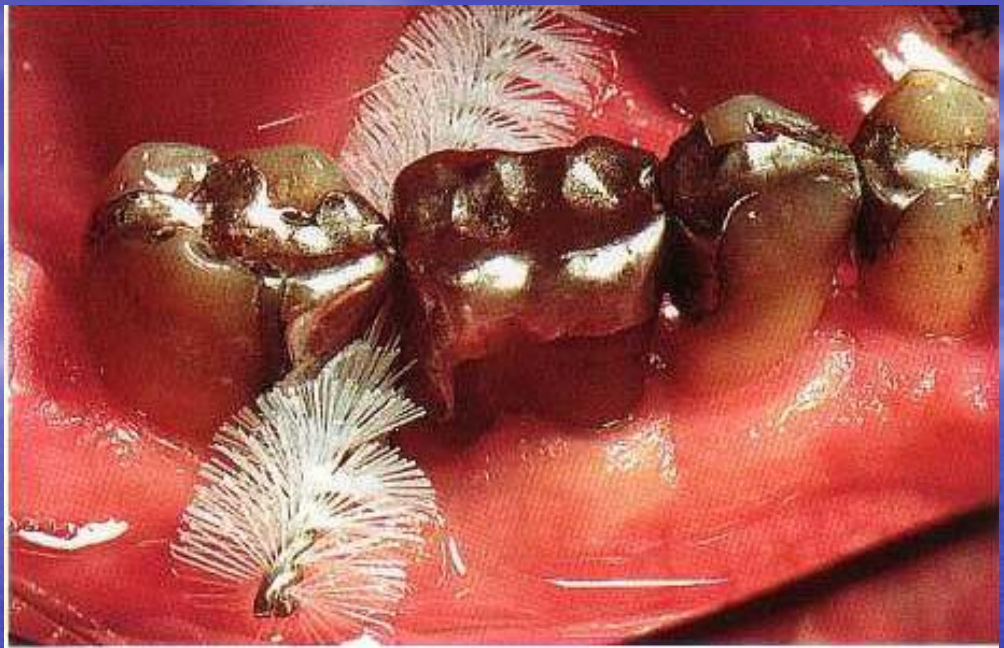Prevencia vzniku zubného kazu



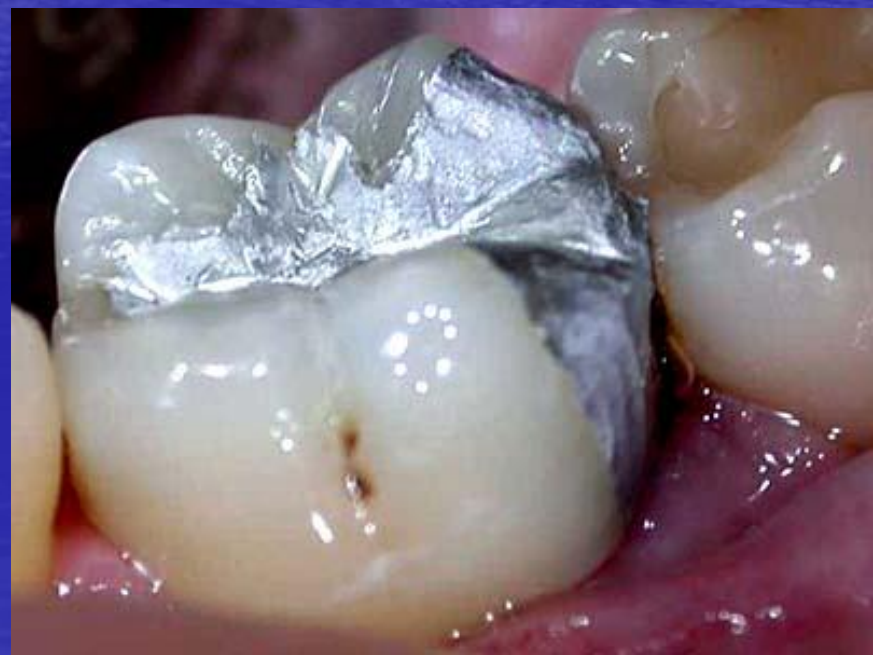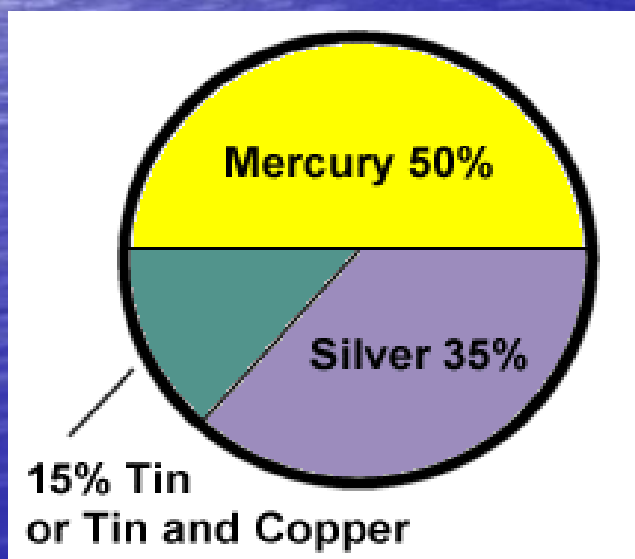

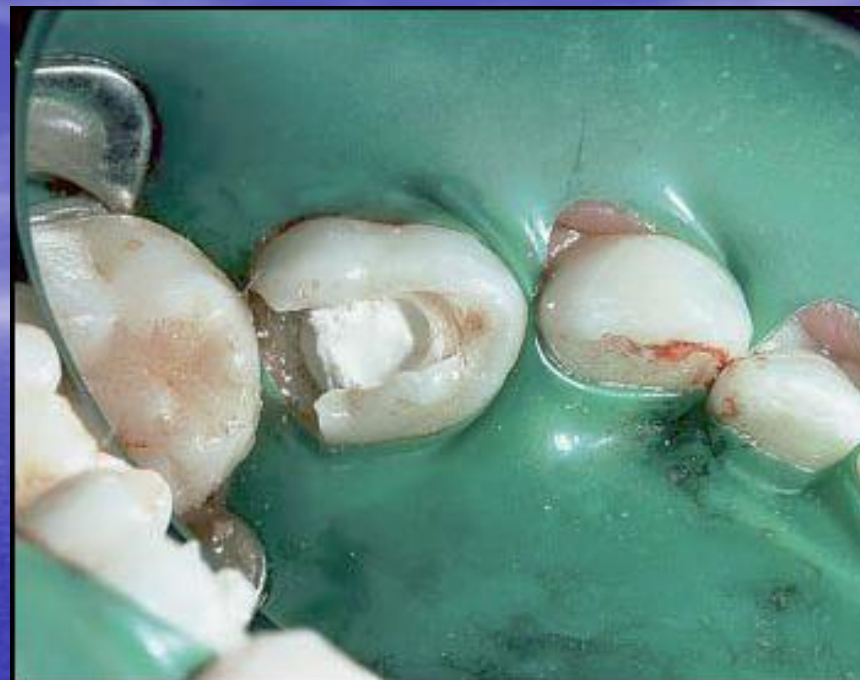
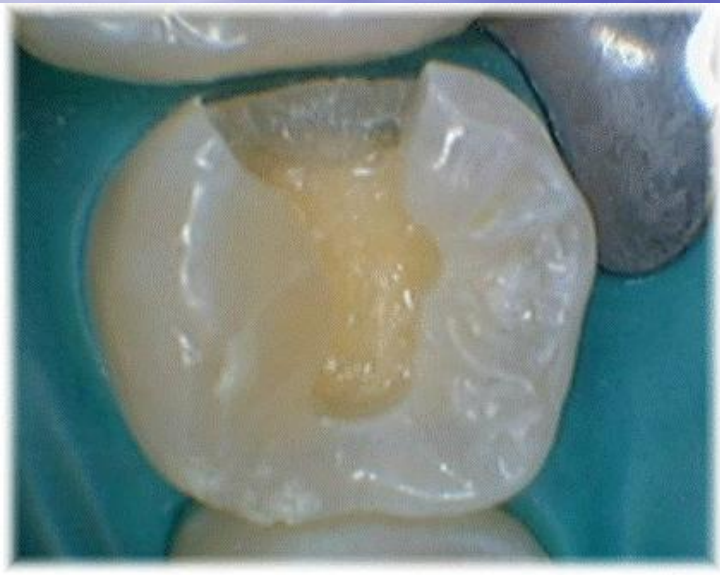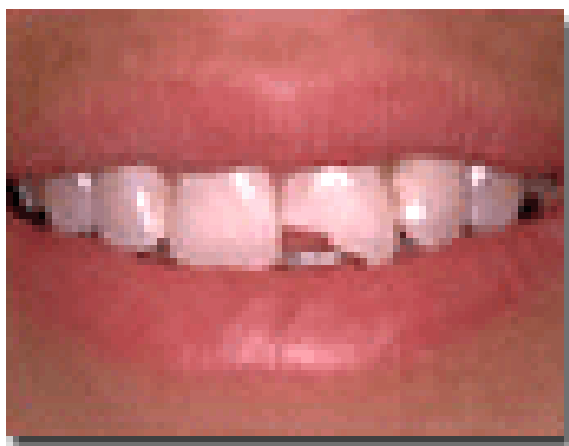
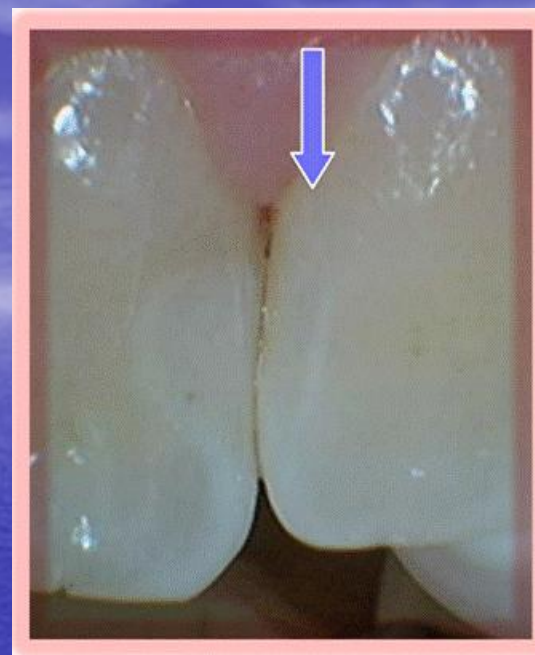
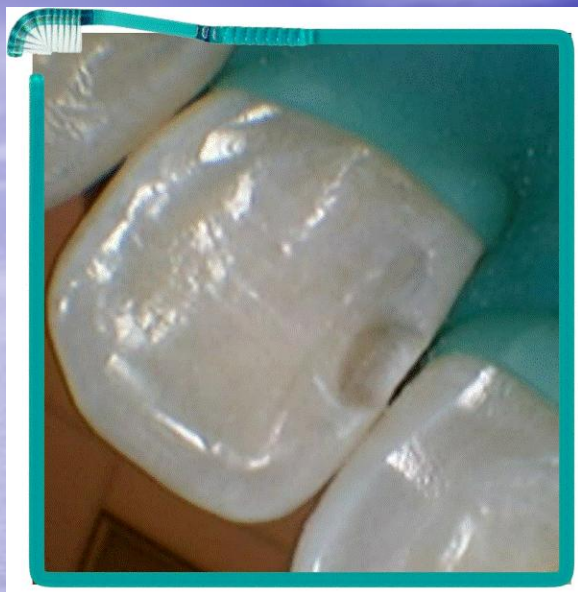Prevenca vzniku zubneho kazu



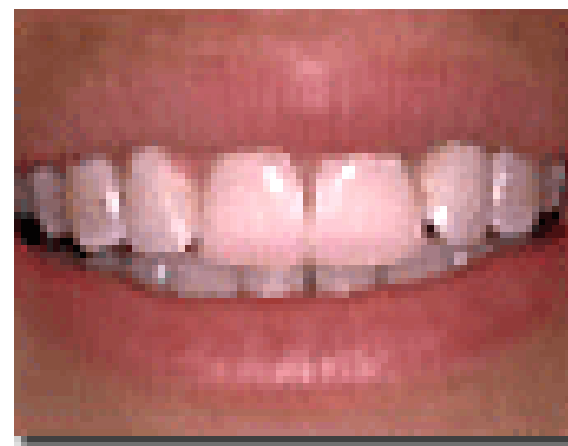


Liečba



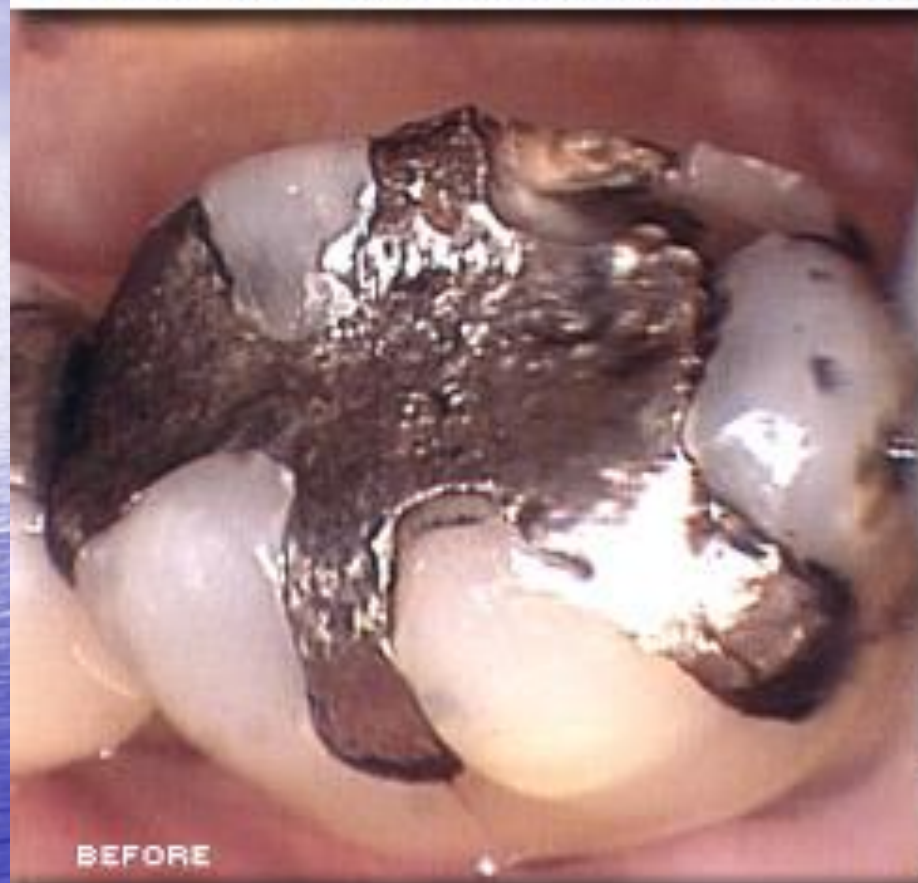

Before

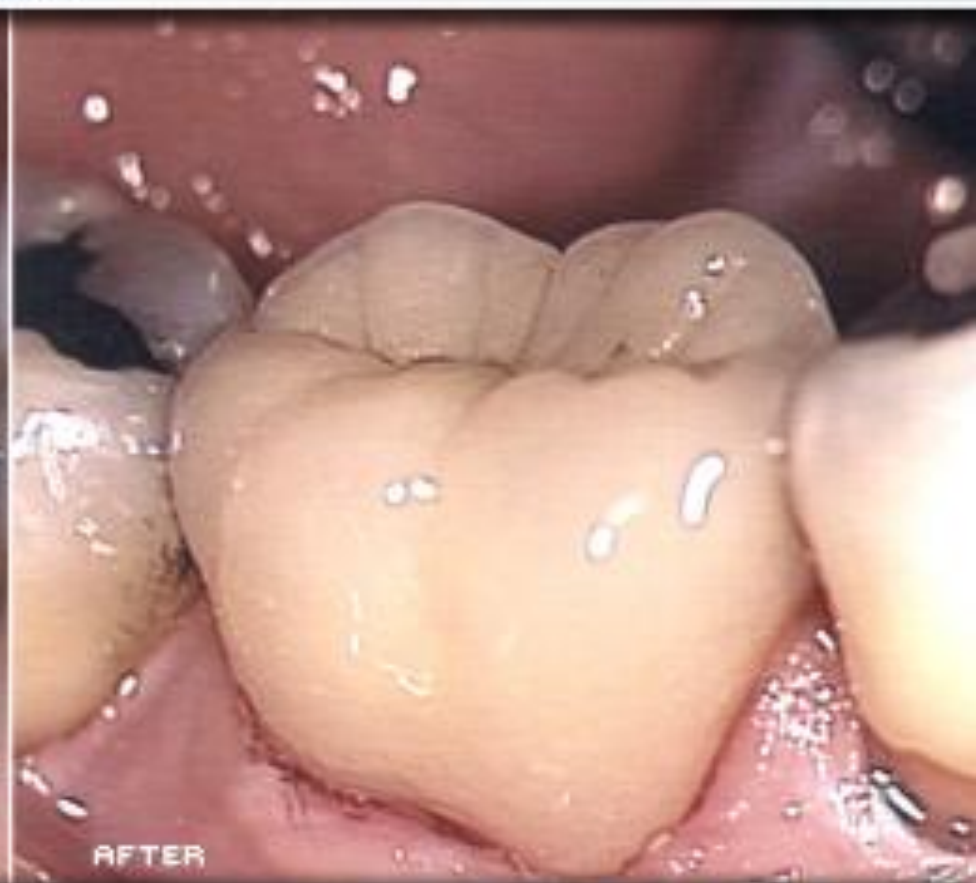

After

Peter H. Rubinstein D.M.D.



BEFORE

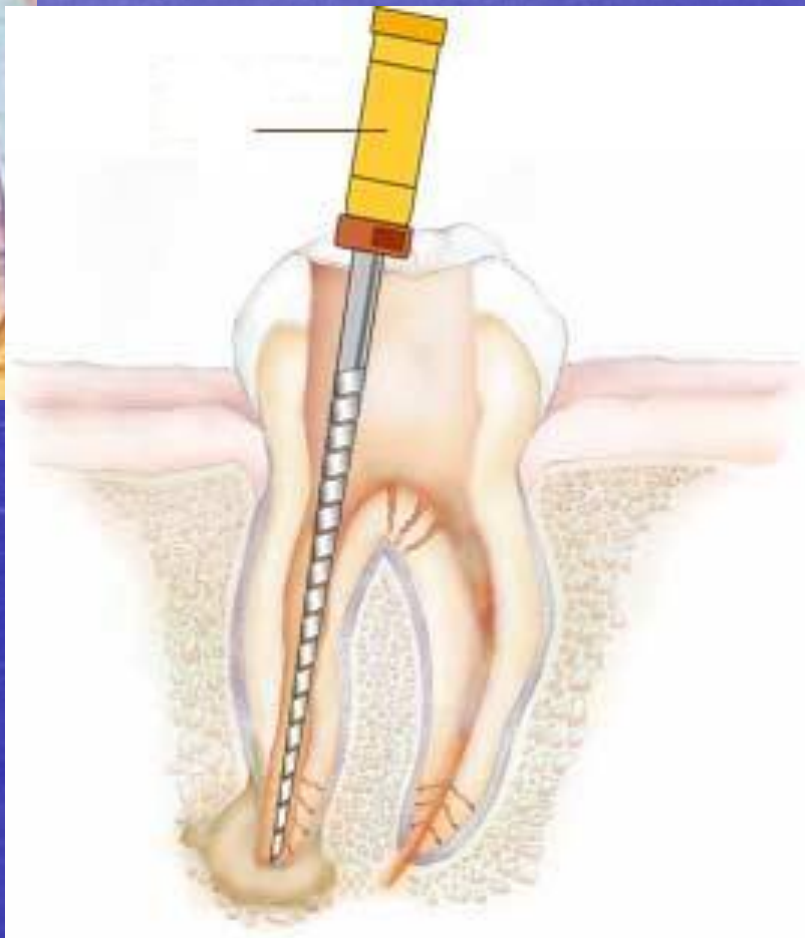
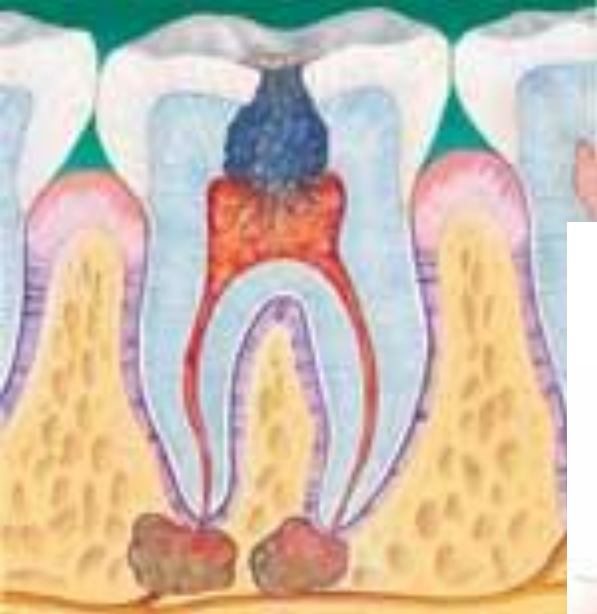

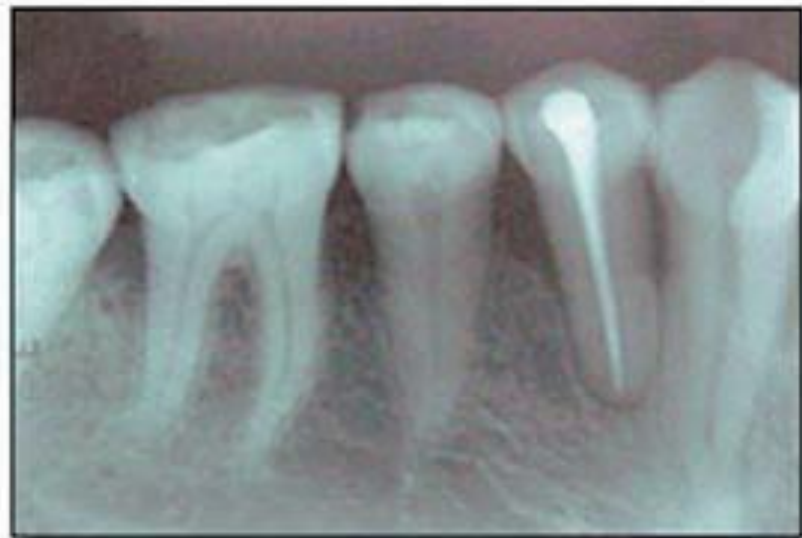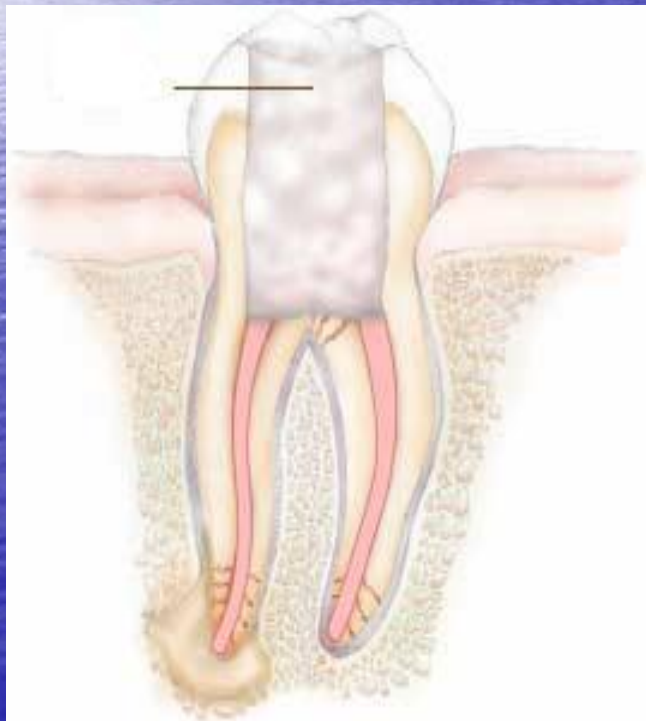
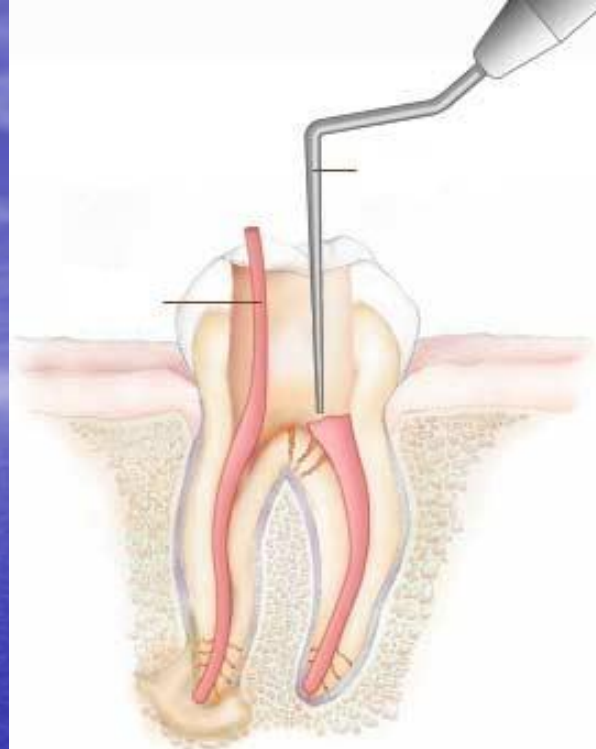
AFTER

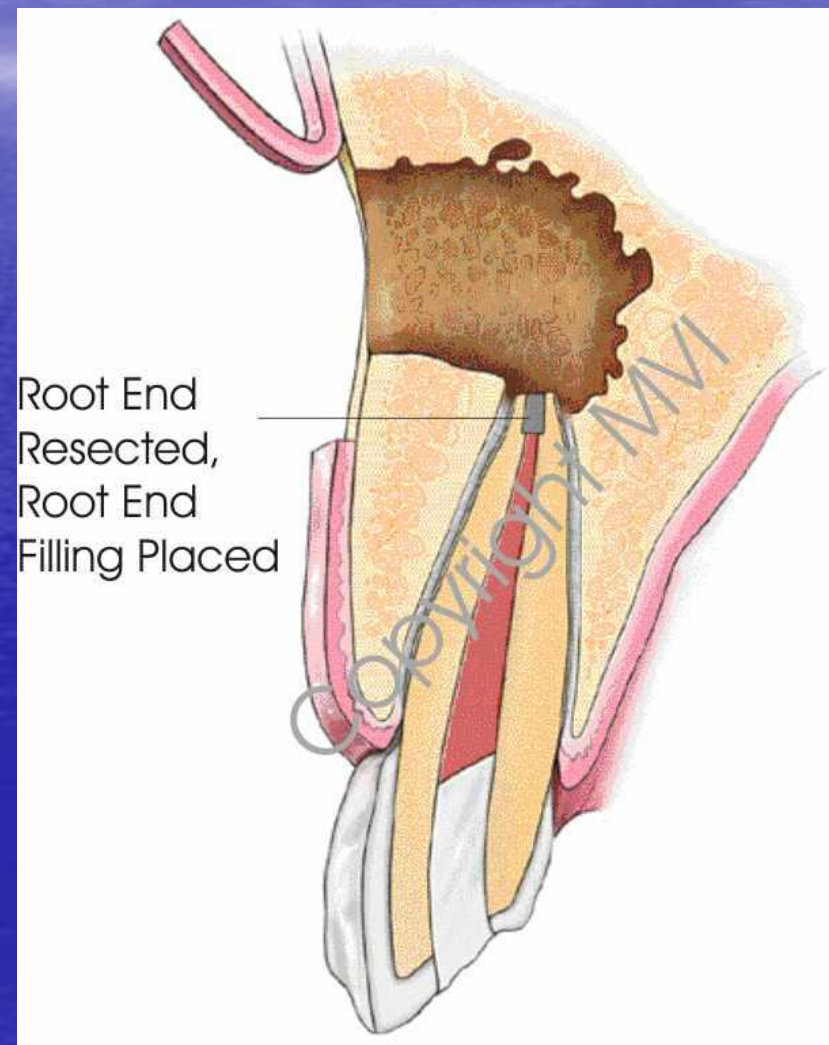
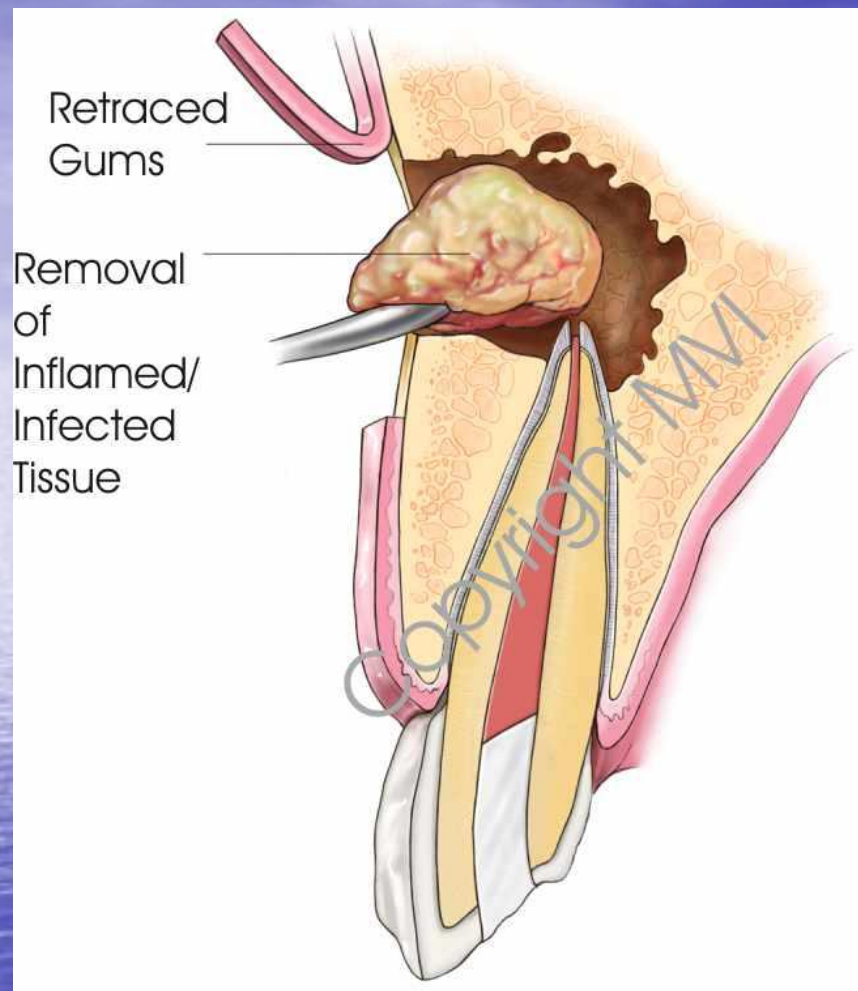
 Close Window

Call 212.995.8930

Komplikácie zubného kazu







Okoločelústné zápalý

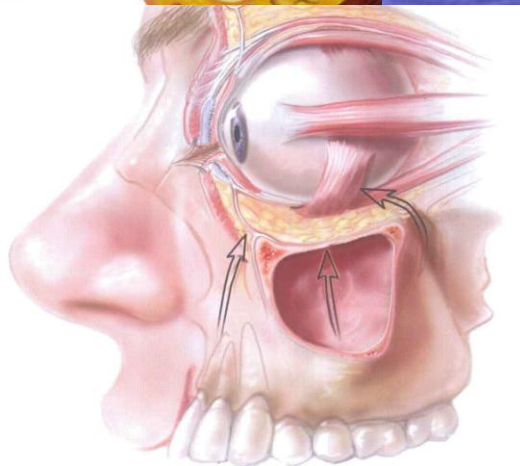
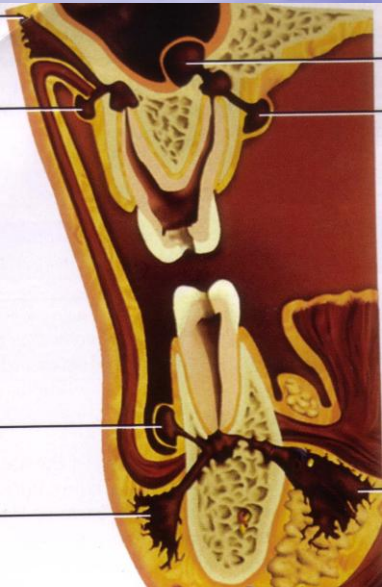
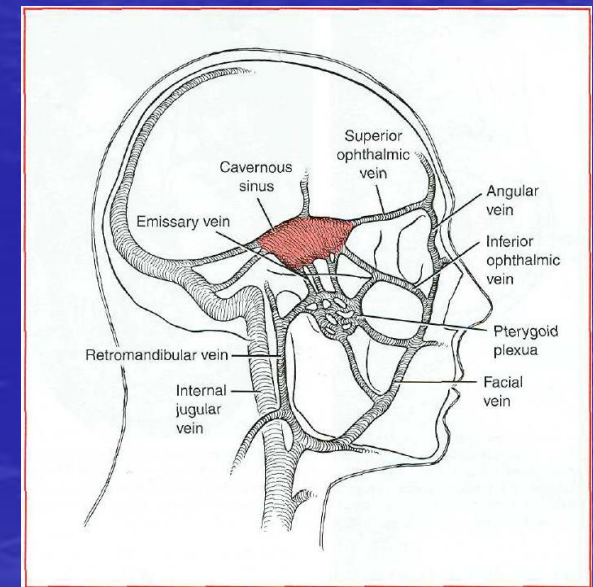
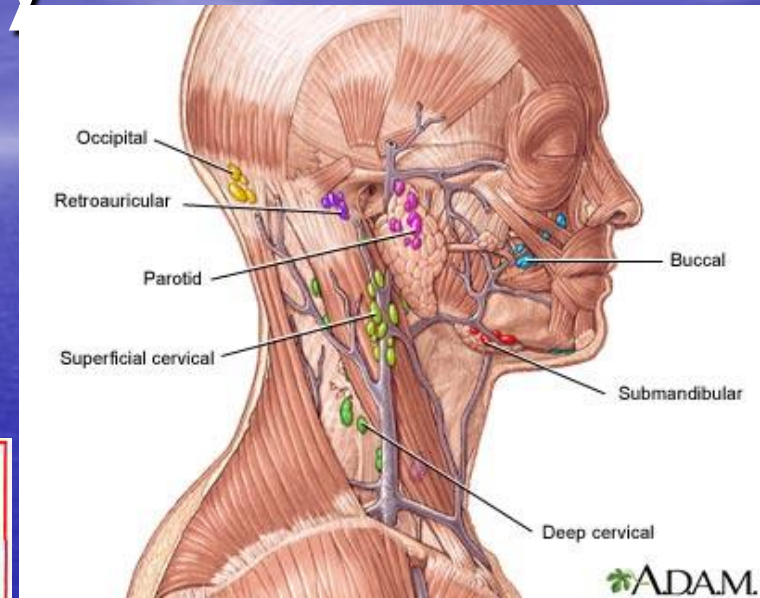
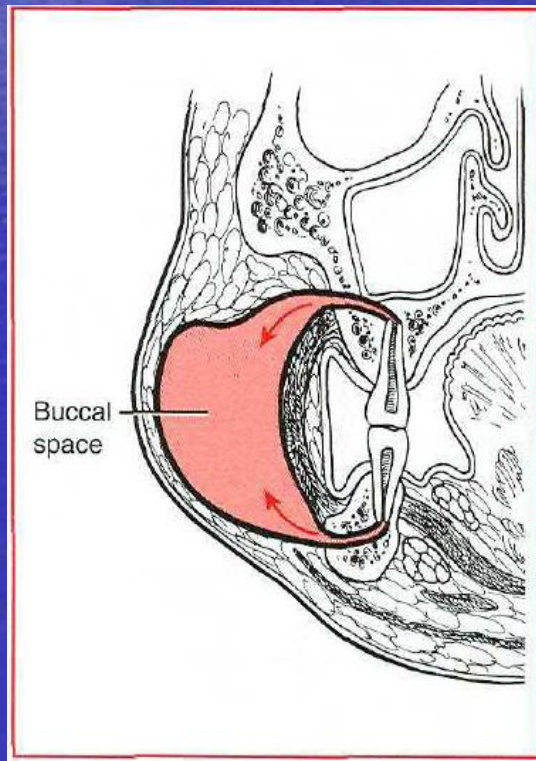
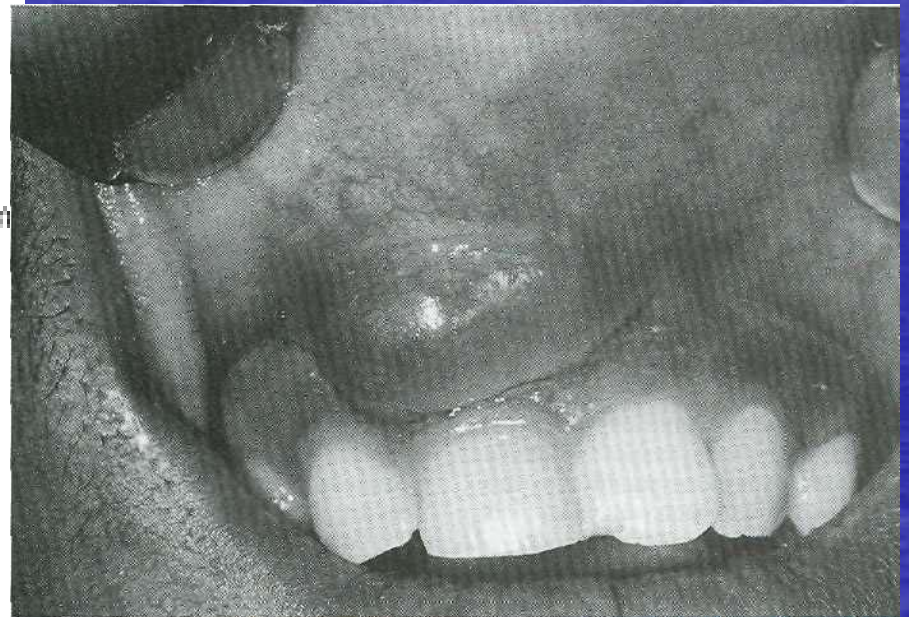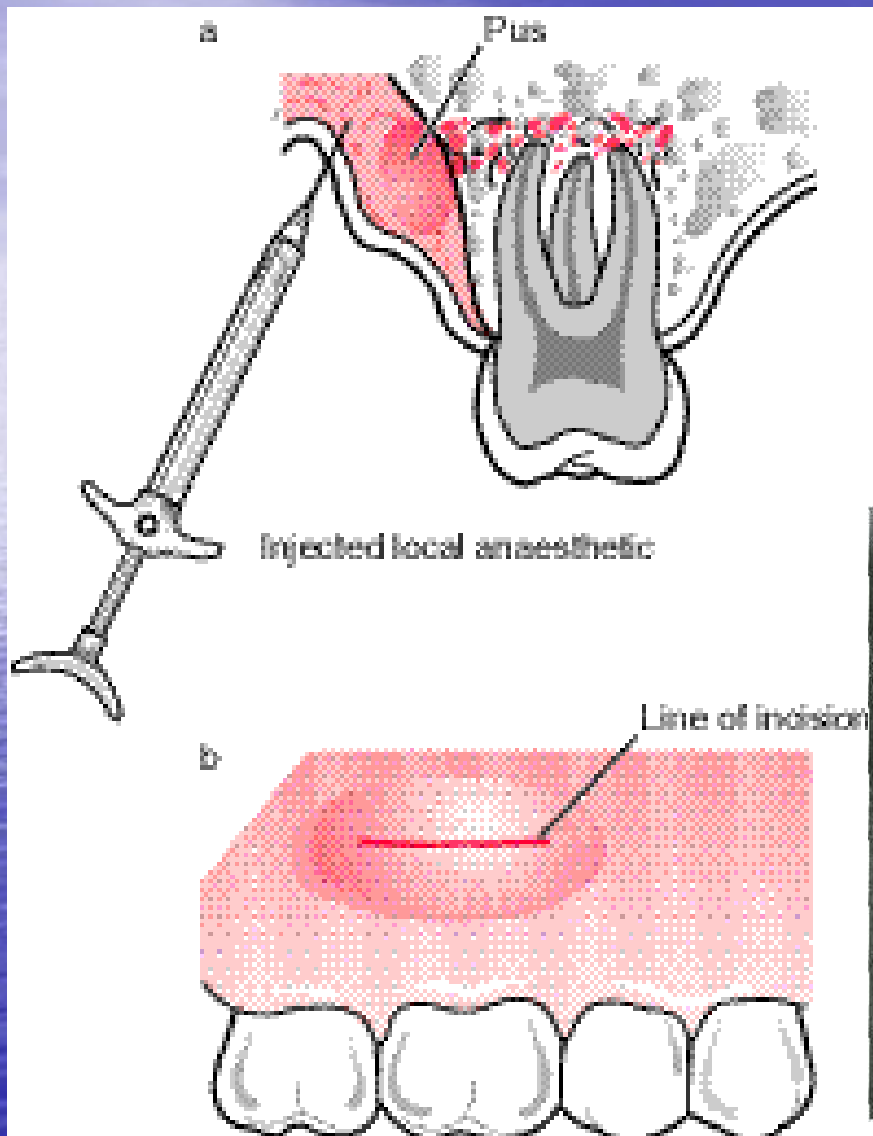

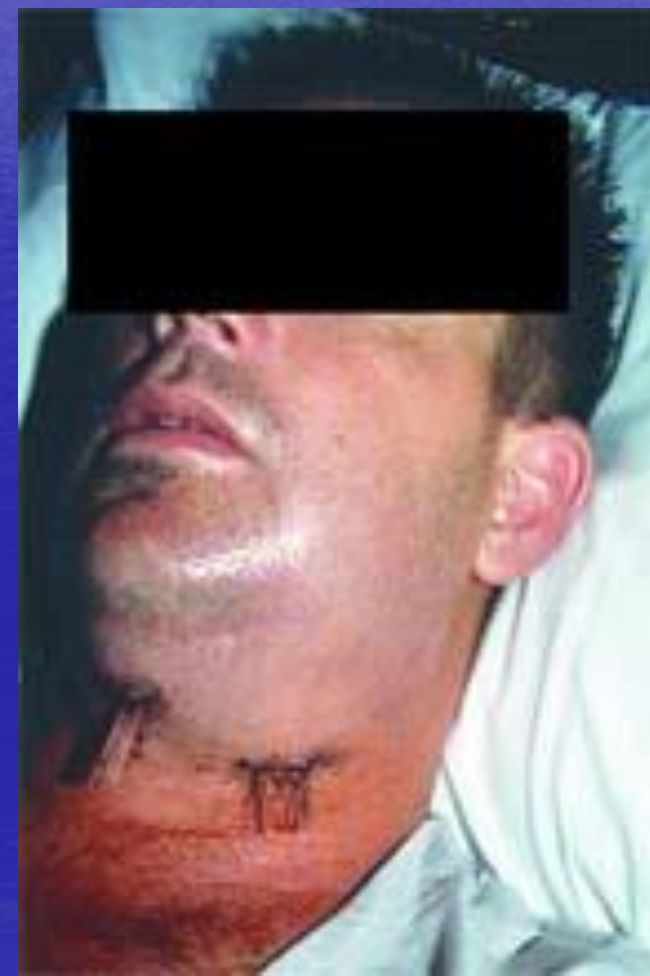
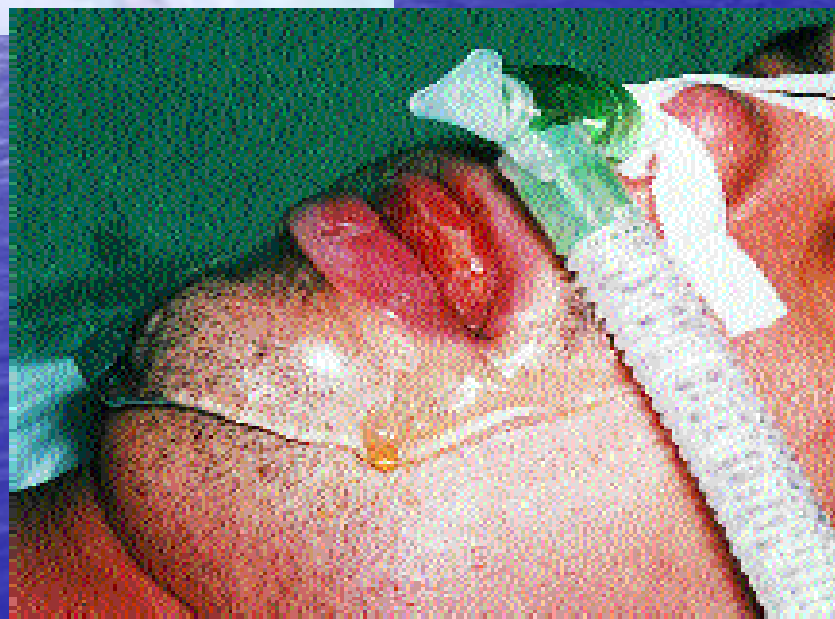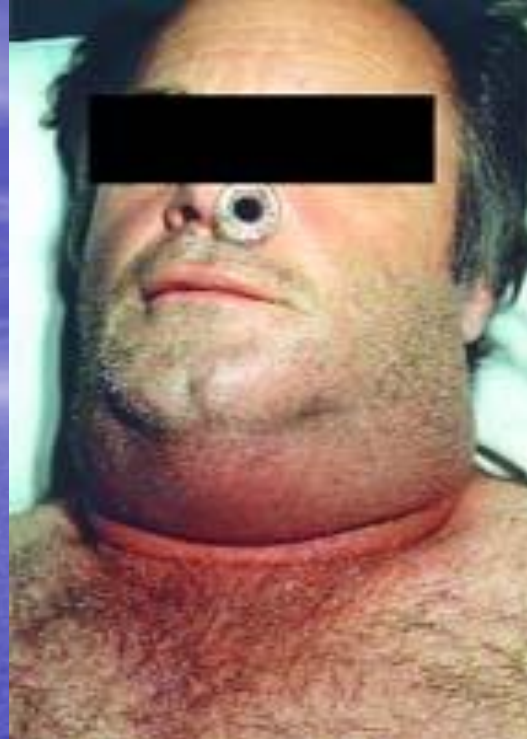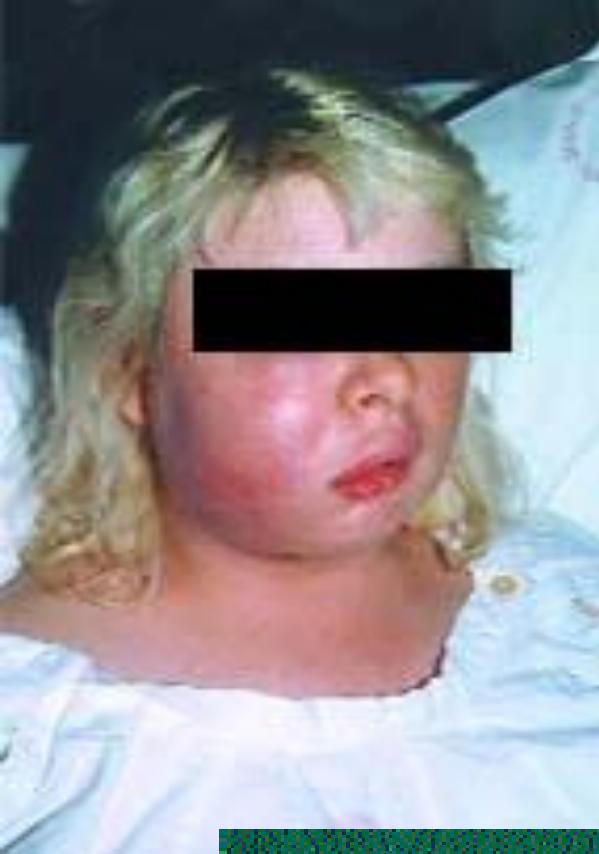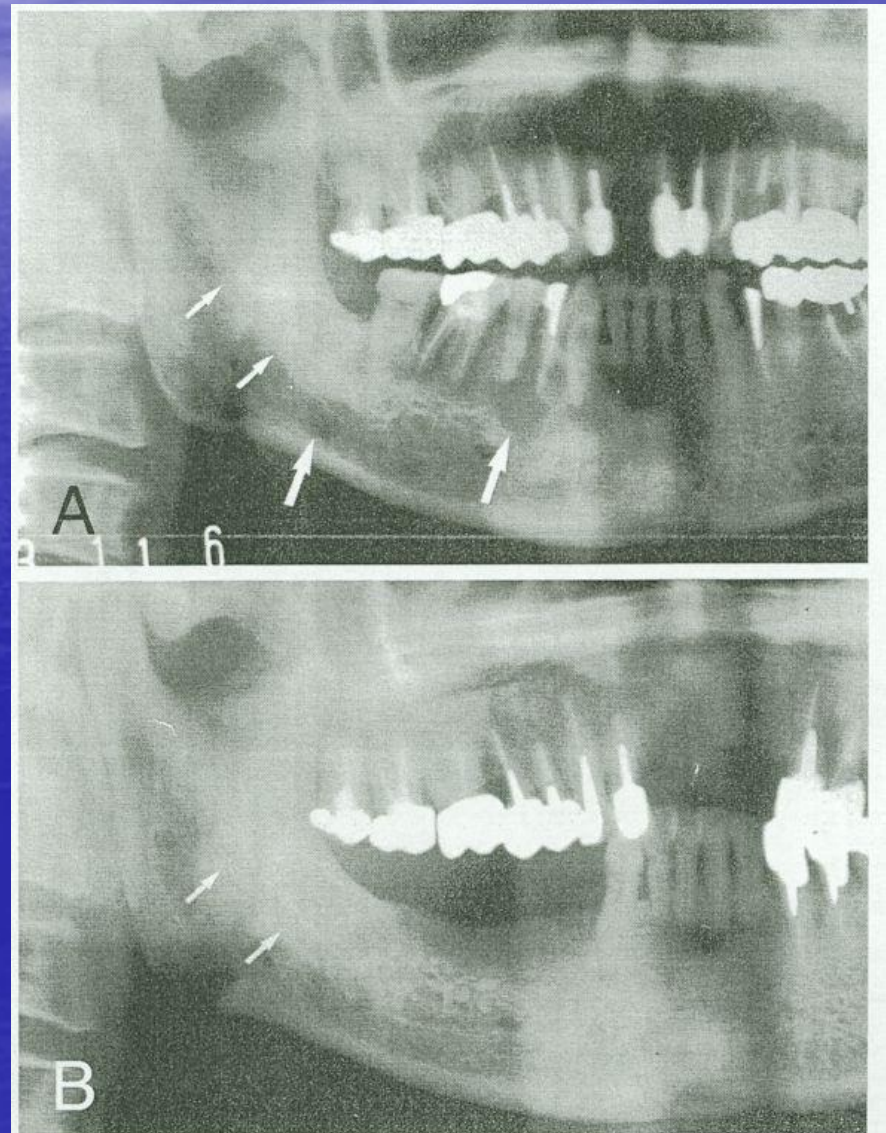
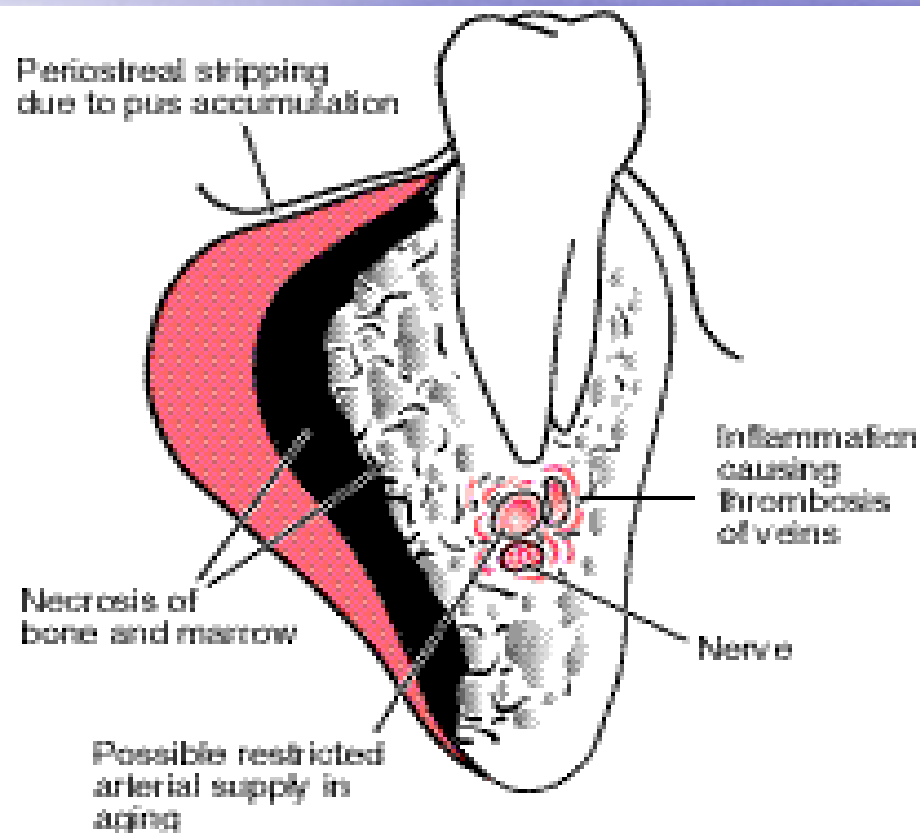
Figure 12-4
The path of spread of infection from the skin, teeth, and maxillary sinus to the orbit. Note that the orbit may become involved through the infratemporal fossa via the inferior orbital fissure.

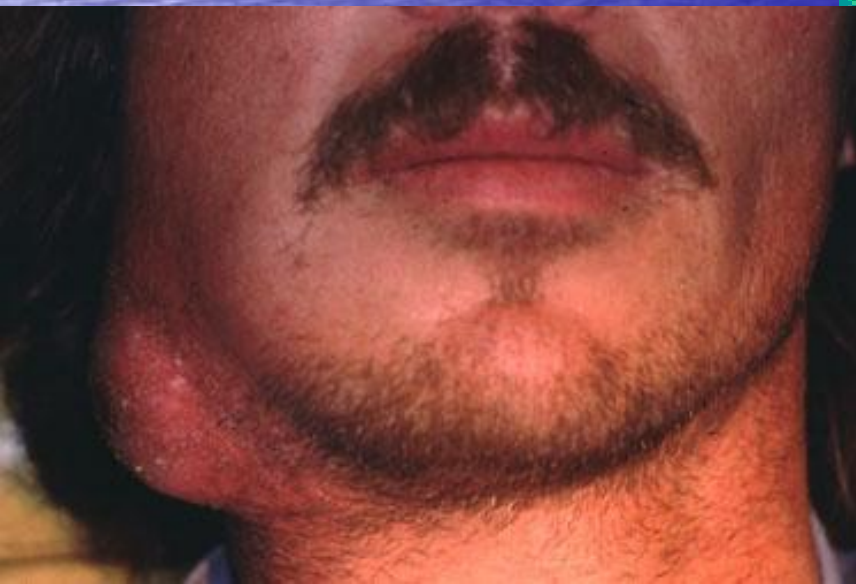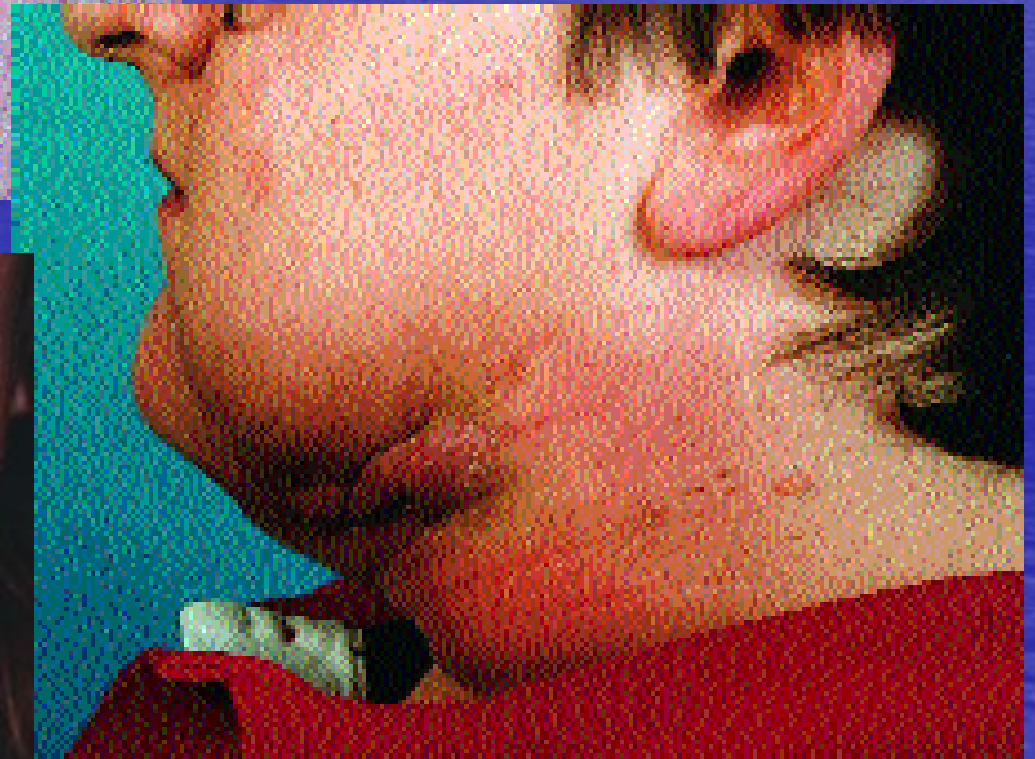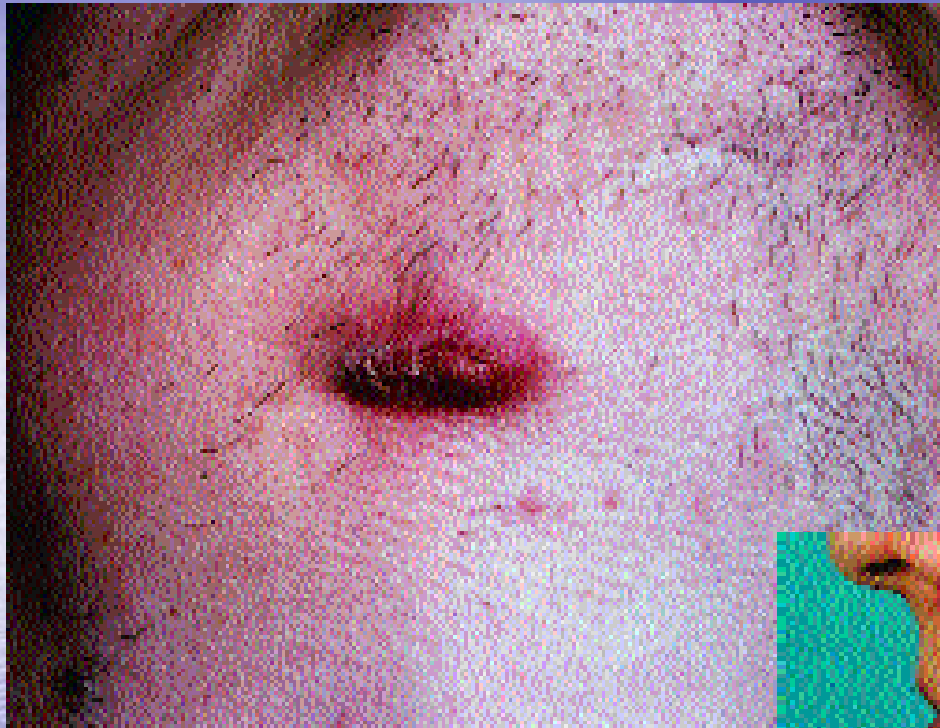




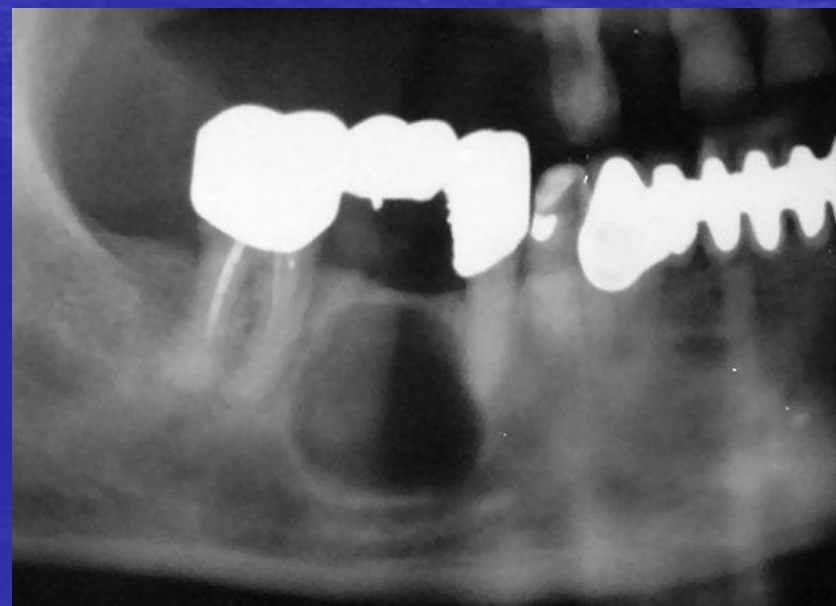


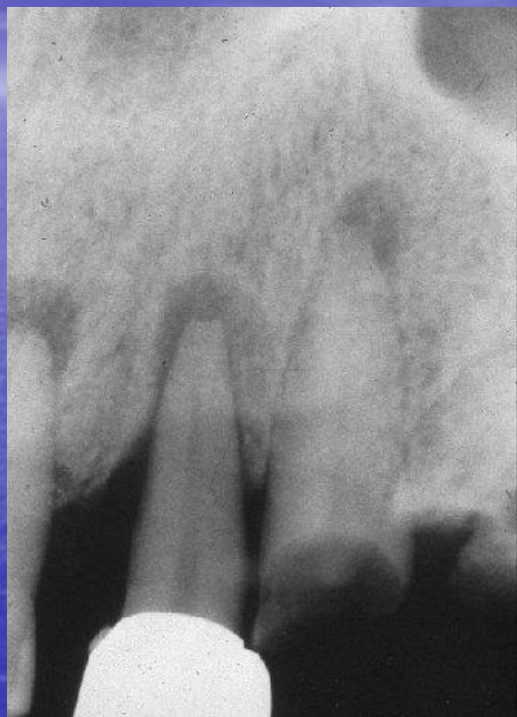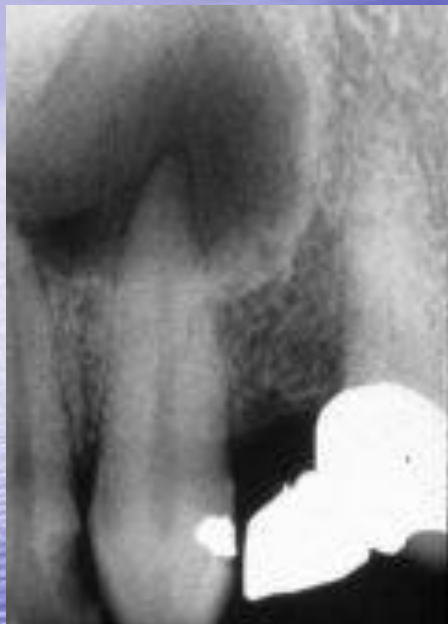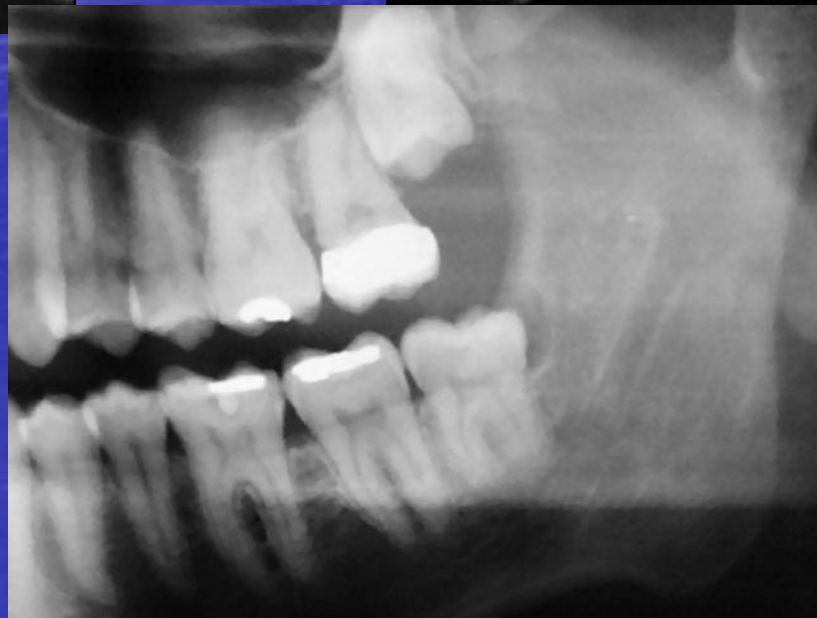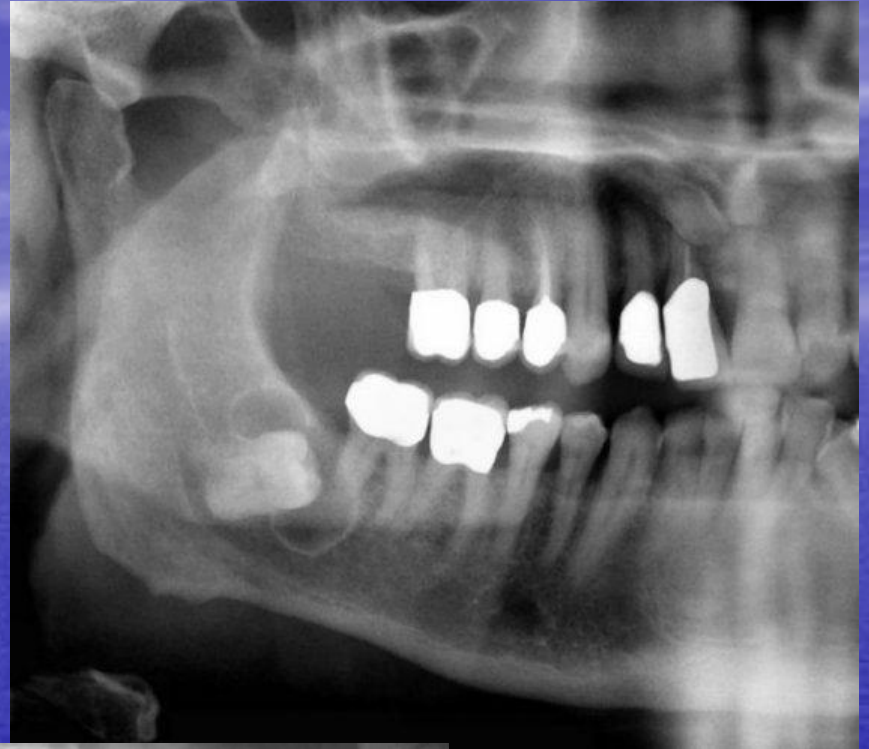
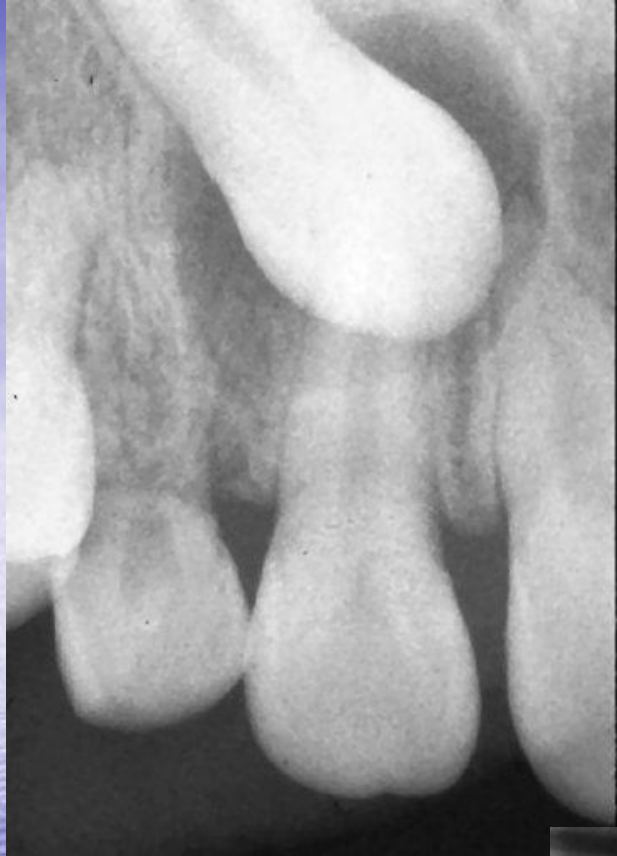Osteomyelitída



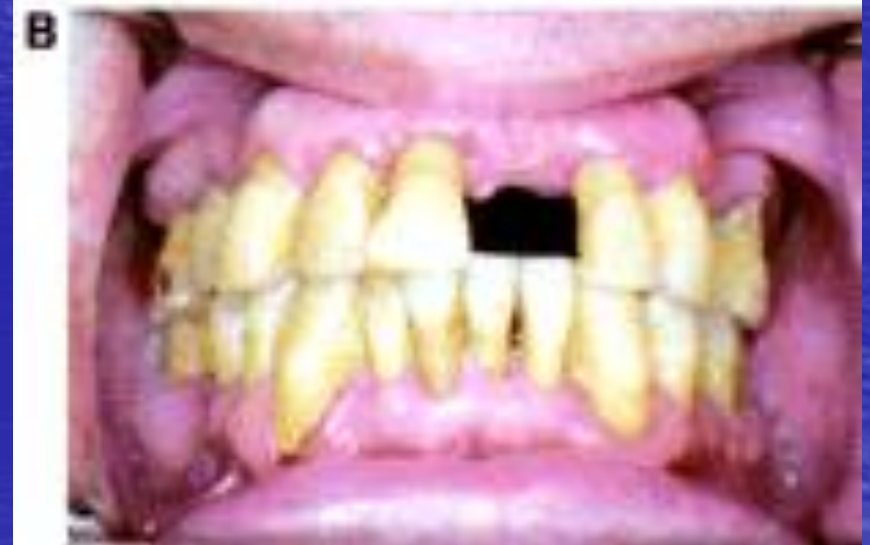
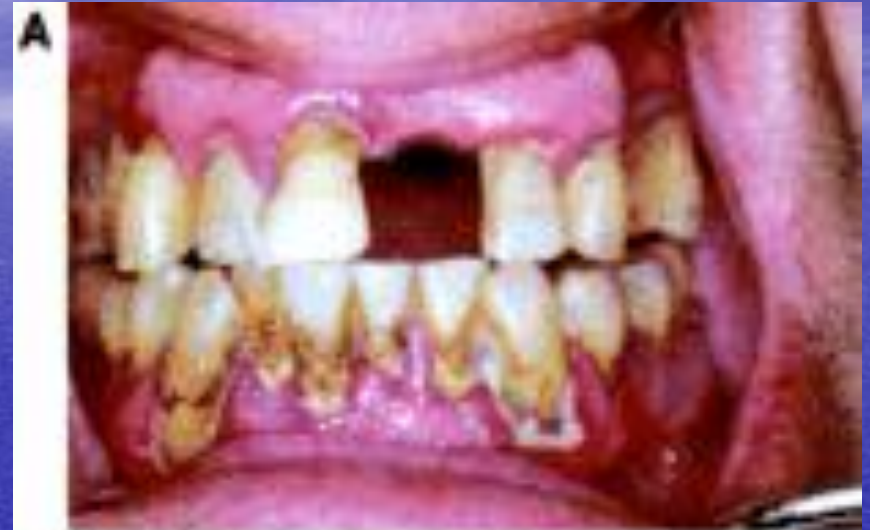
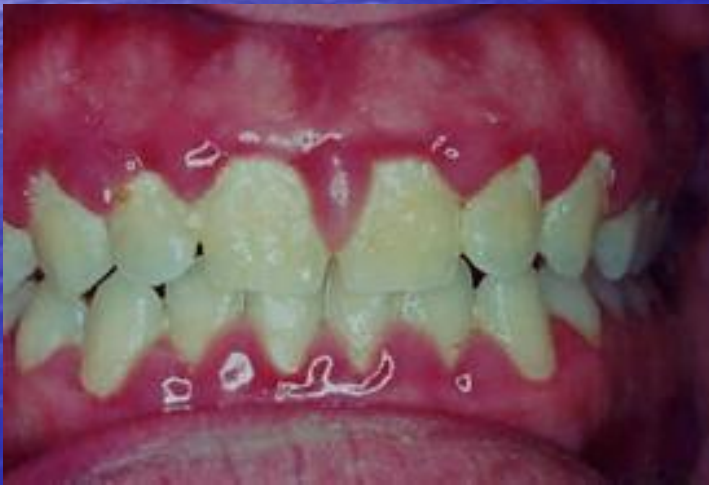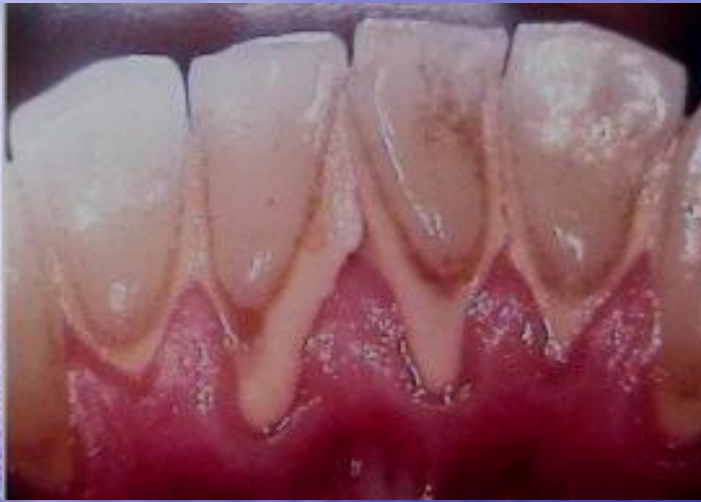Dentálna fokálna infekcia





Parodontológia



Gigivitída

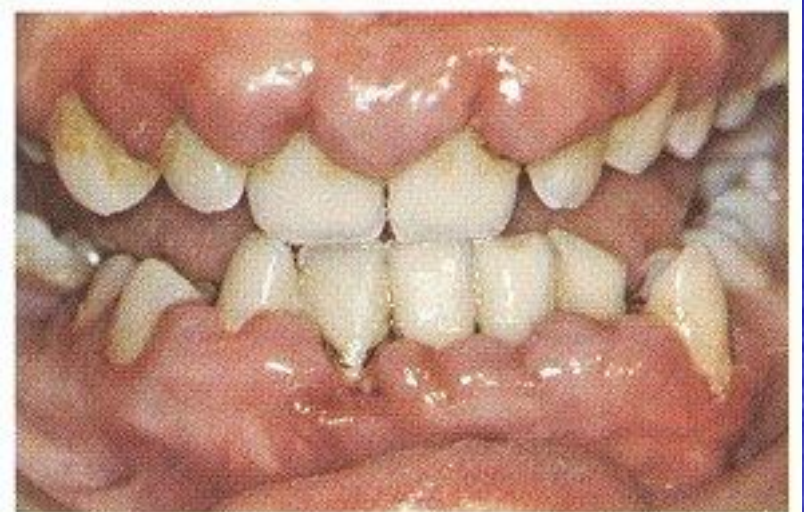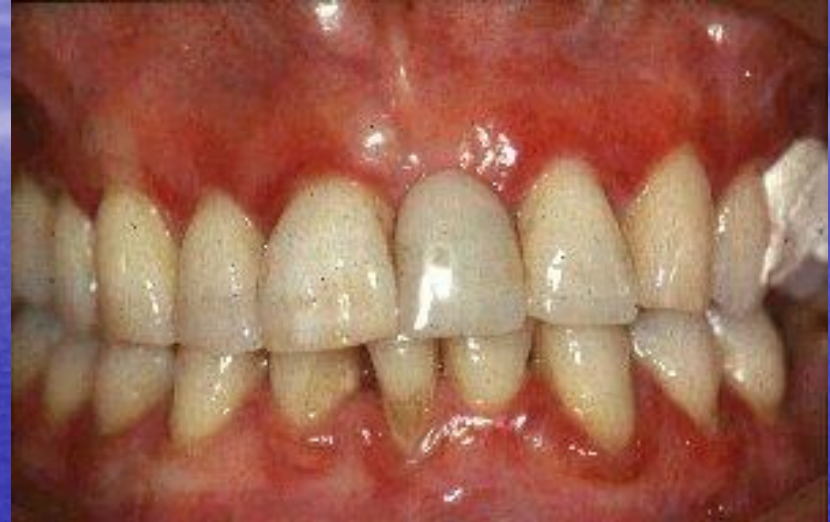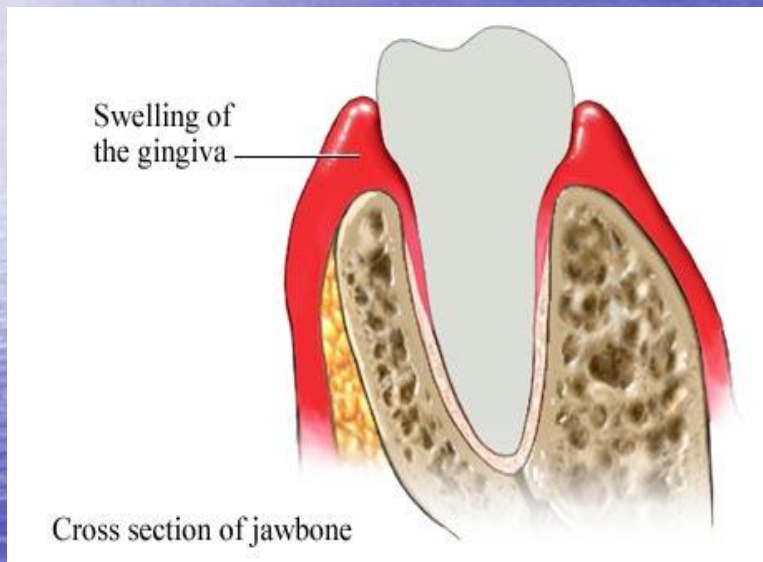
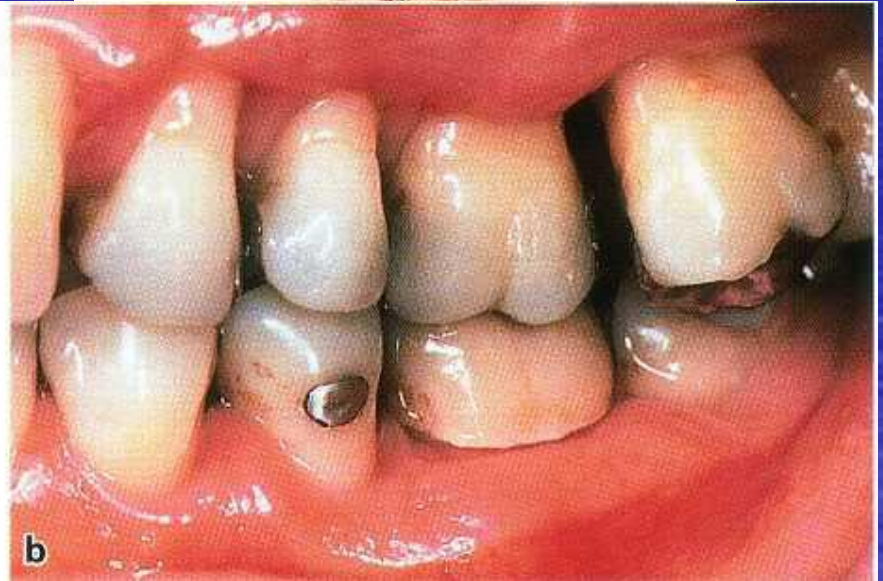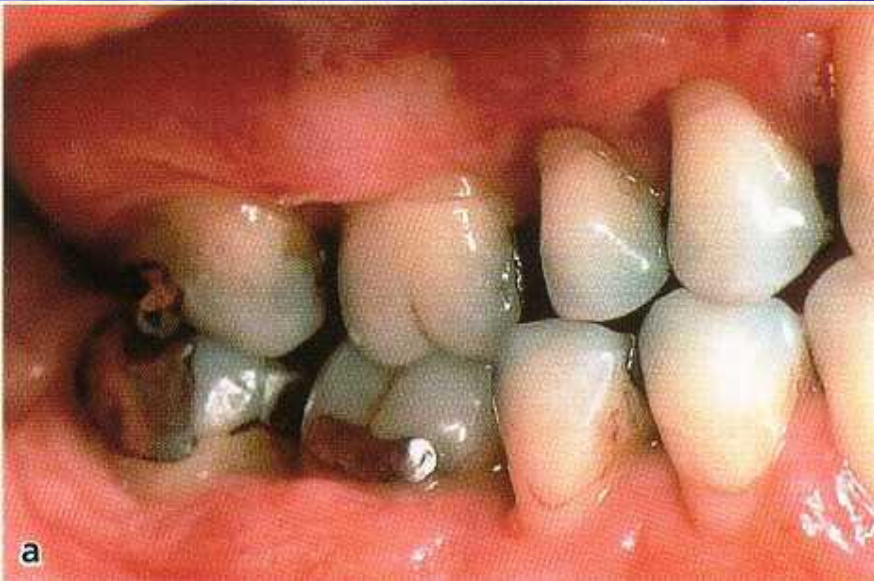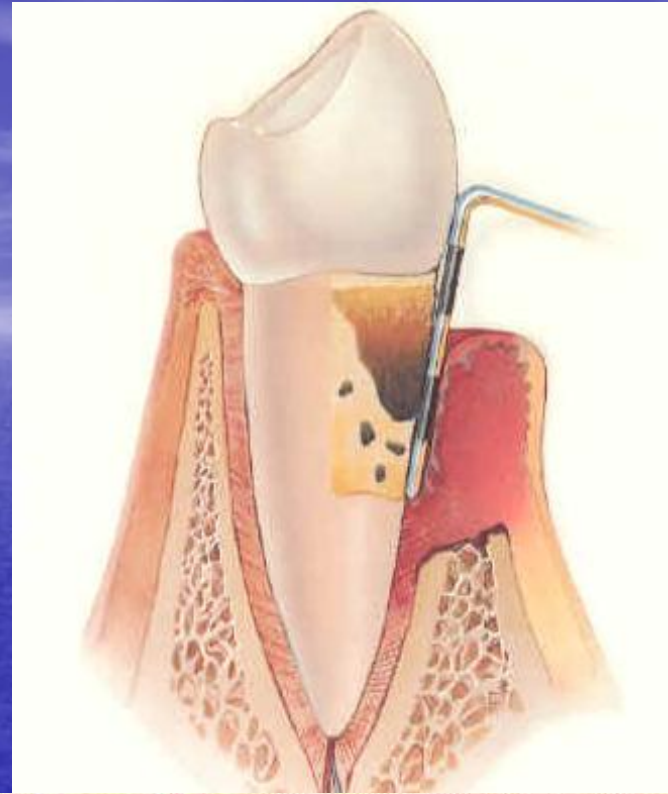
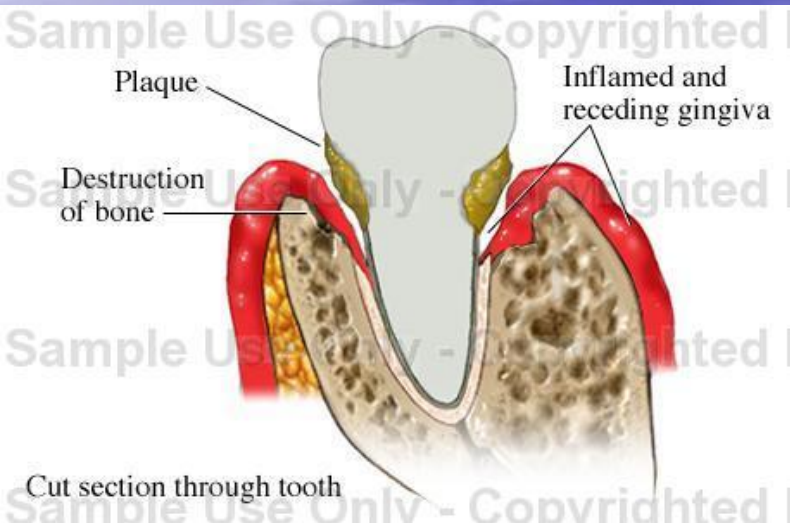


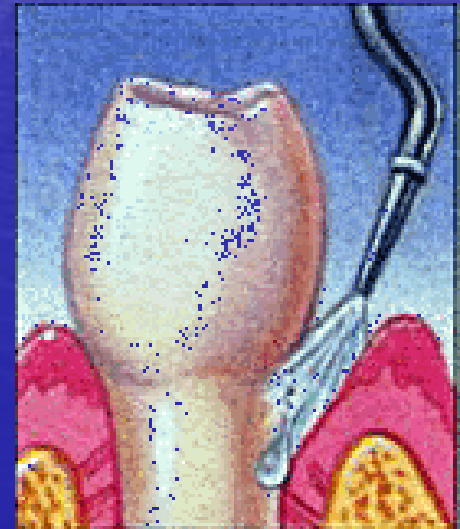
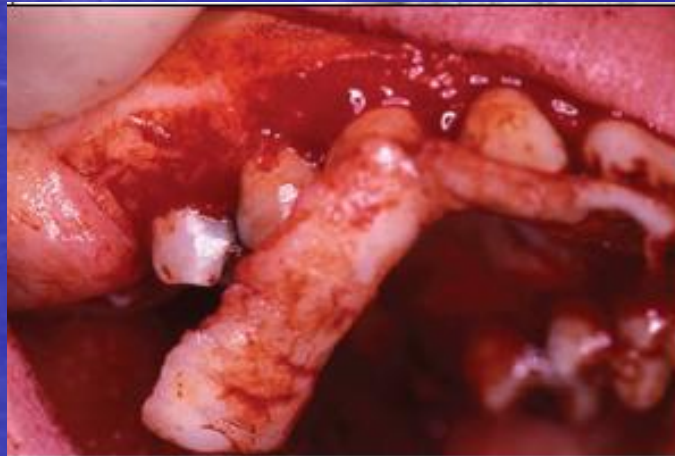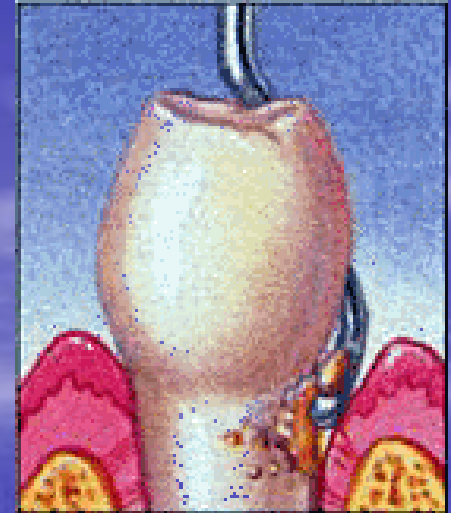
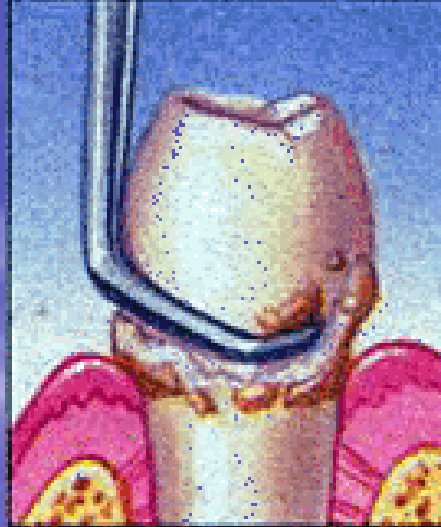
Fig. 44

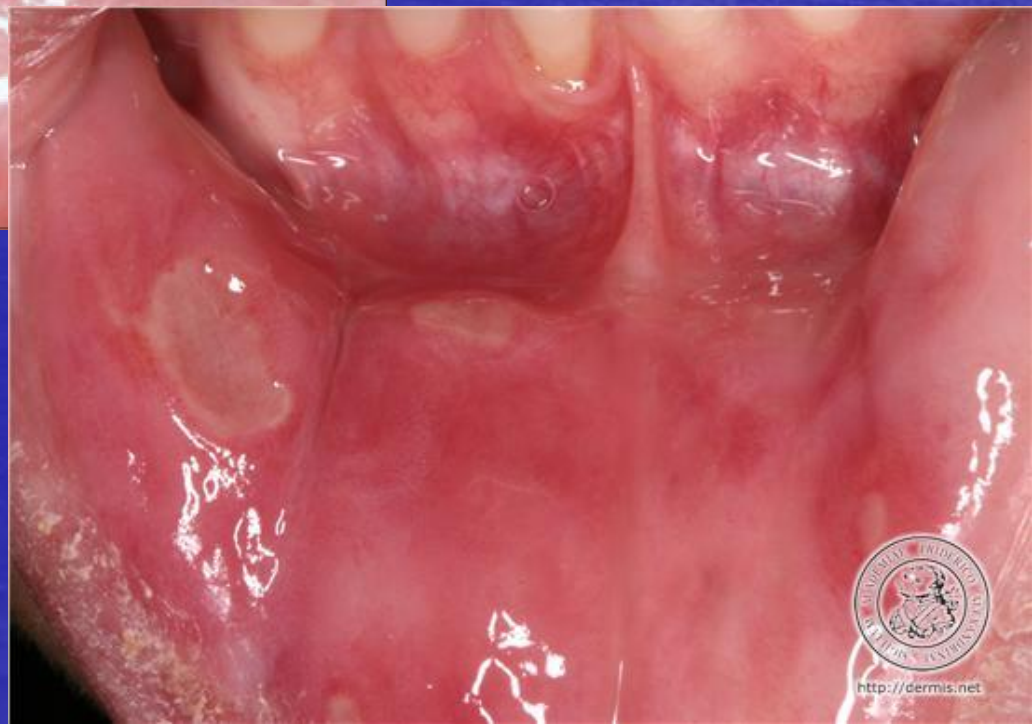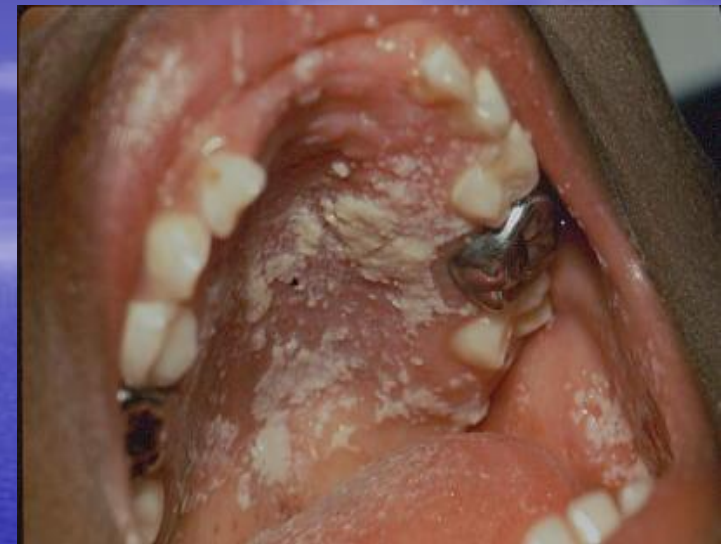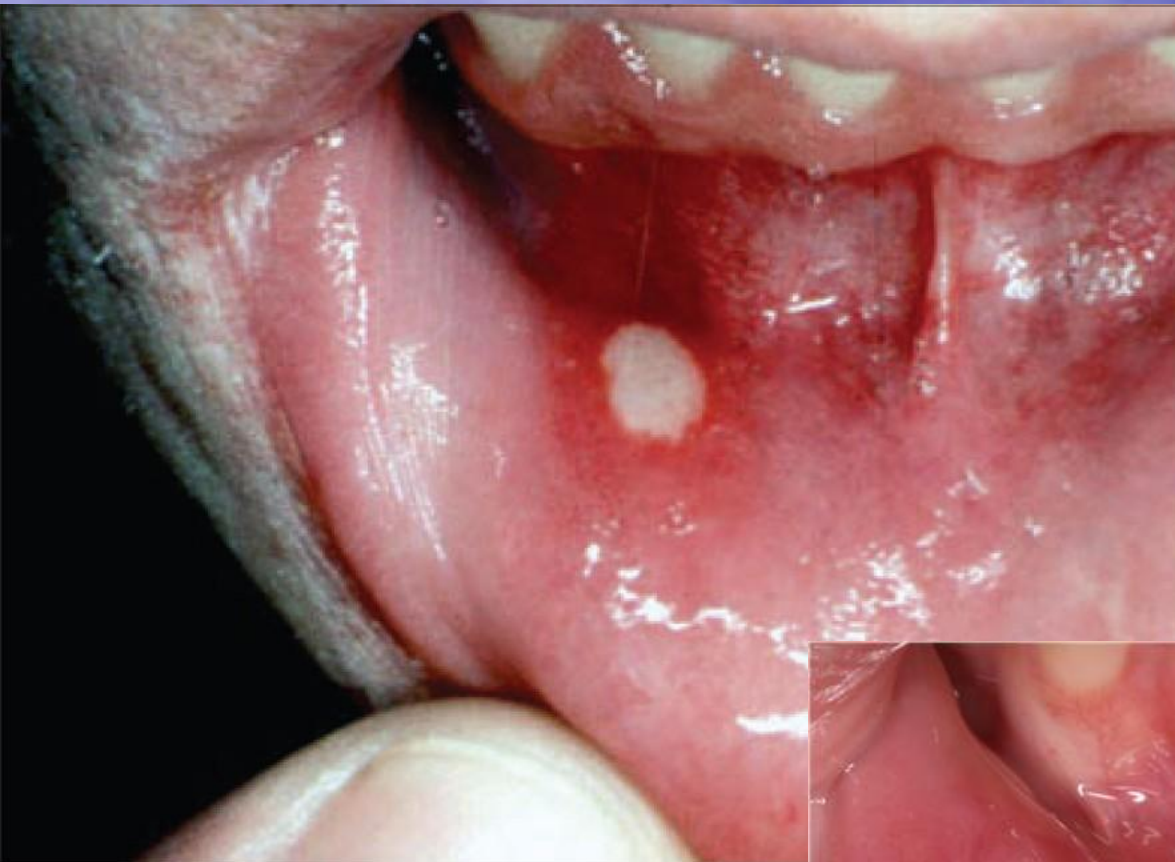Parodontitída



Terapia

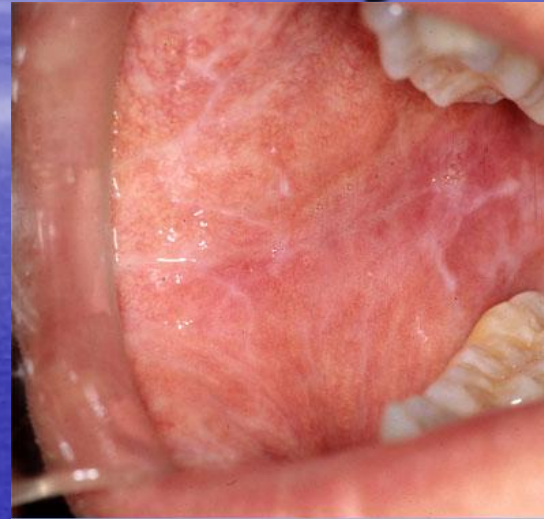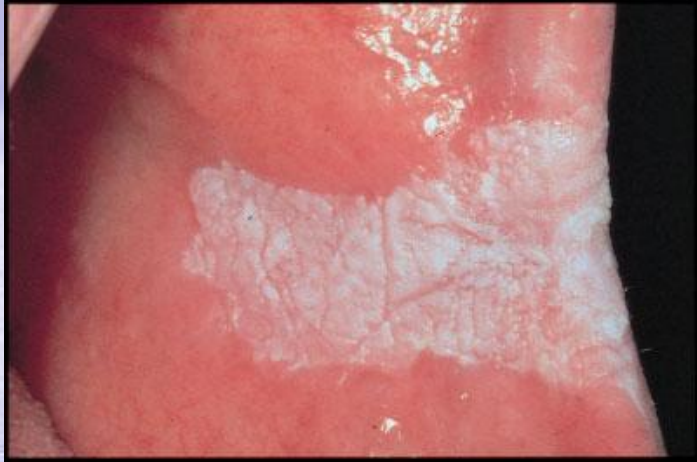- Odstránenie zubného kameňa
- Scaling, kyretáž parodontálneho vaku
- Podporná liečba chlorhexidin, dezinfekčné roztoky, ATB



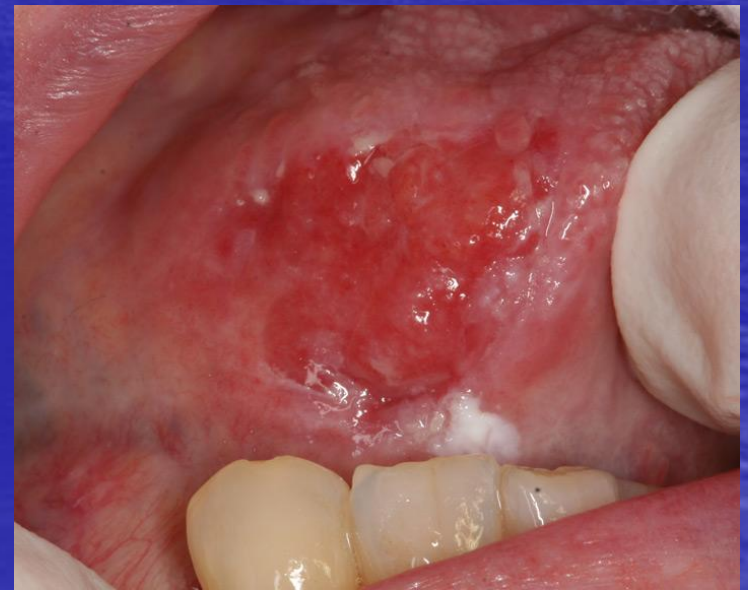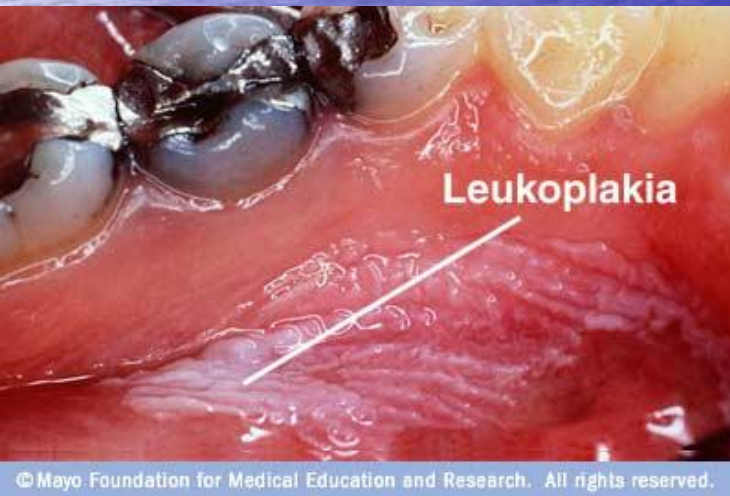


<http://dermis.net>

Ochorenia slizníc ústnej dutiny



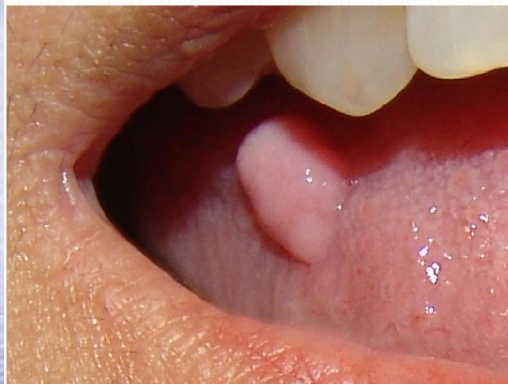© Mayo Foundation for Medical Education and Research. All rights reserved.



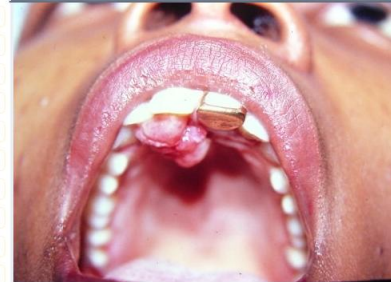© Mayo Foundation for Medical Education and Research. All rights reserved.

Onkológia oro-maxilofaciálnej oblasti

Fibroma of Tongue

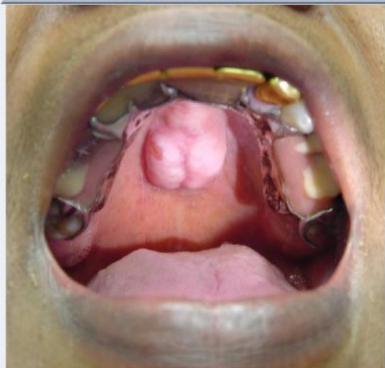

Picture of Giant Cell Epulis / Granuloma



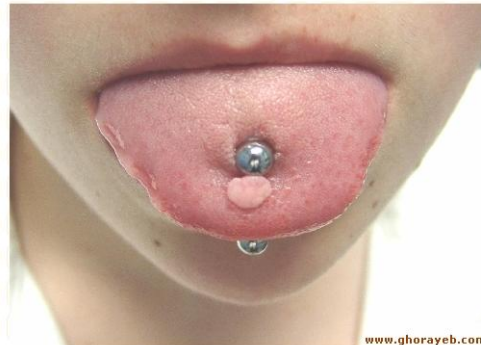The peripheral giant cell granuloma (PGCG) is an exuberant reactive response of the gum to trauma or some chronic inflammatory process. It arises from cells originating in the periodontal ligament or the periosteum. It presents as a sessile or pedunculated, highly vascular, easily bleeding exophytic mass with a purple-brown color. It is more frequent in women than in men, and is more often found on the mandibular gingiva rather than the maxillary gingiva. Radiographically there is bone erosion.

Pictures of Torus Palatinus & Torus Mandibularis



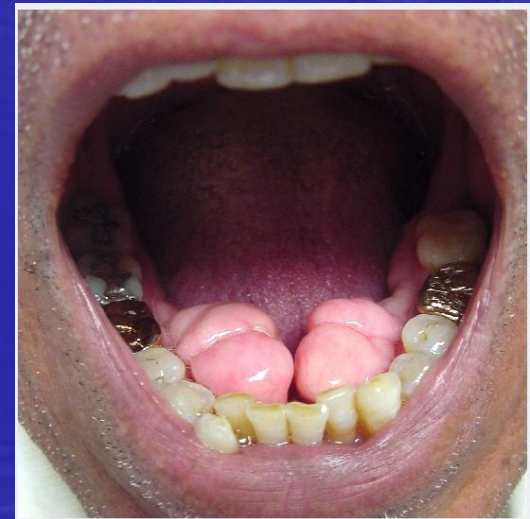Torus palatinus is a common developmental exostosis or outgrowth of the bone of

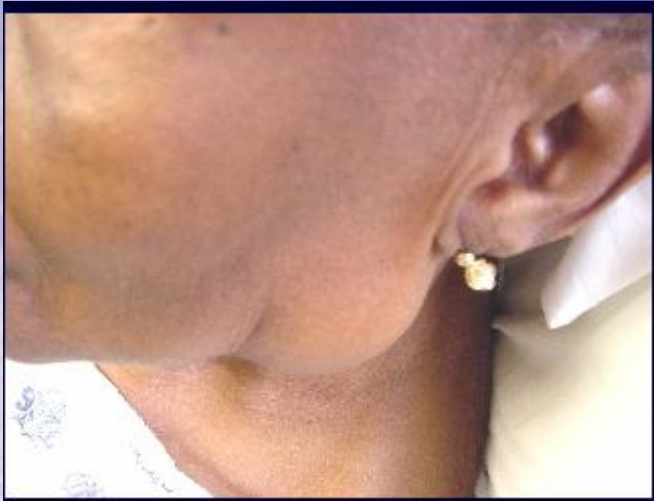Picture of Pyogenic Granuloma of the Tongue



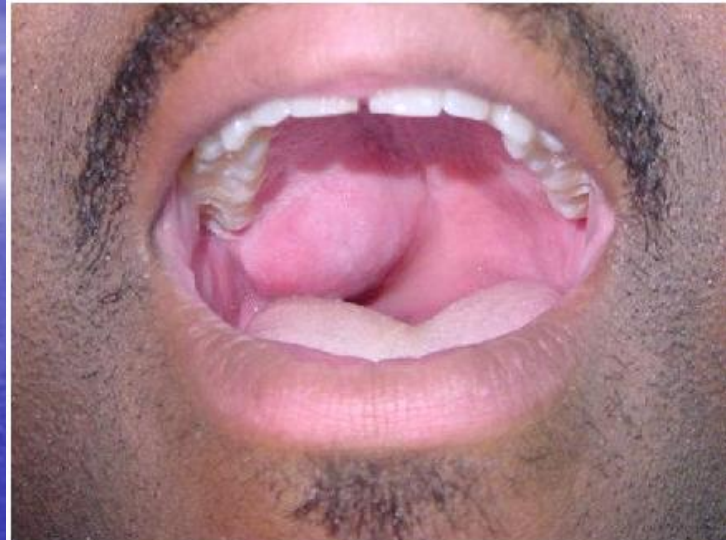www.ghorayeb.com

Pyogenic granuloma of the tongue, a complication of tongue piercing.





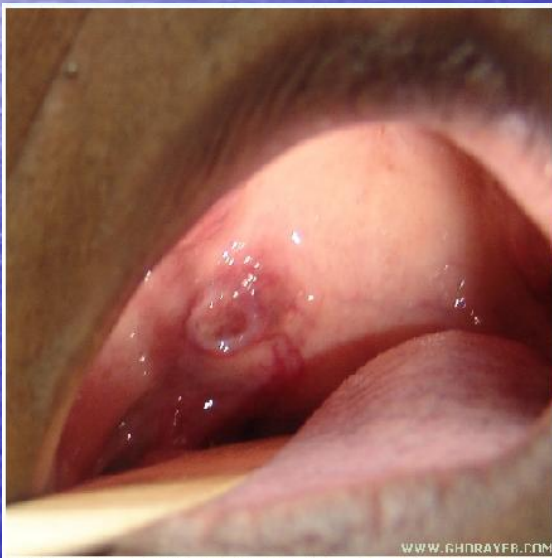Pleomorphic Adenoma of the Palate



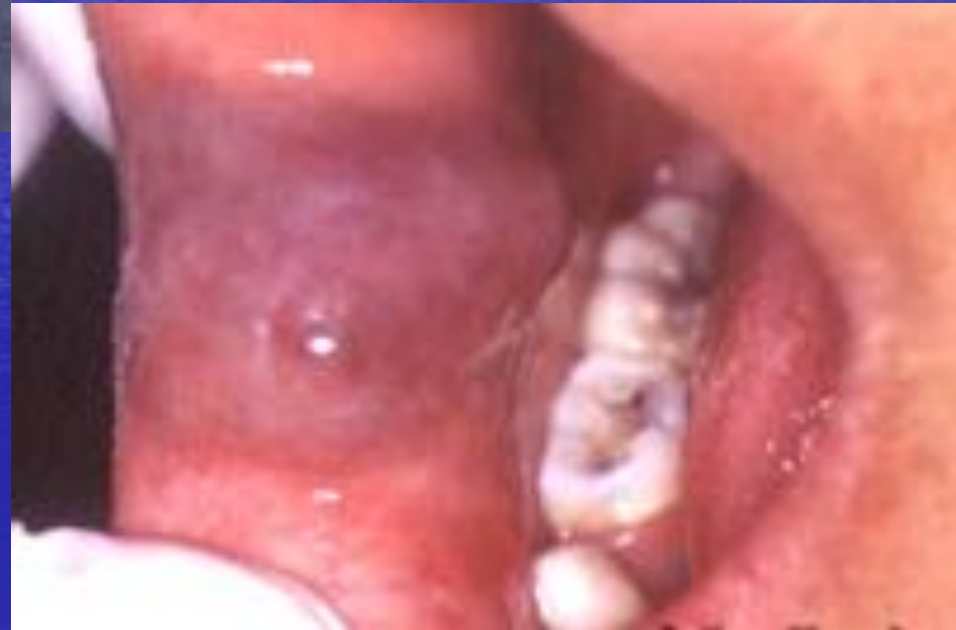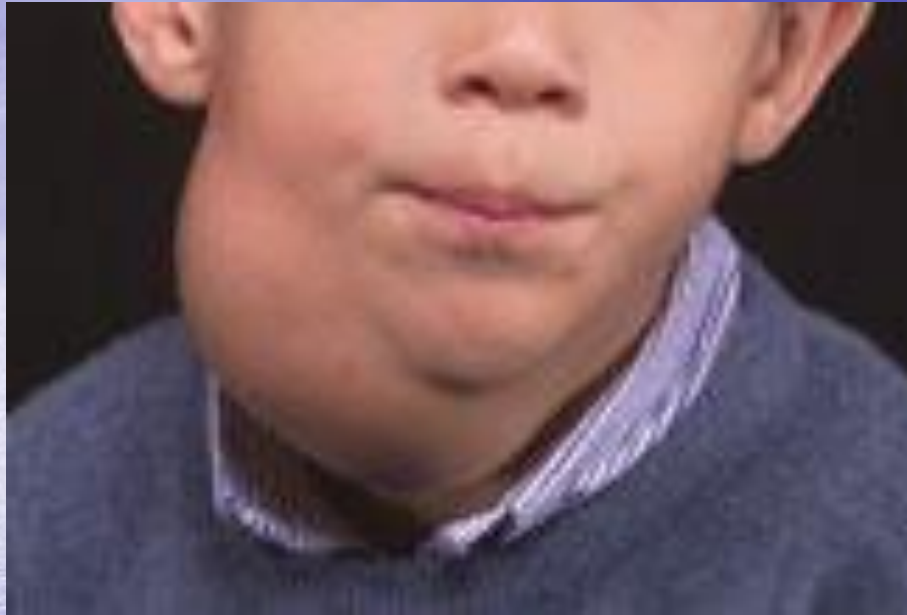PICTURE OF PLEOMORPHIC ADENOMA OF THE HARD PALATE

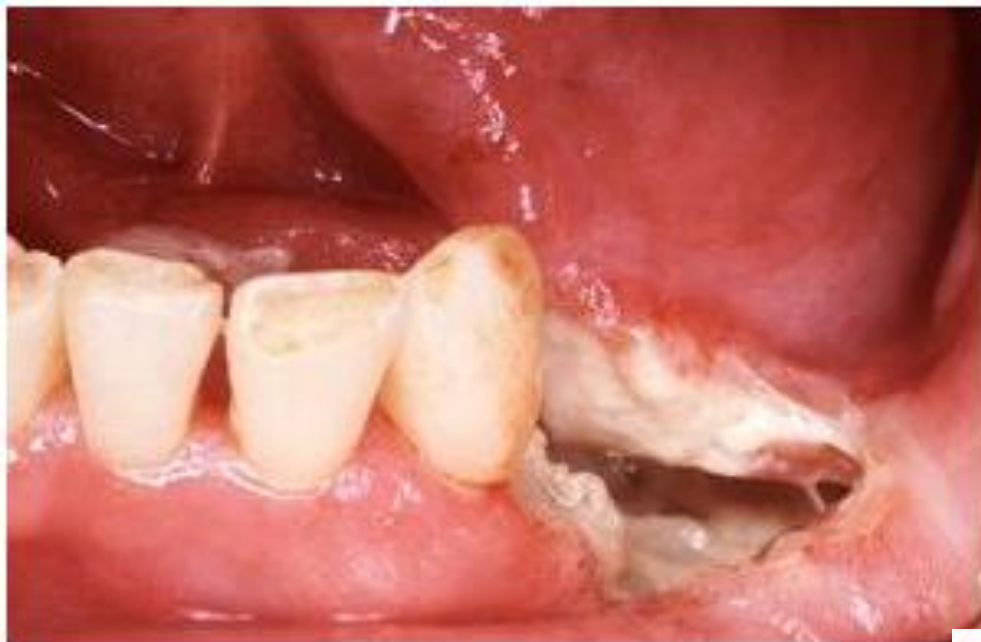Pleomorphic adenoma (benign mixed tumor) of the minor salivary glands of the palate.

Tumours arising in the **minor salivary glands** account for 22% of all salivary gland neoplasms. The majority are malignant; only 18% are benign.

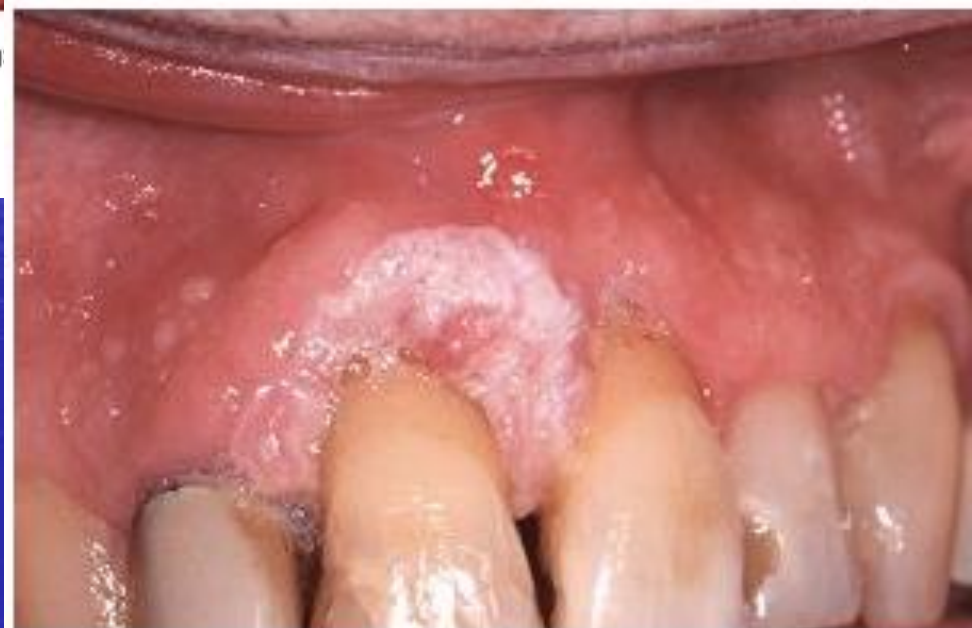


PICTURE OF PLEOMORPHIC ADENOMA OF THE SOFT PALATE

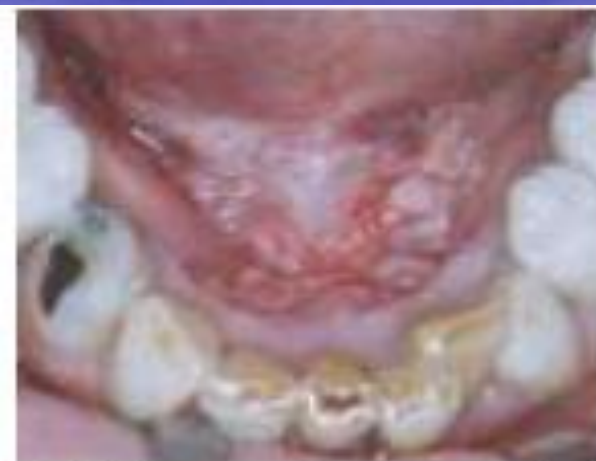
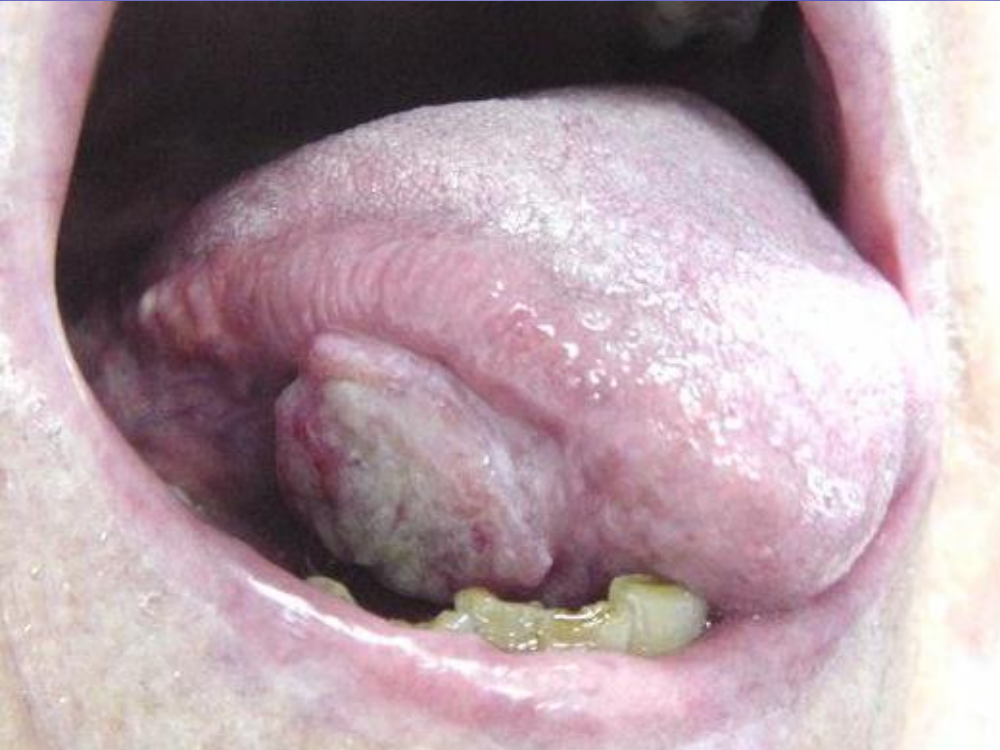


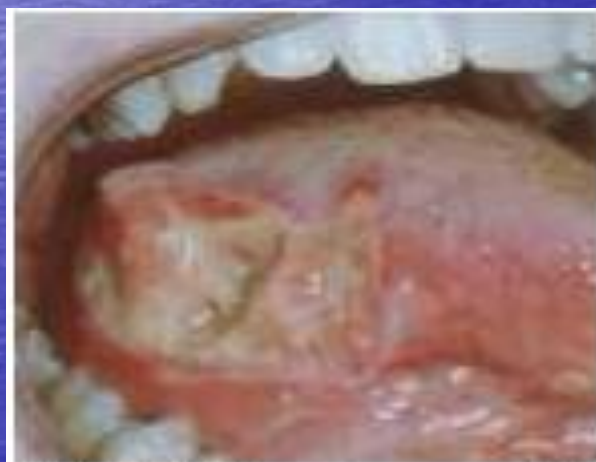Squamous cell carcinoma of the lower gingiva. Presenting a deeply ulcerative lesion, in a 65 year old female patient.



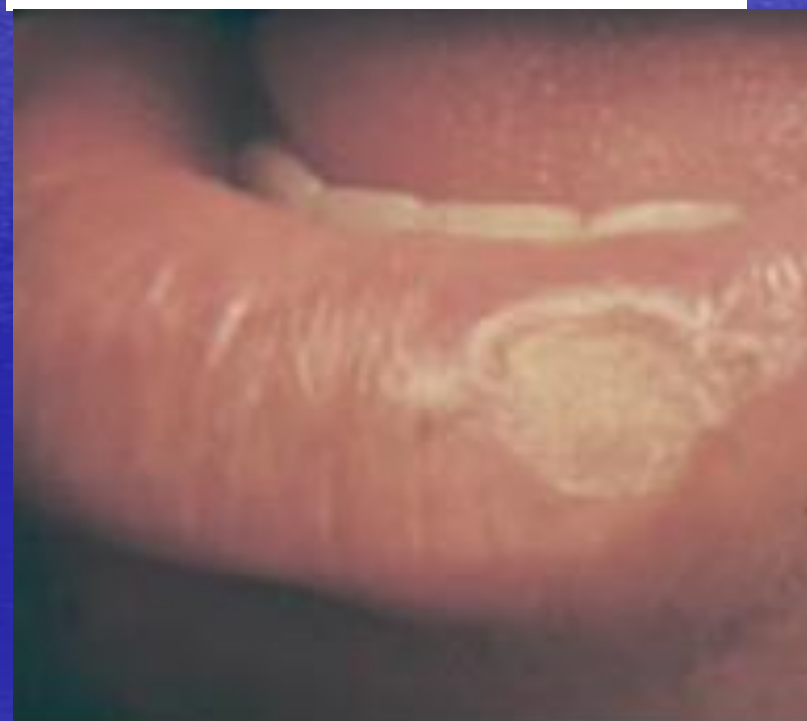A squamous cell carcinoma presenting as a verrucous keratotic lesion of the marginal gingiva, in a 54 year old male patient.



PECA anteriorer mouth soil T4

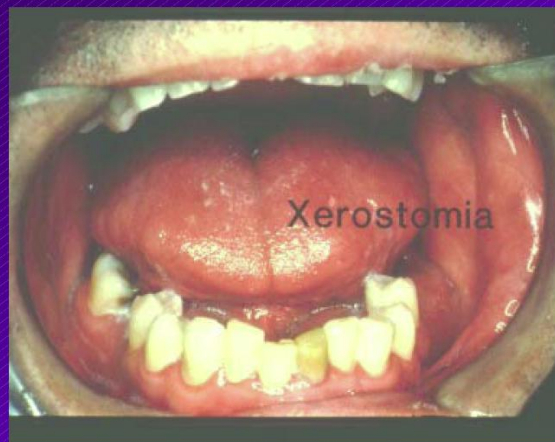
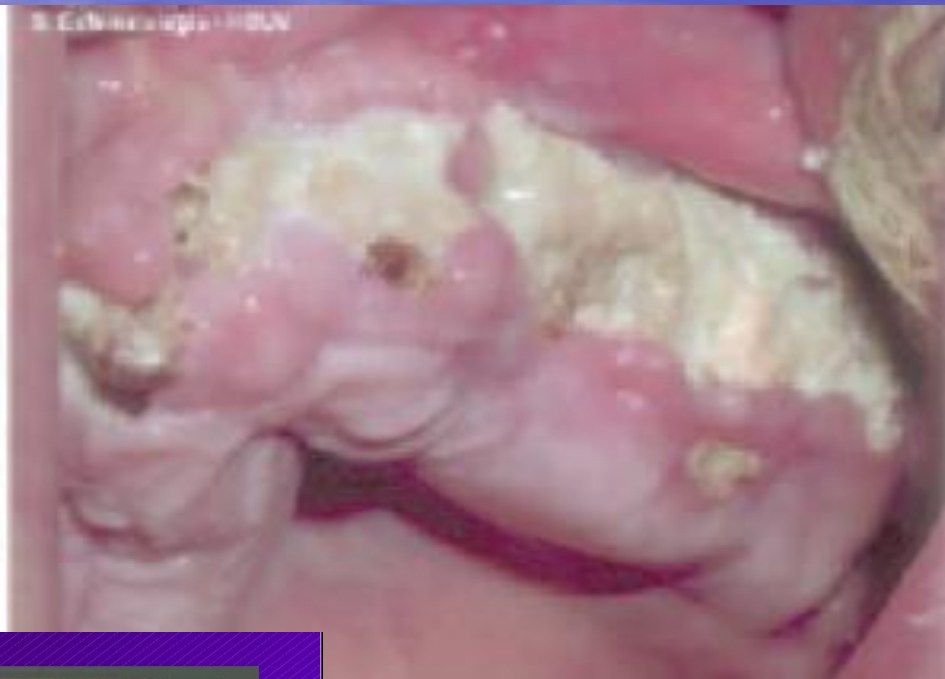
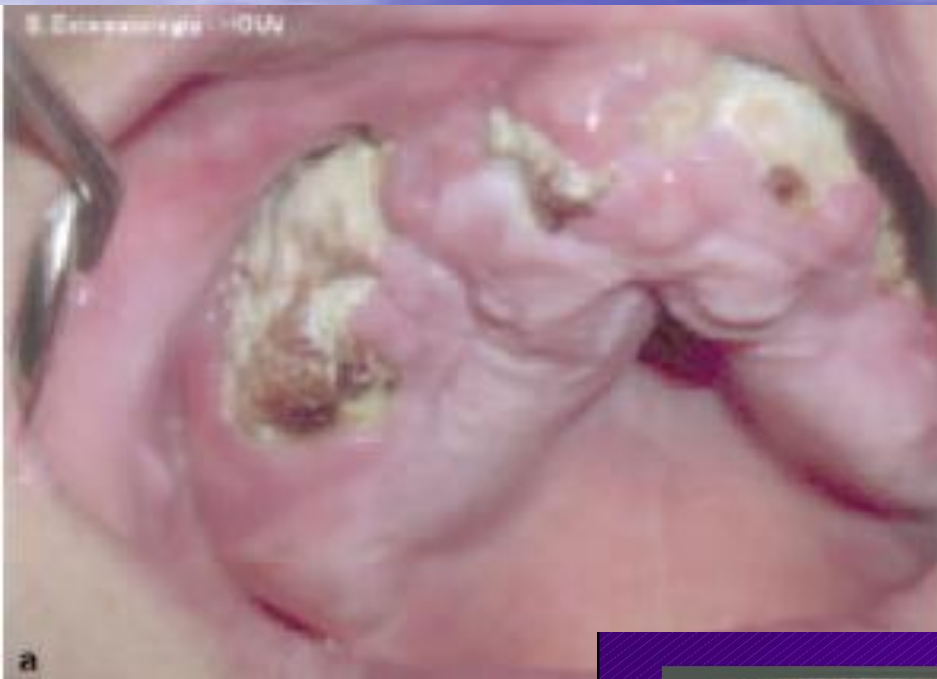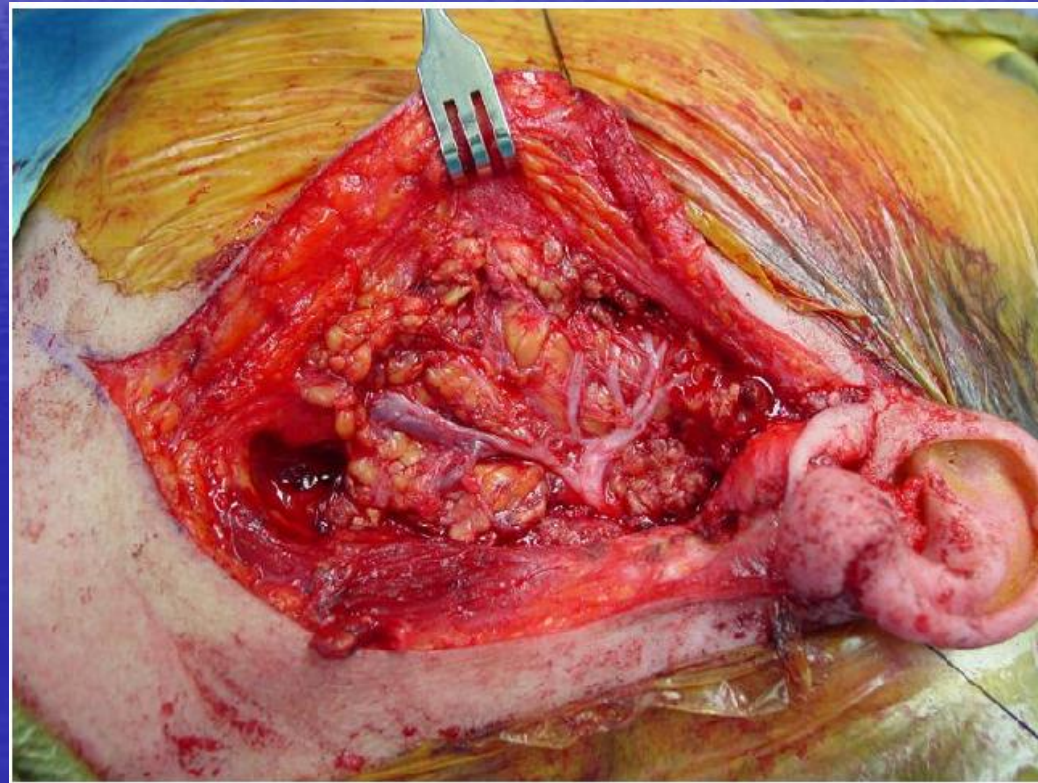
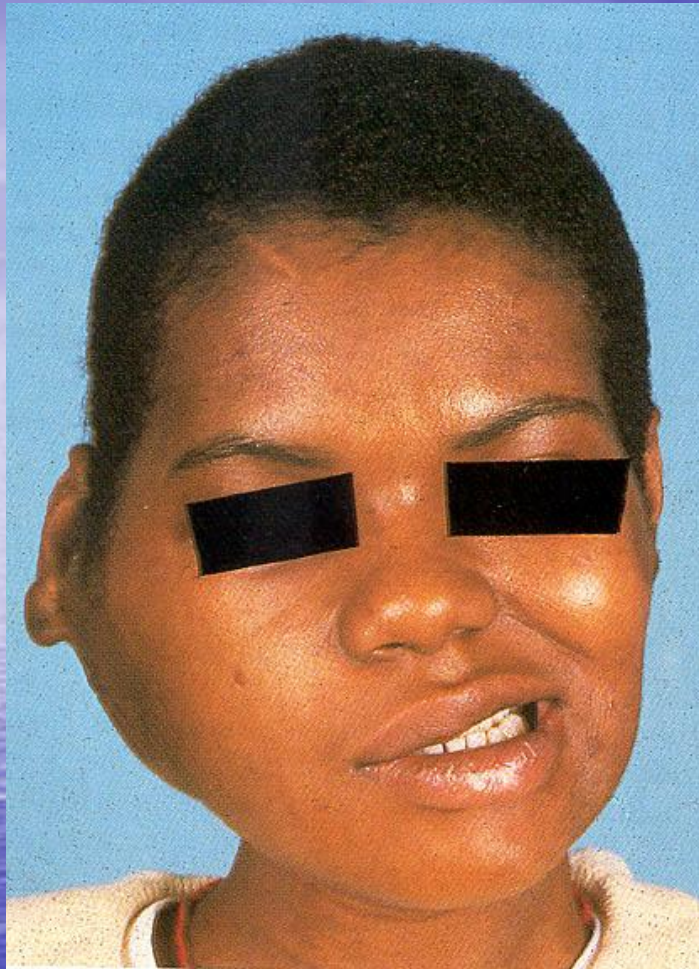PECA Edge of tongue T4

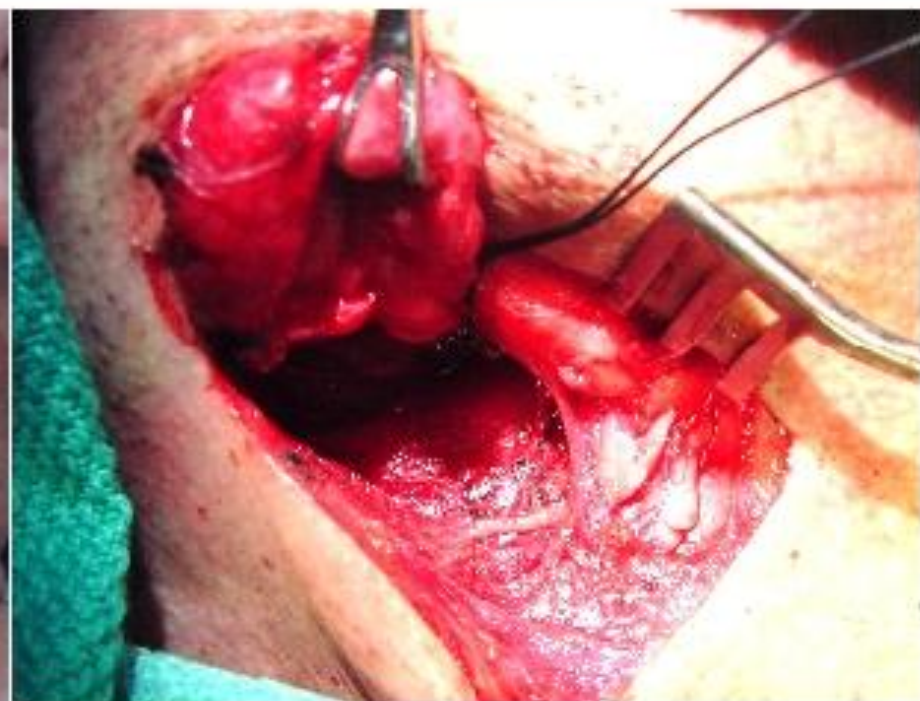
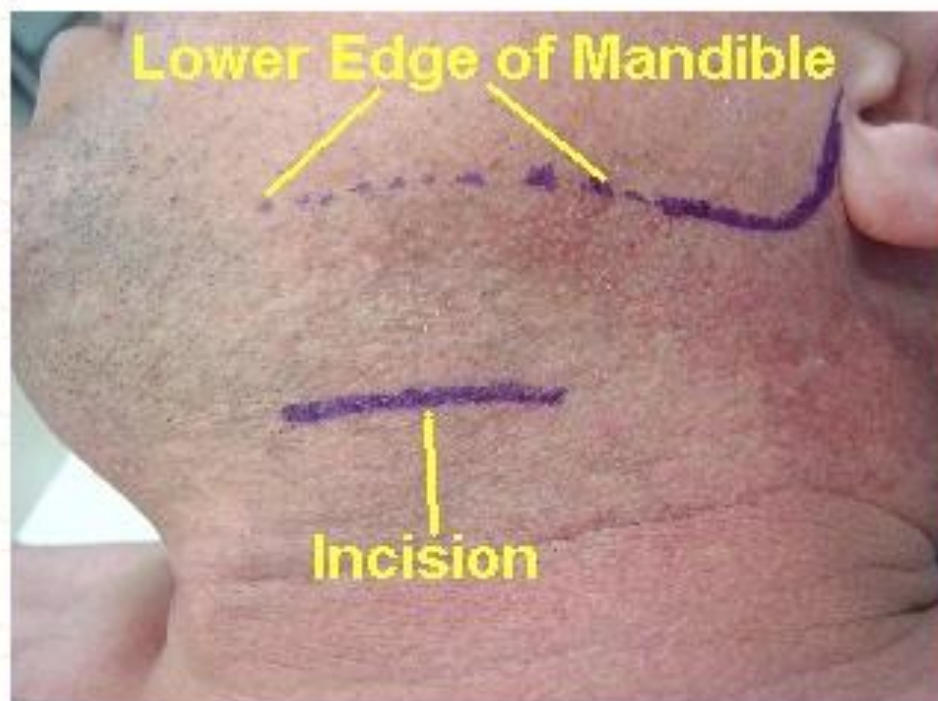
Oral cancer—lip

Komplikácie onkologickej liečby

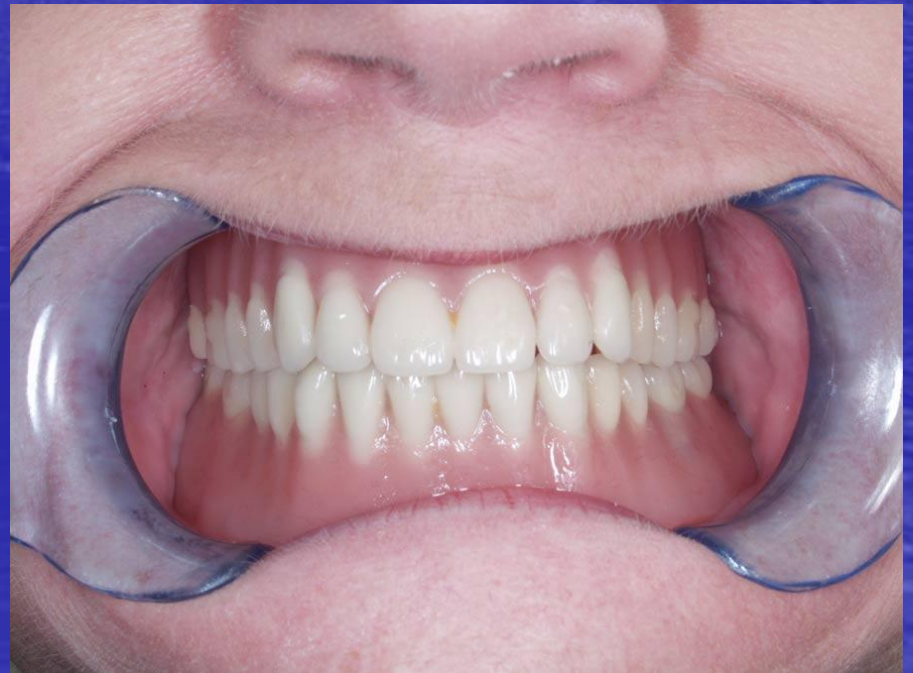
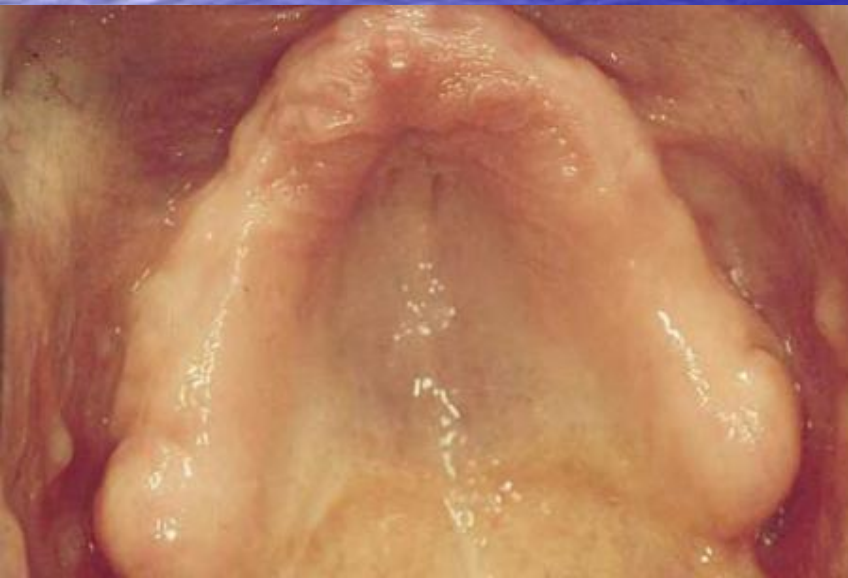
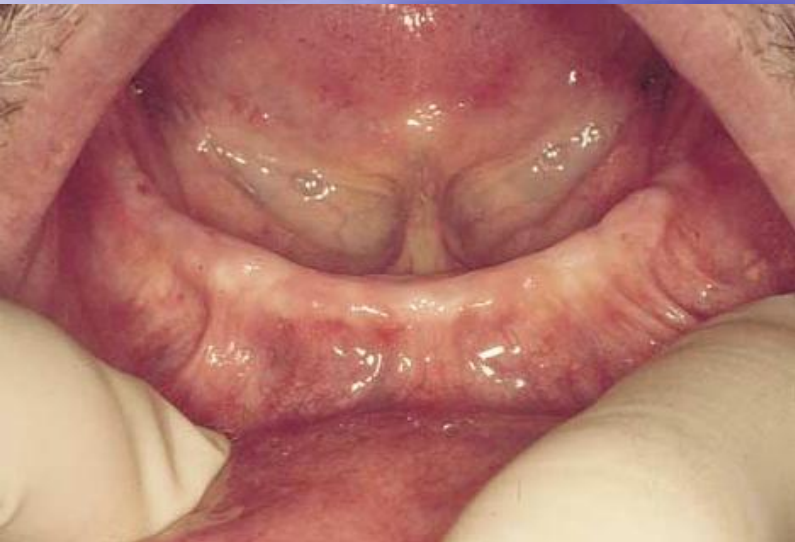

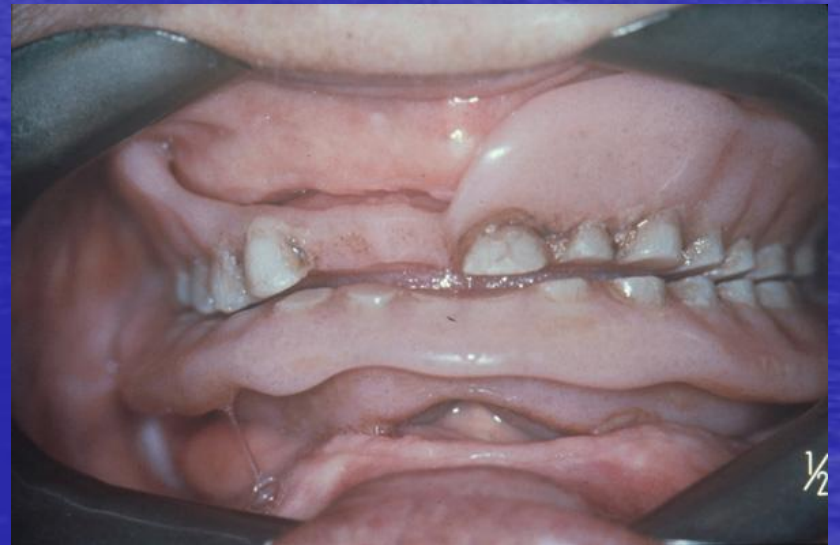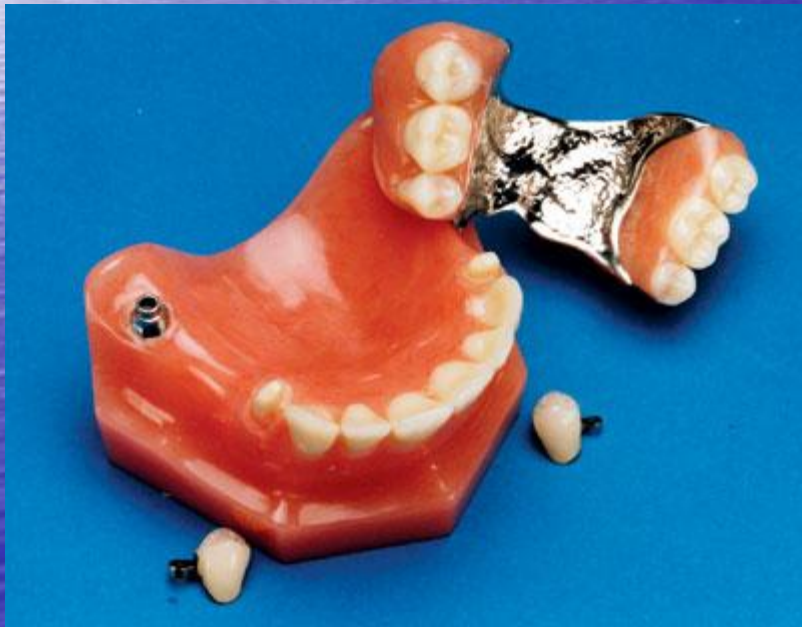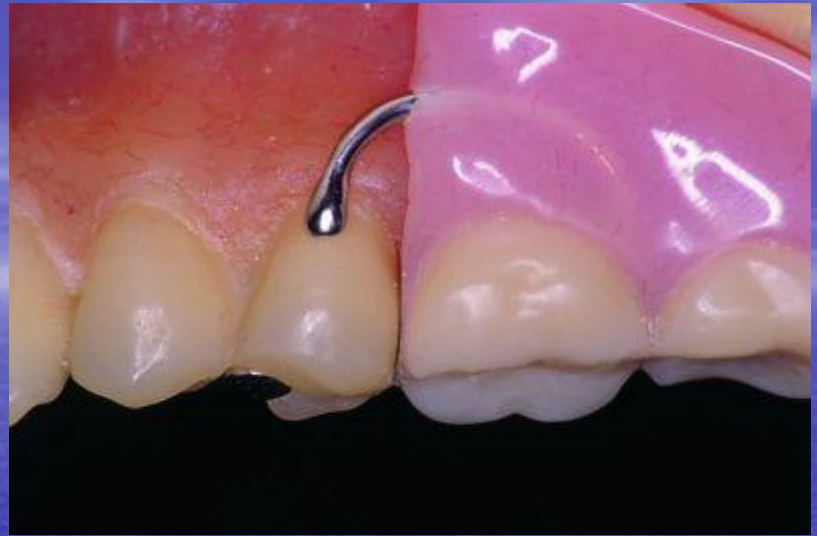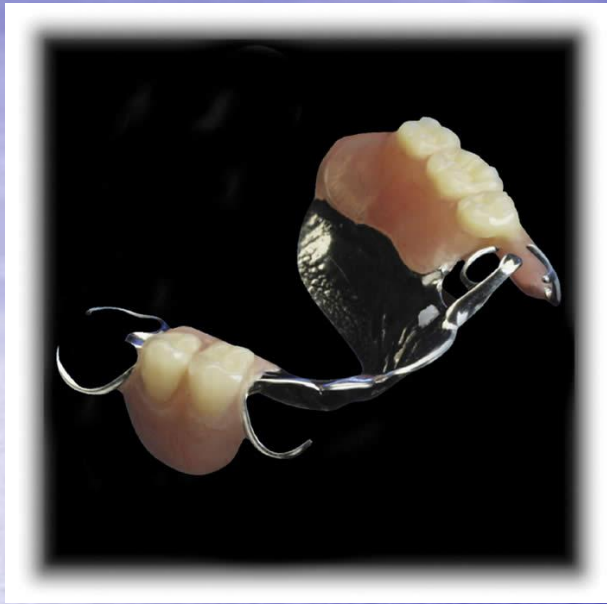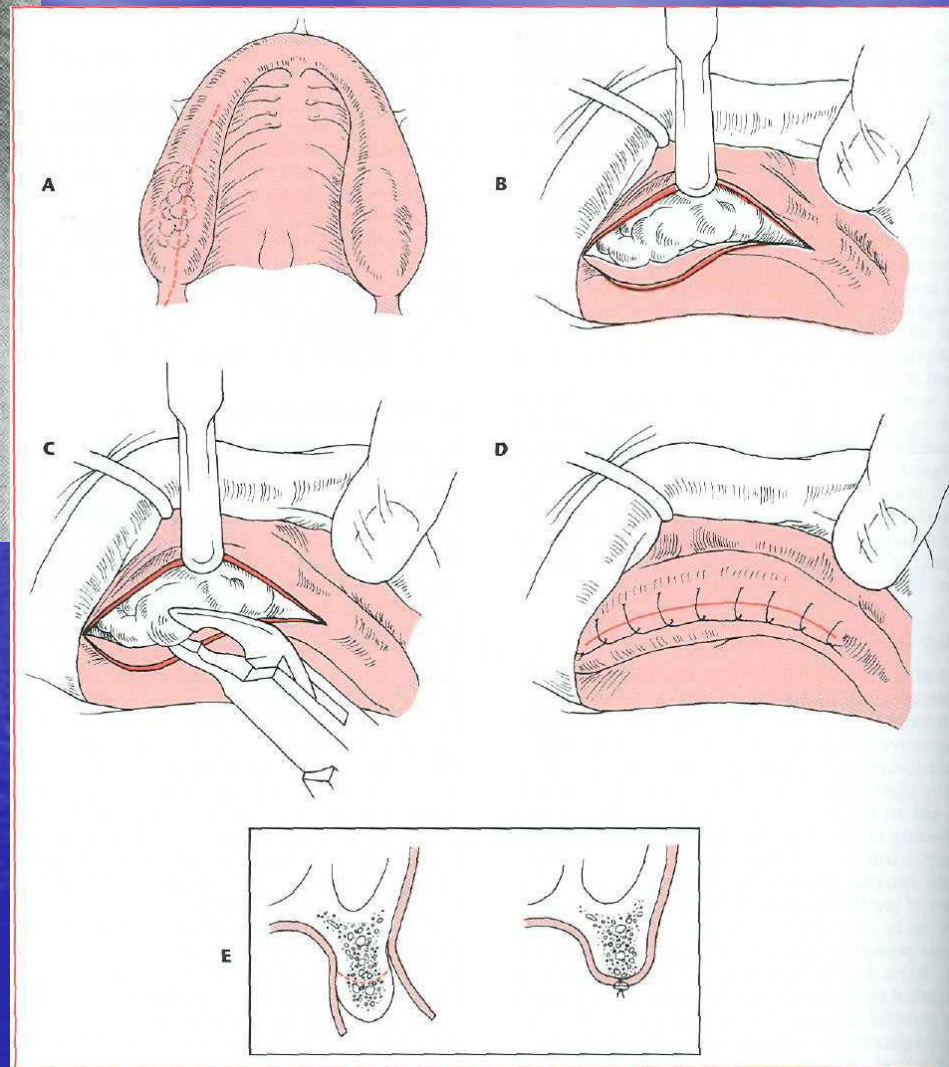
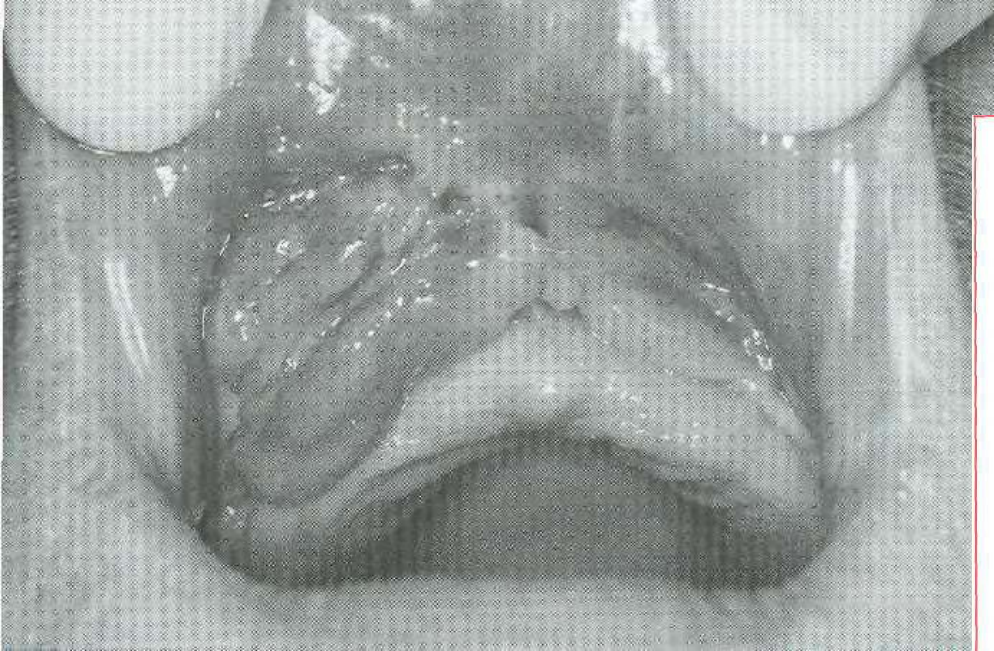


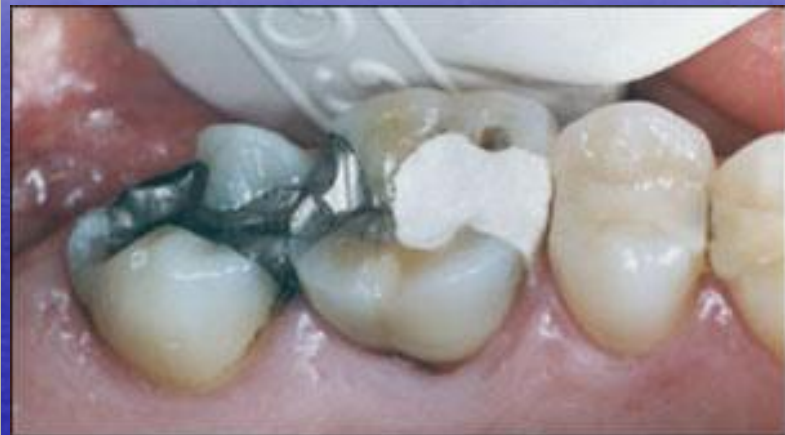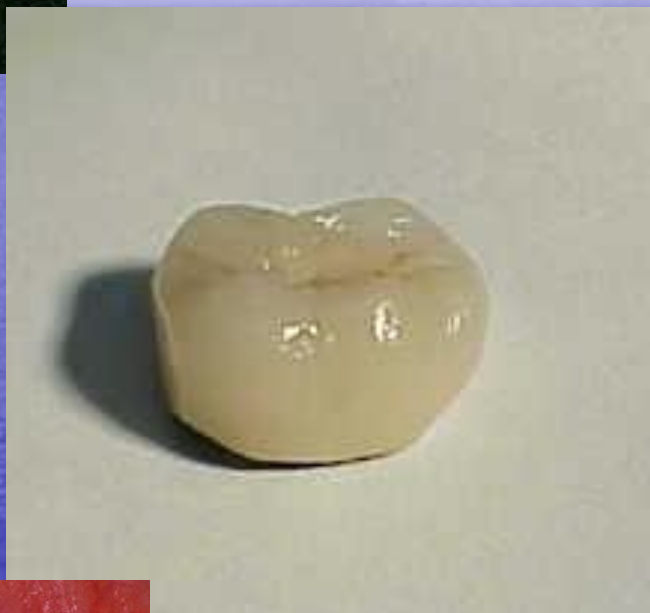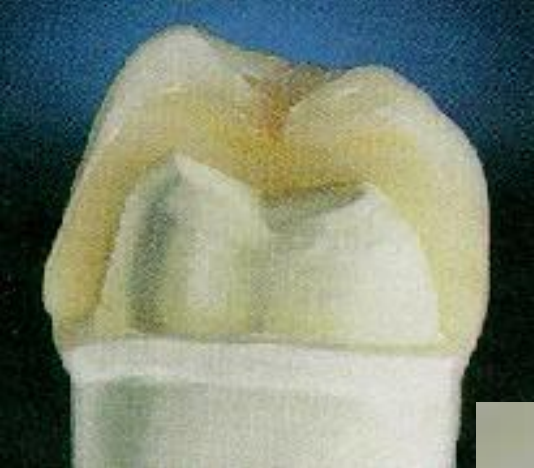Submandibular sialadenectomy (excision of submandibular gland) is indicated for various conditions, ranging from chronic infection to tumors. The submandibular gland has a higher incidence of malignant tumors than the parotid gland (about $\frac{2}{3}$ of tumors are malignant versus $\frac{1}{5}$ in the parotid). Stones may form in the duct or inside the substance of the gland, causing it to swell. The marginal mandibular branch of the facial nerve runs just lateral to the gland and is carefully localized prior to removing the gland.

Protetika

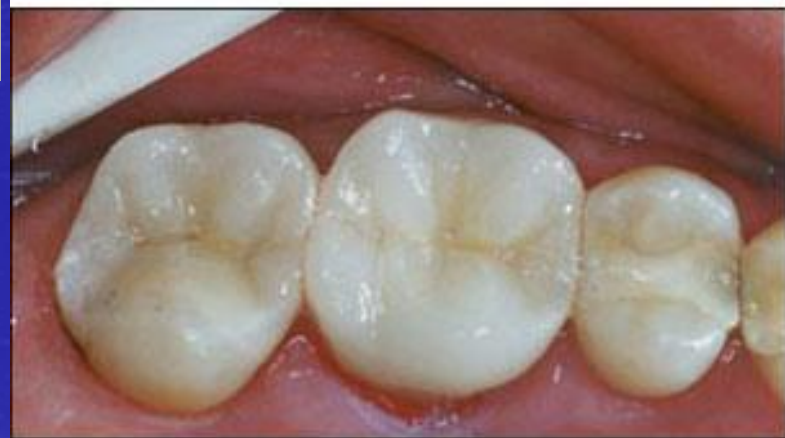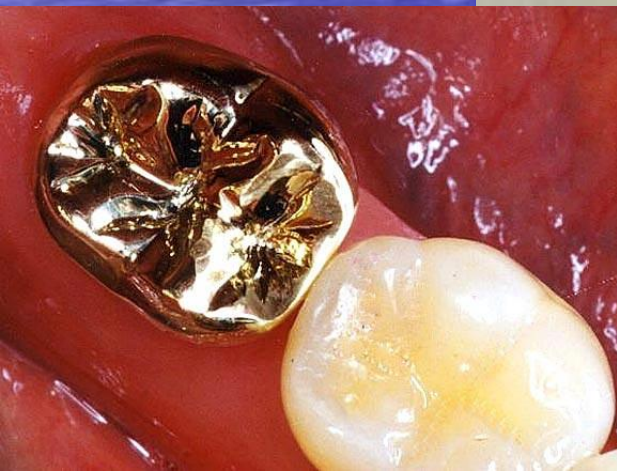




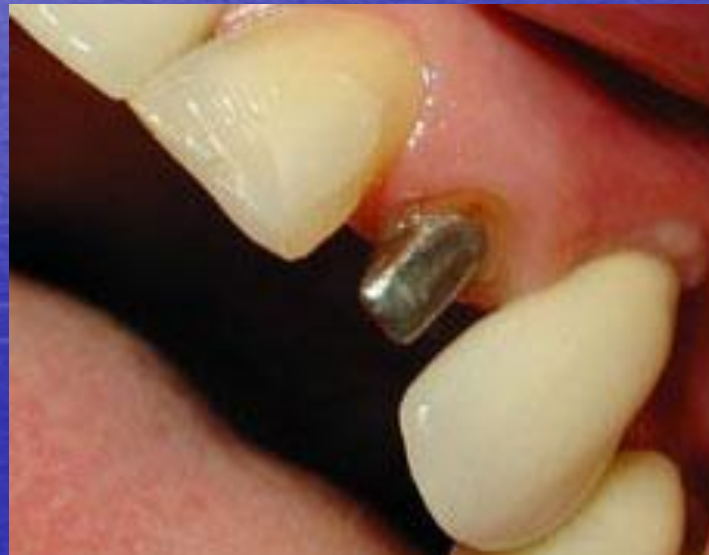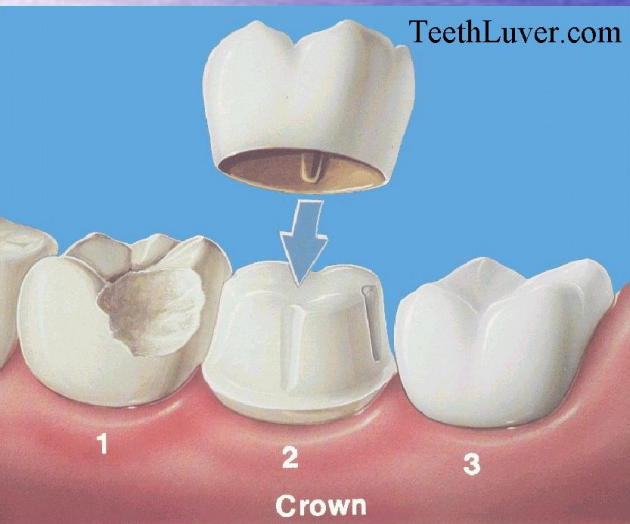


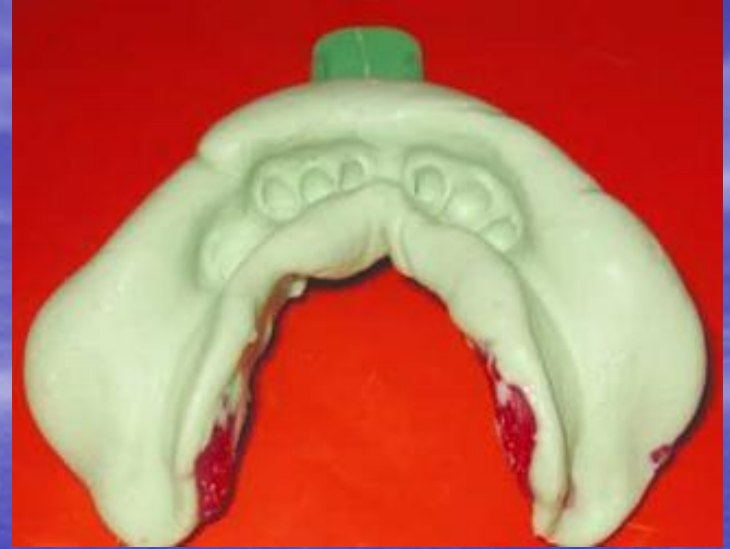
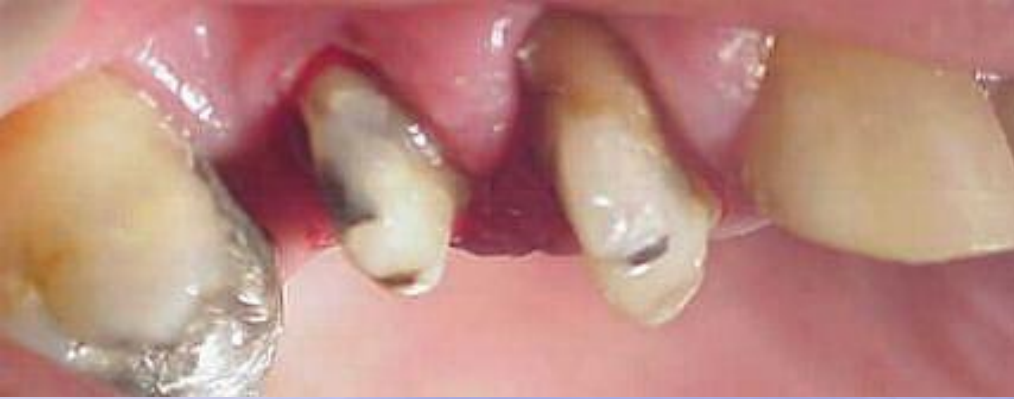
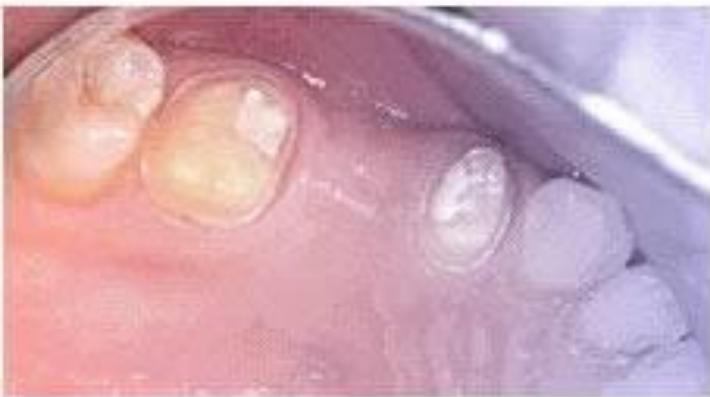Before

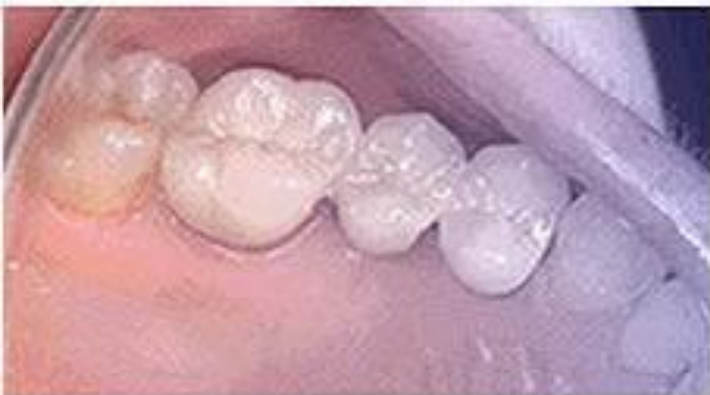

After

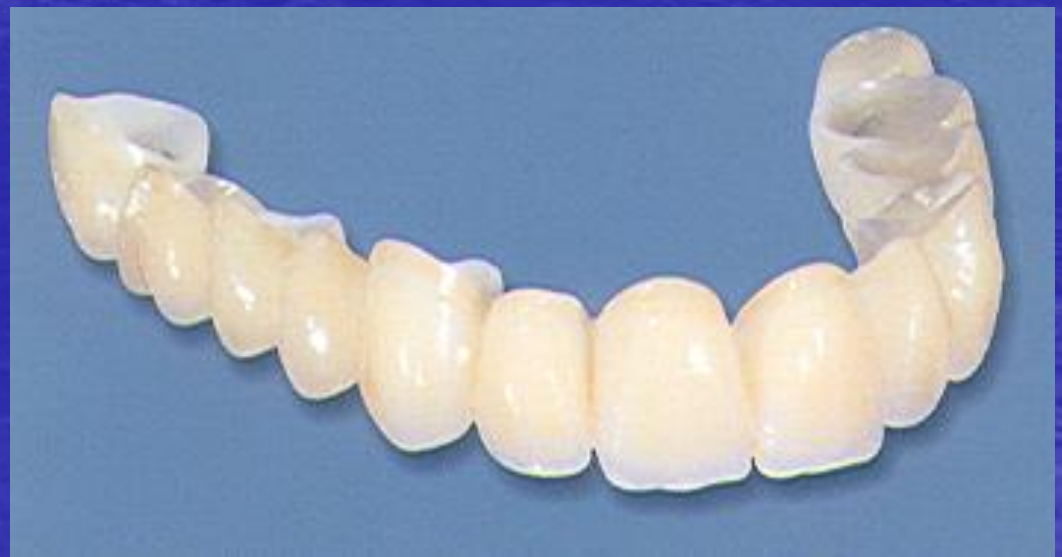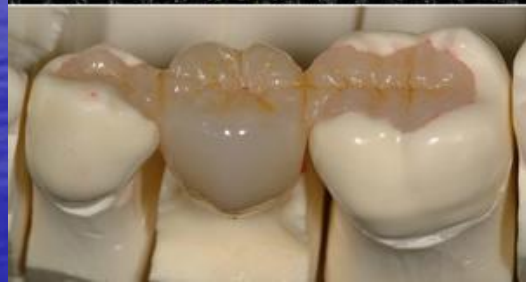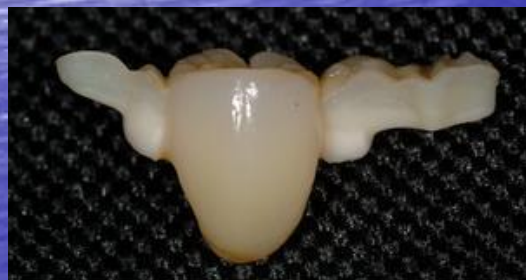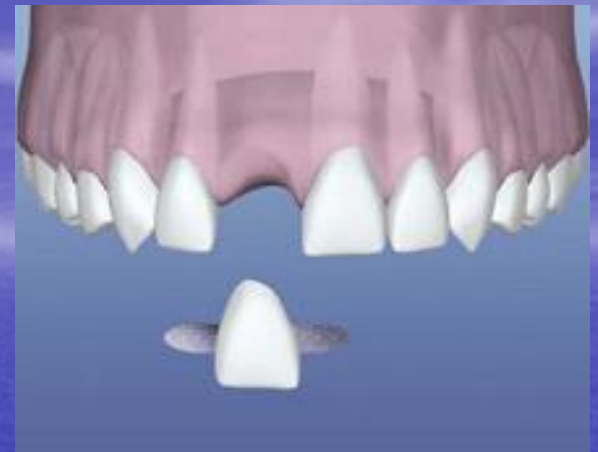




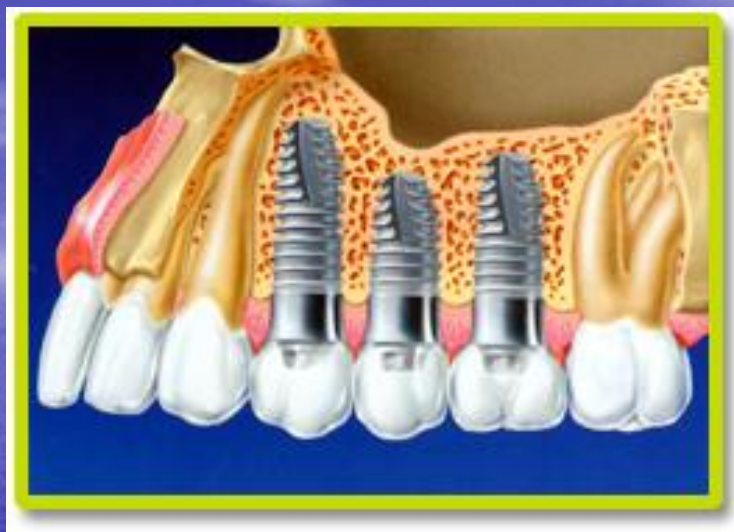**Prepared teeth, ready
for bridge to be placed.**

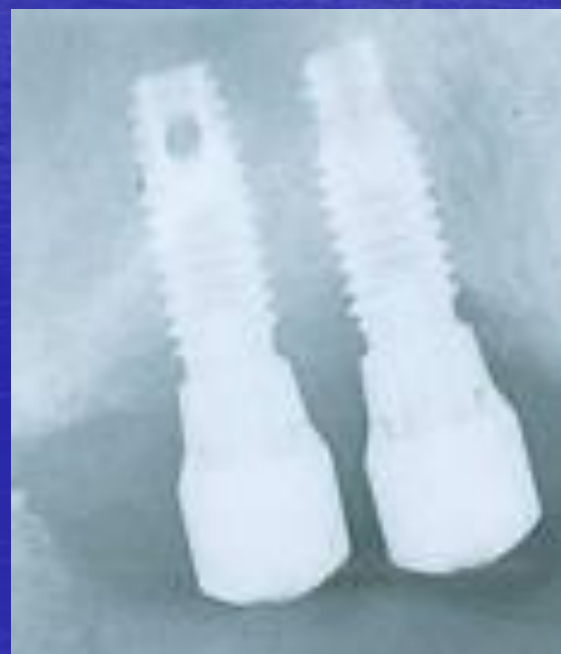
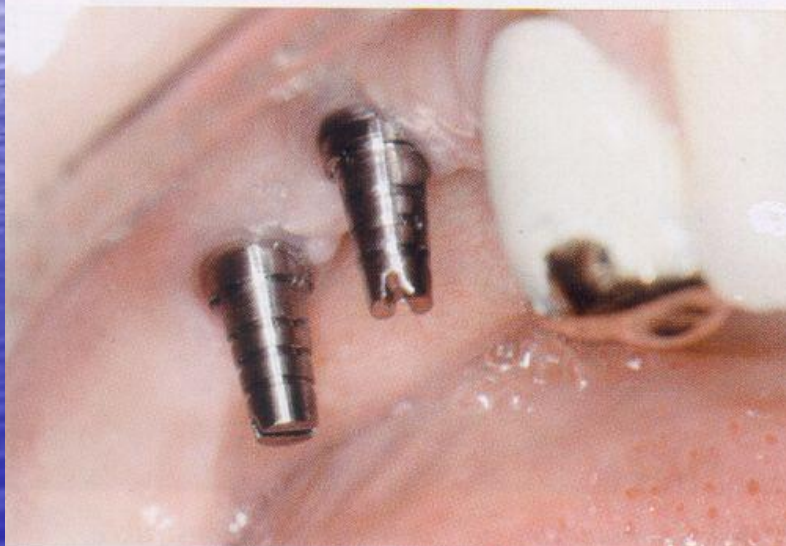
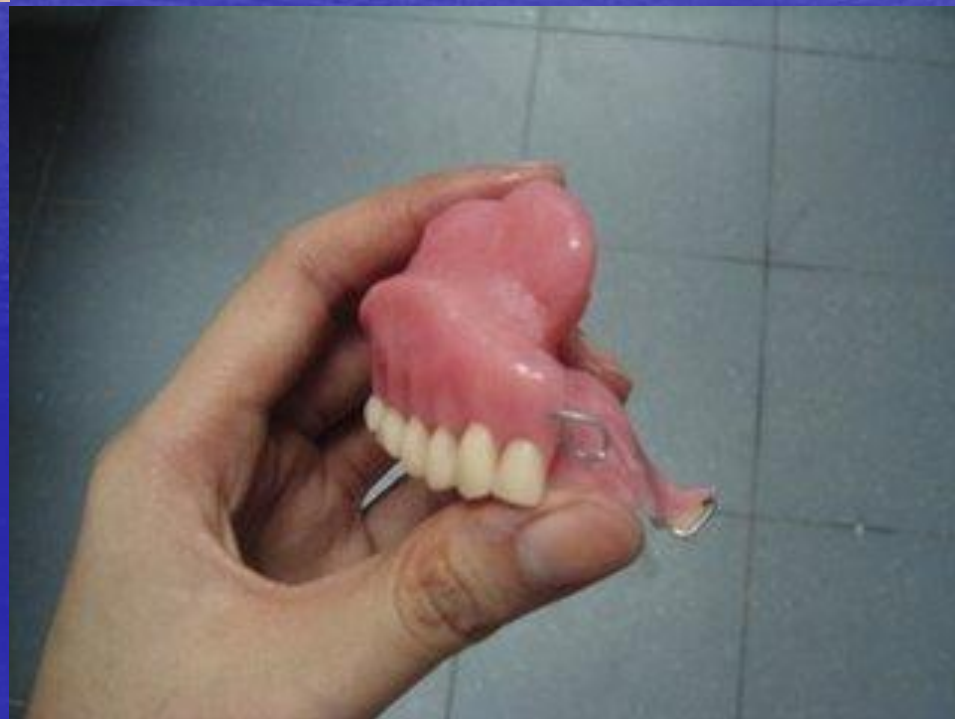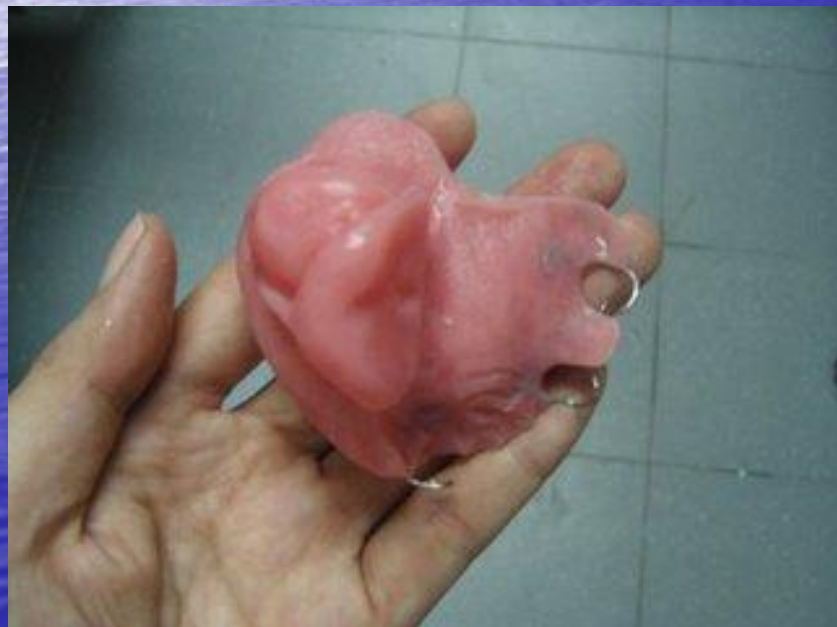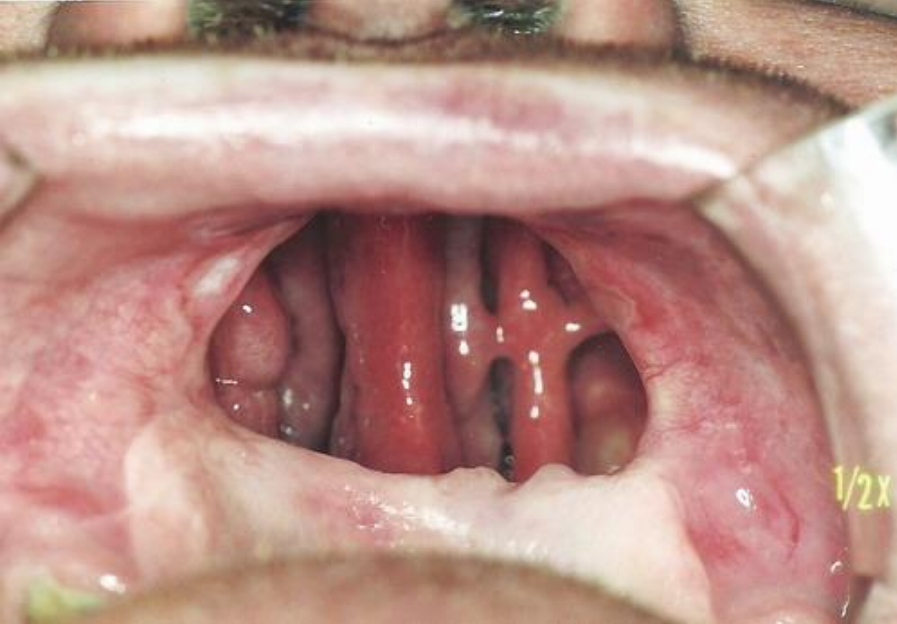Bridge in place.

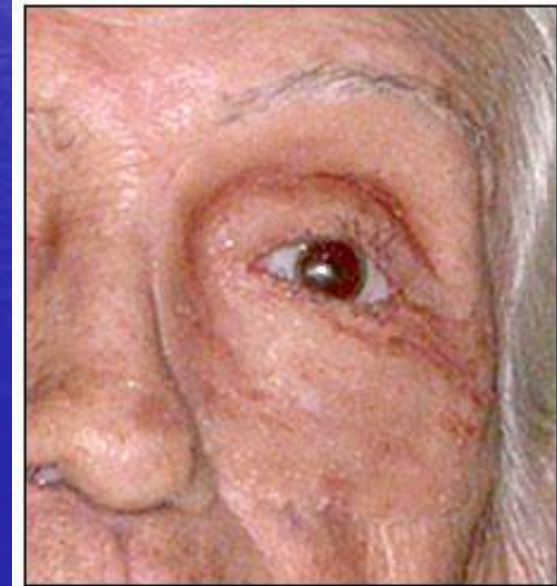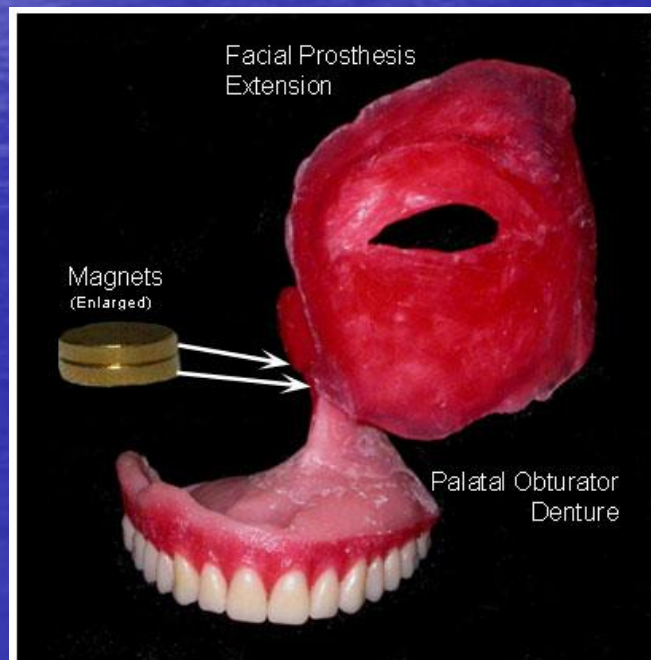

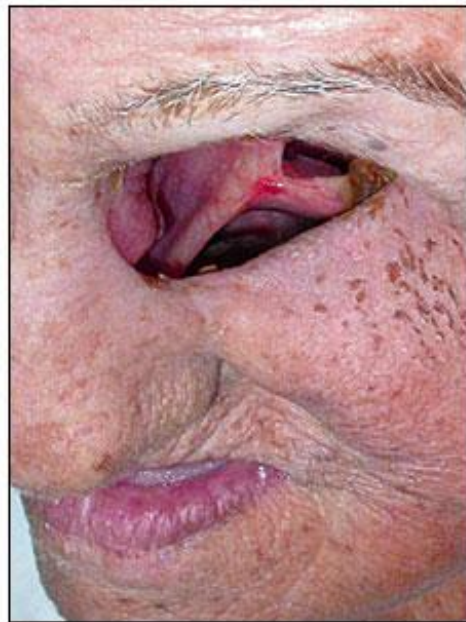
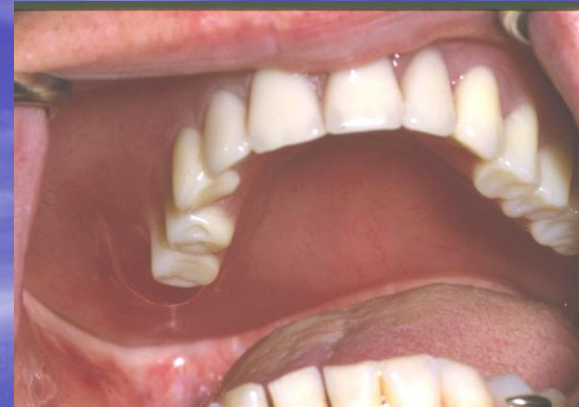
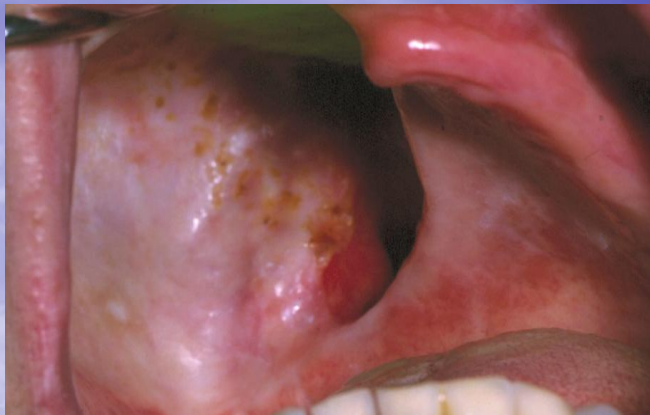
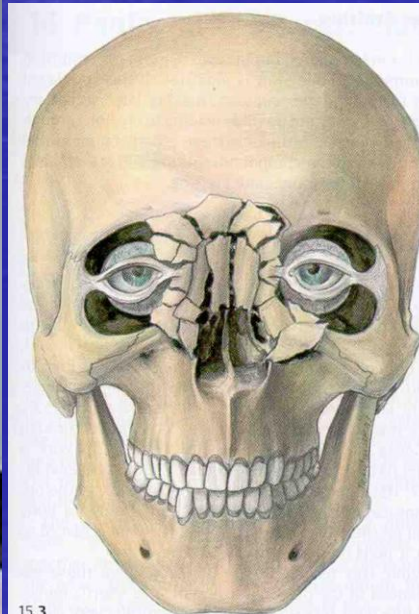
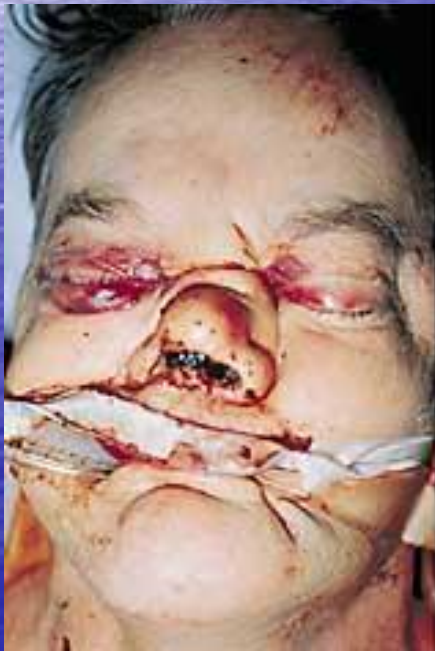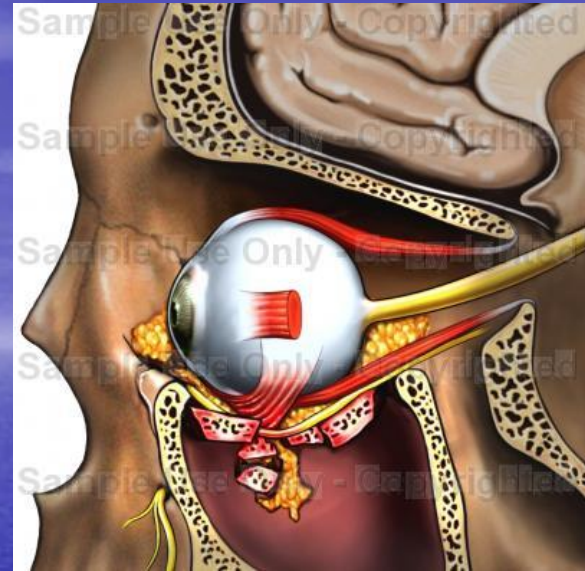
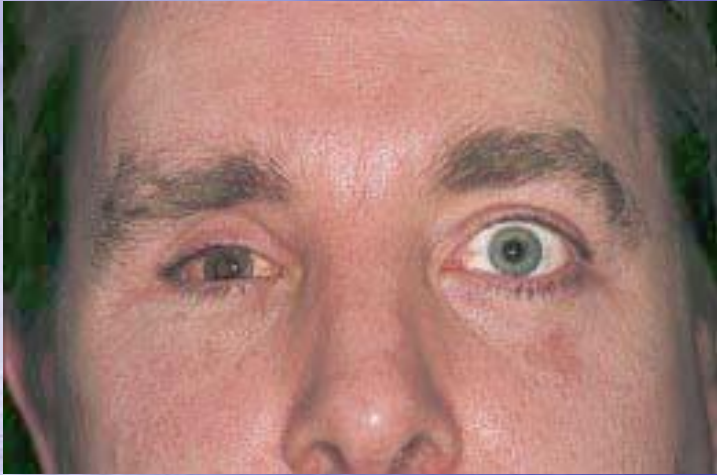Obr. 77: Abutmenty.



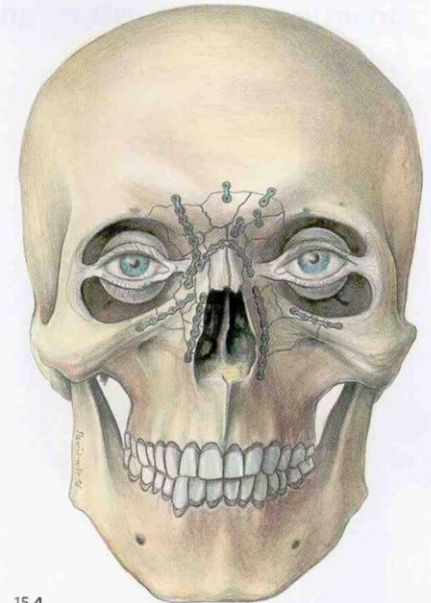




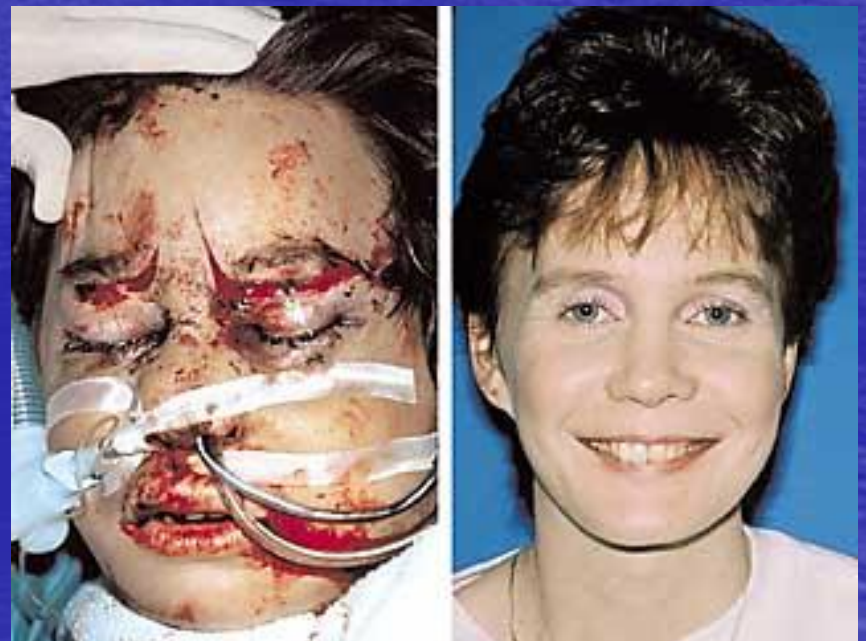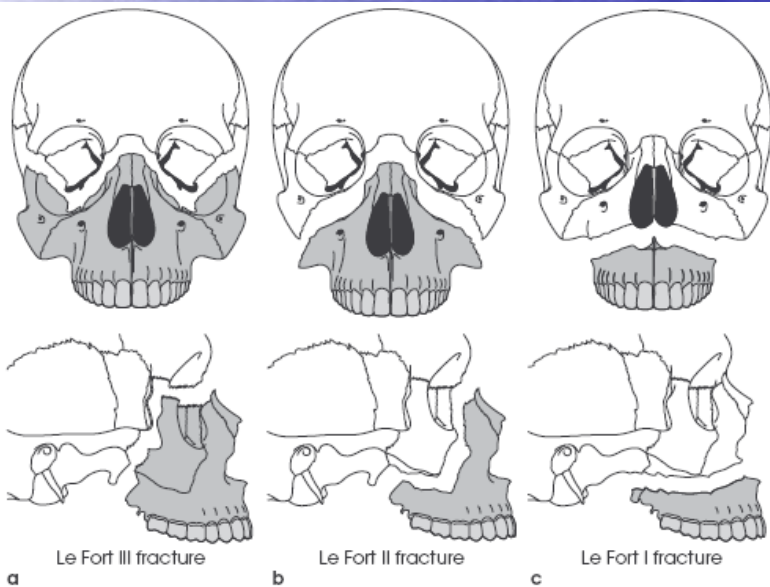
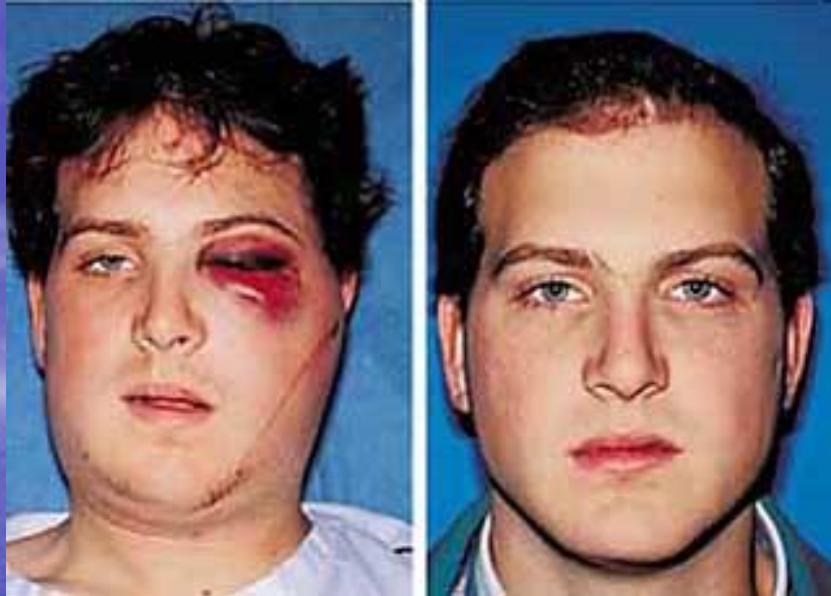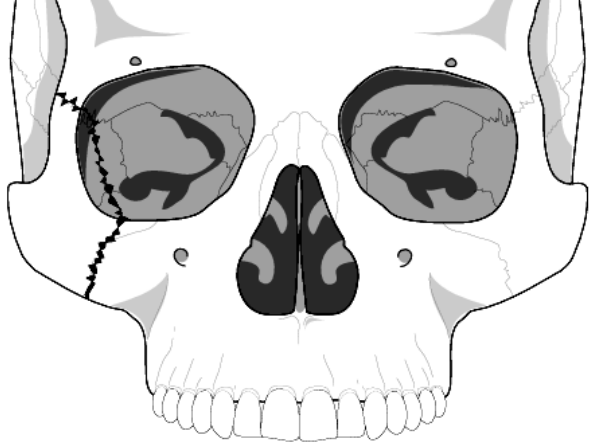
Traumatológia

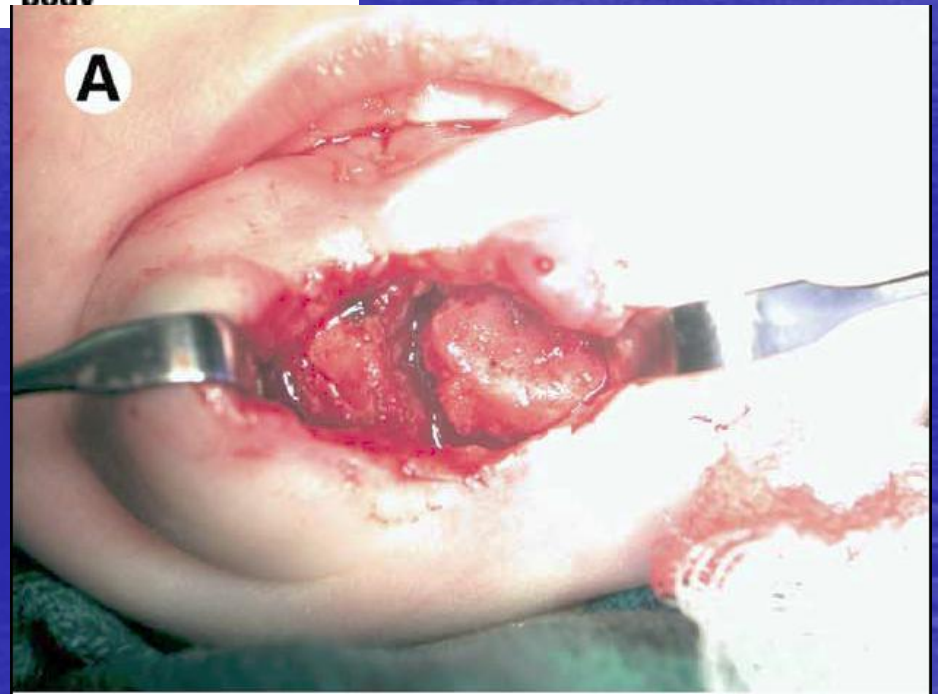
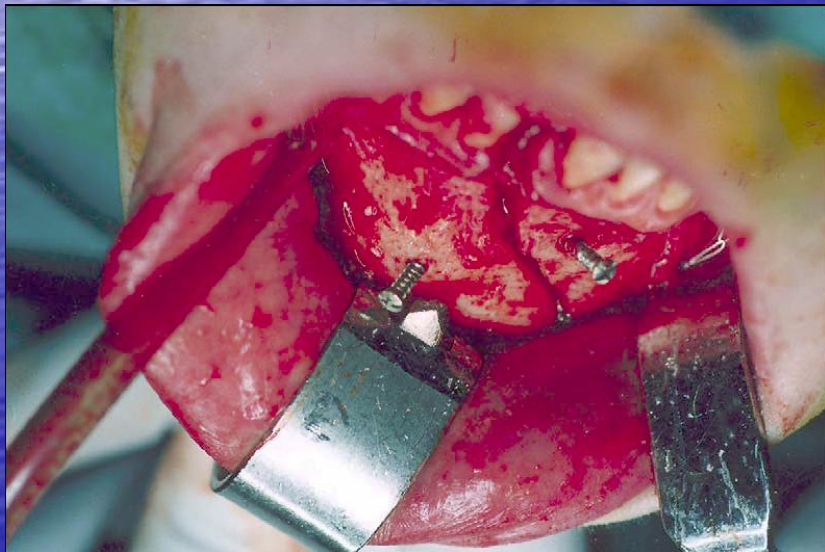
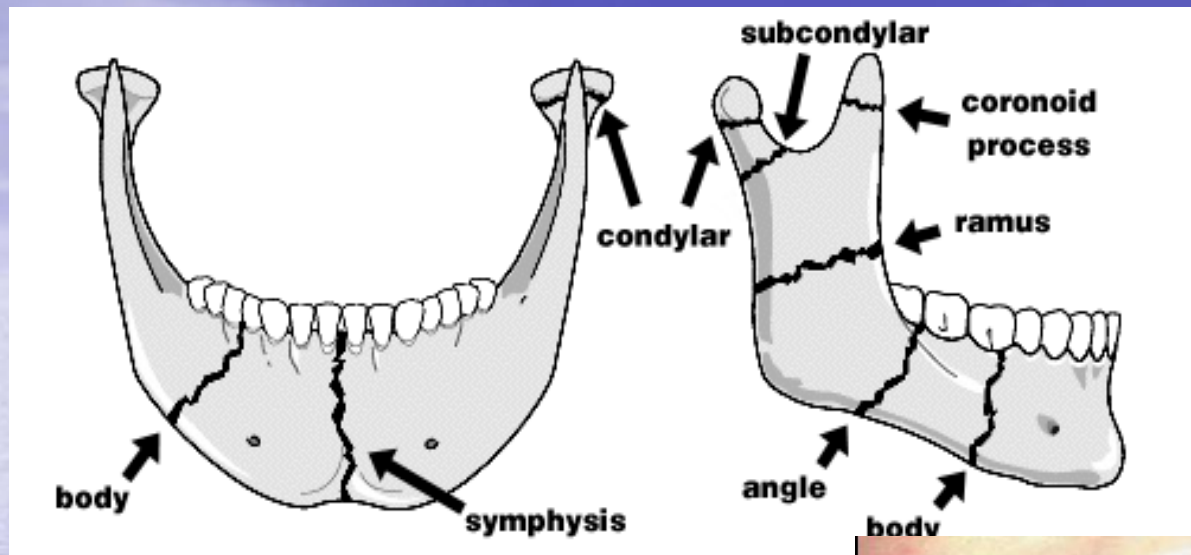


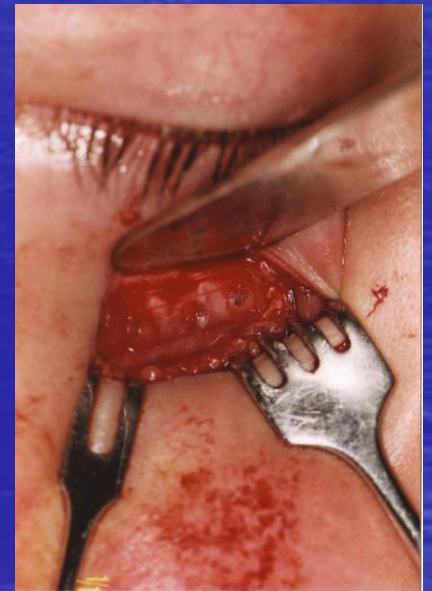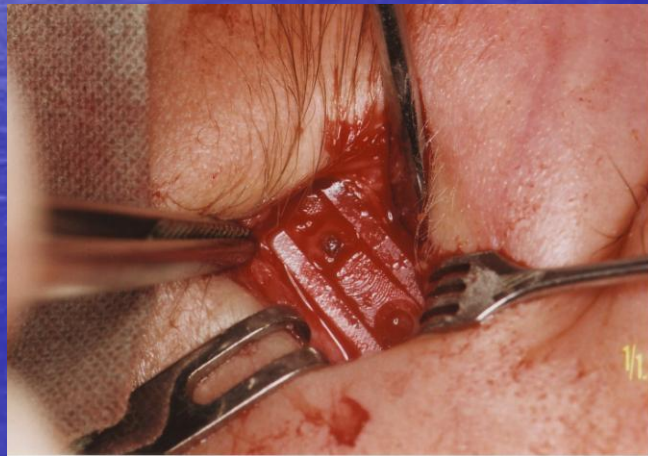
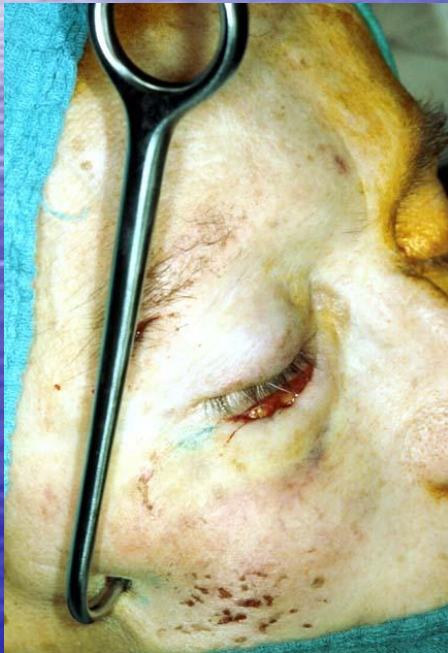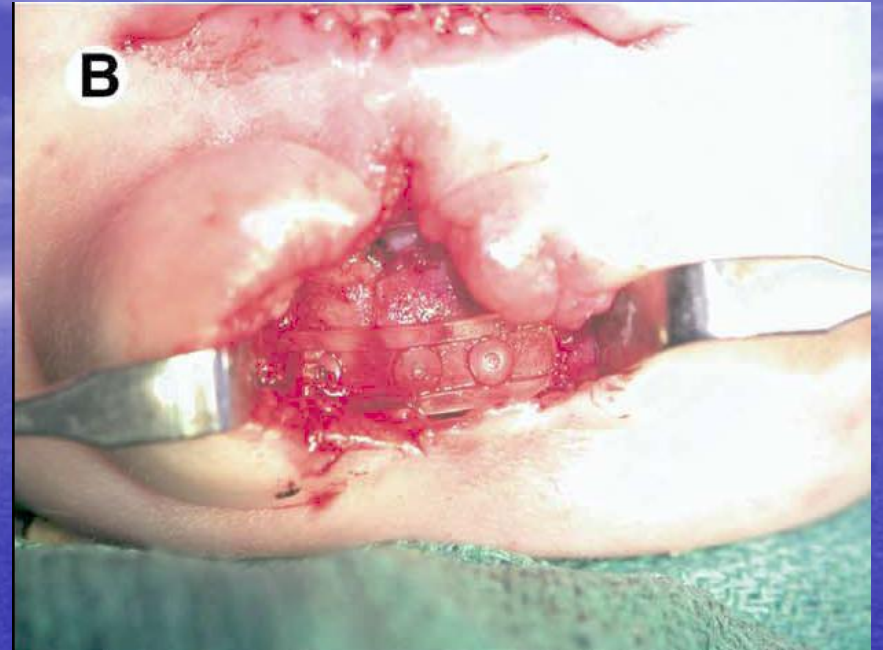
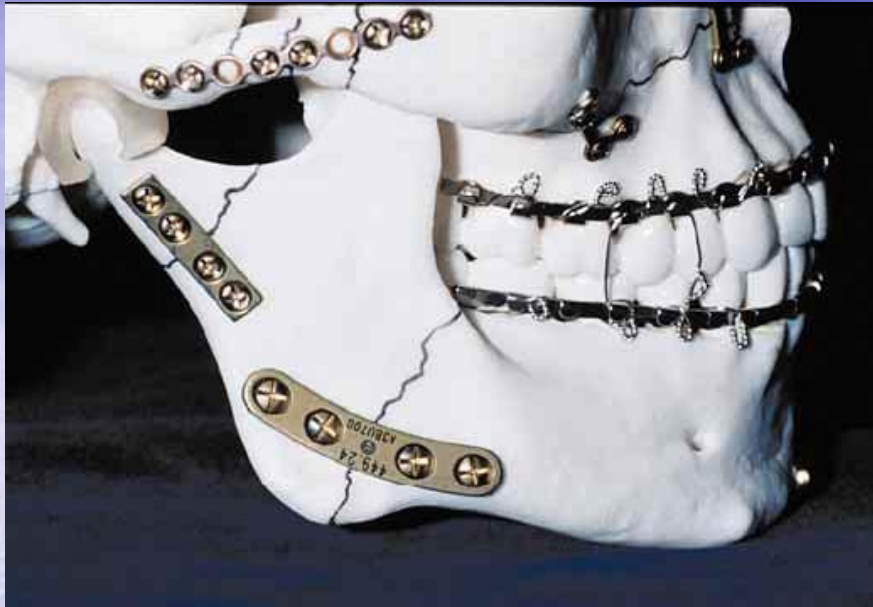15.3

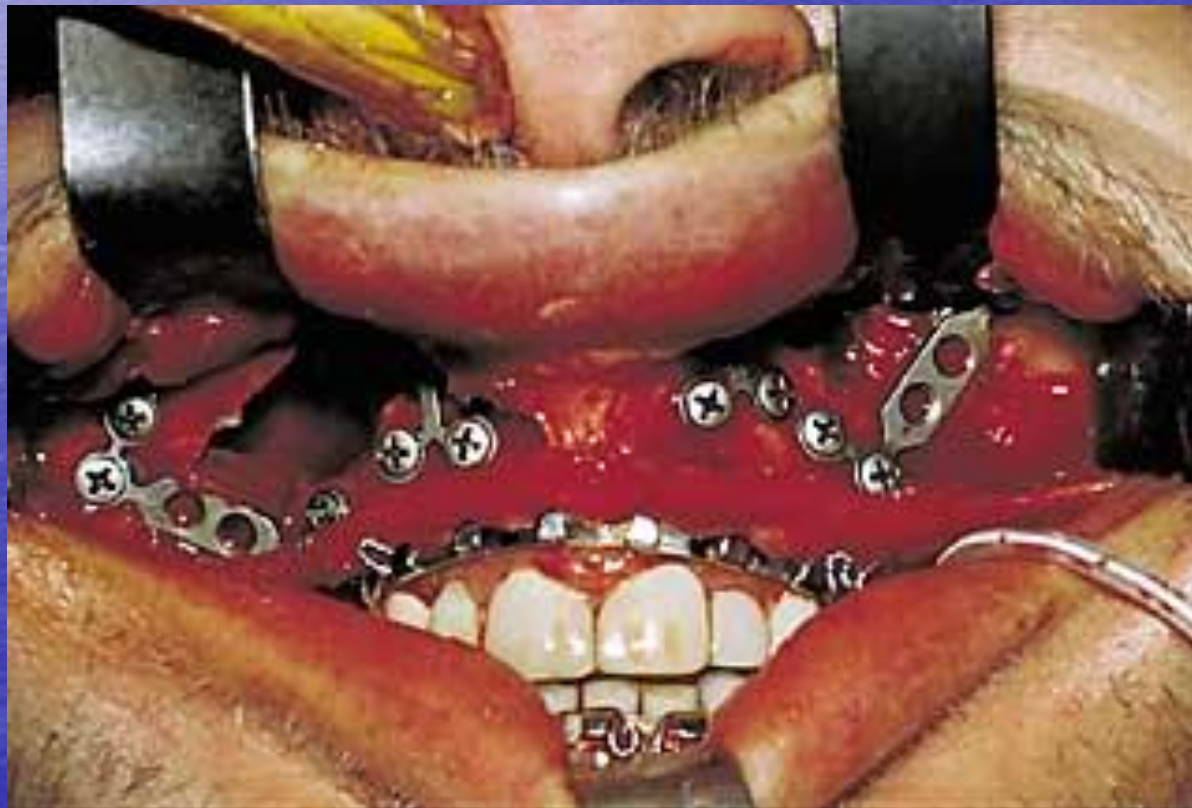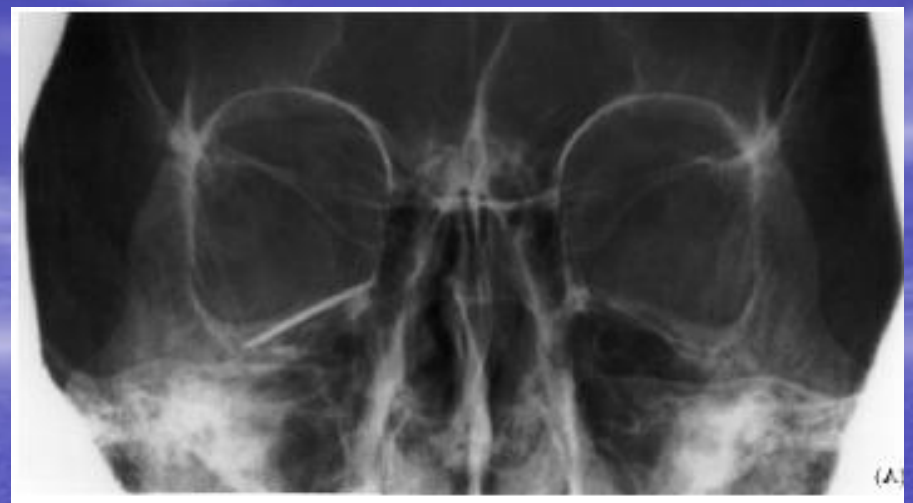
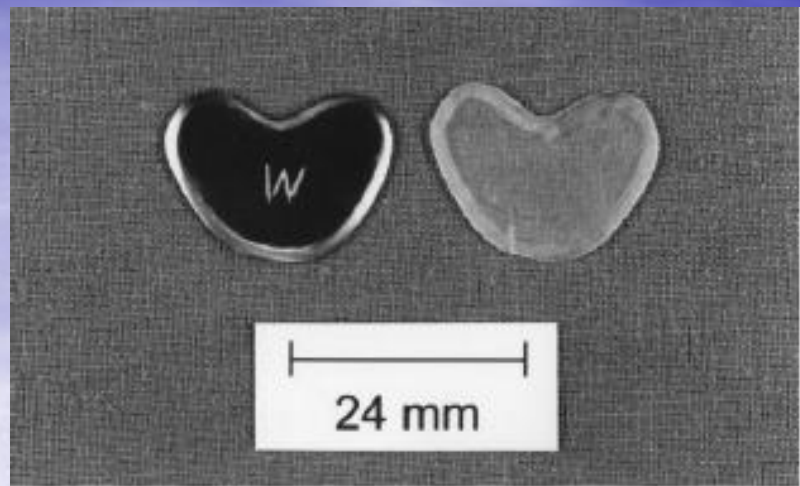


15.4











Ďakujem za pozornosť

