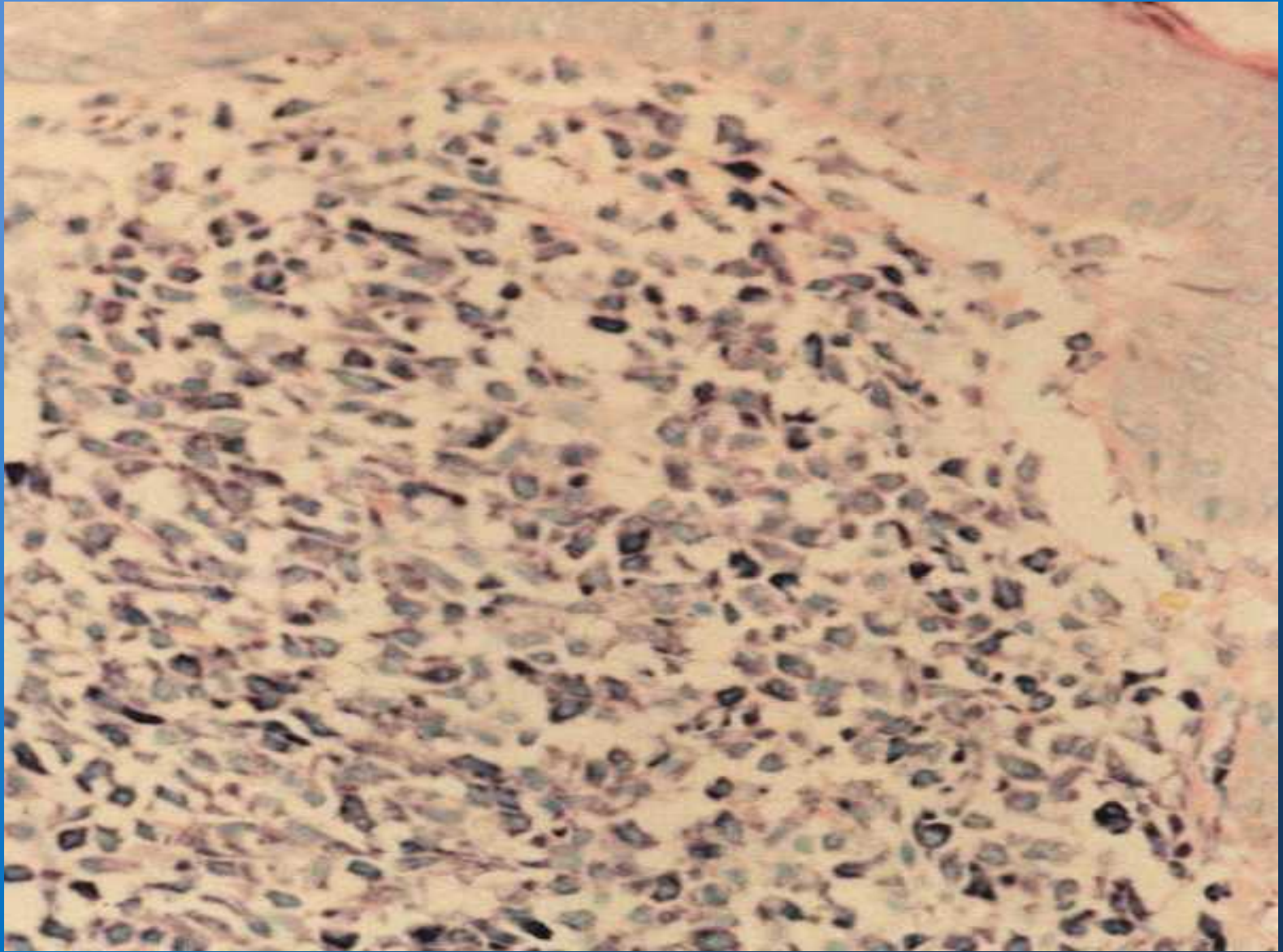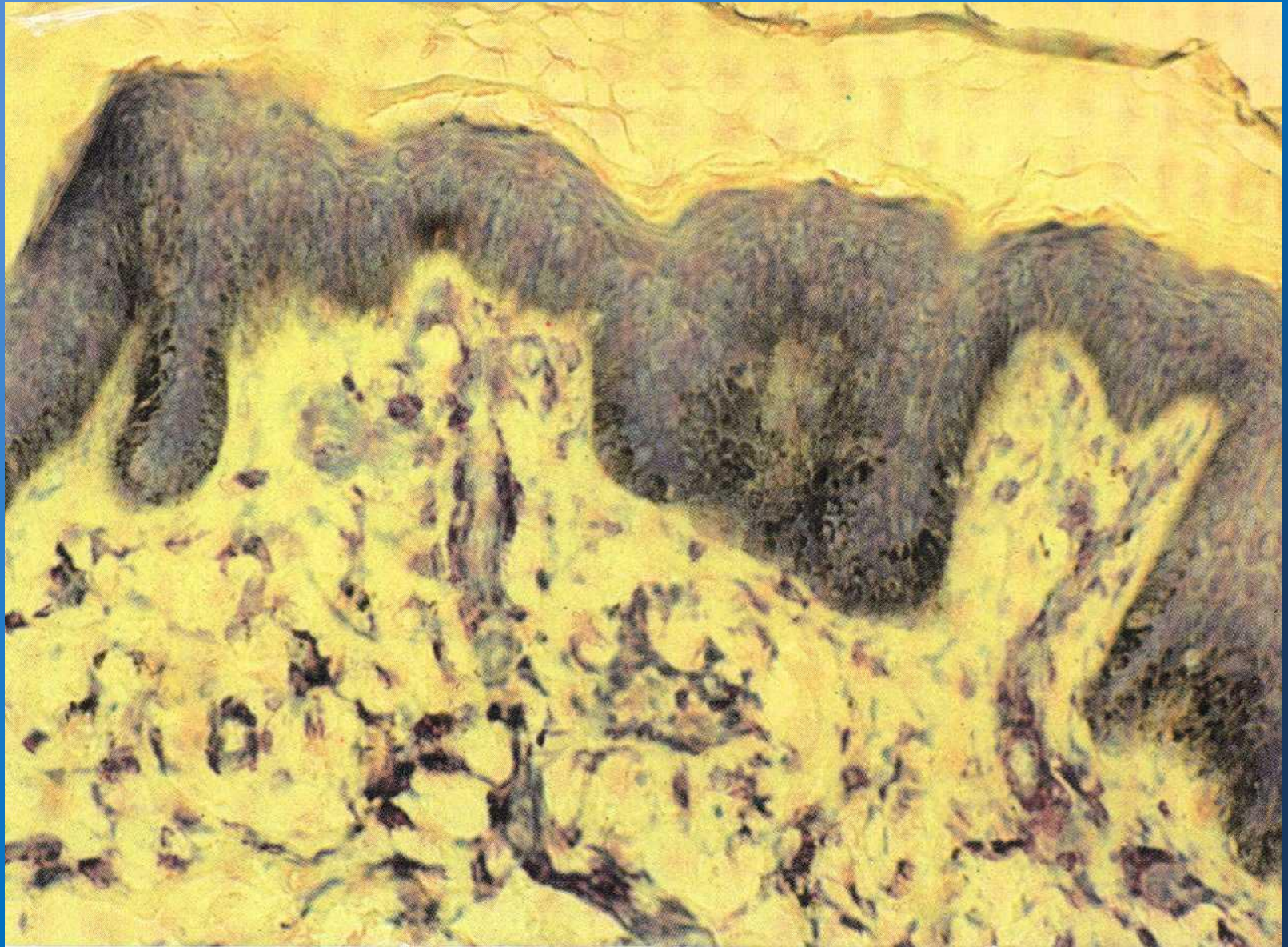
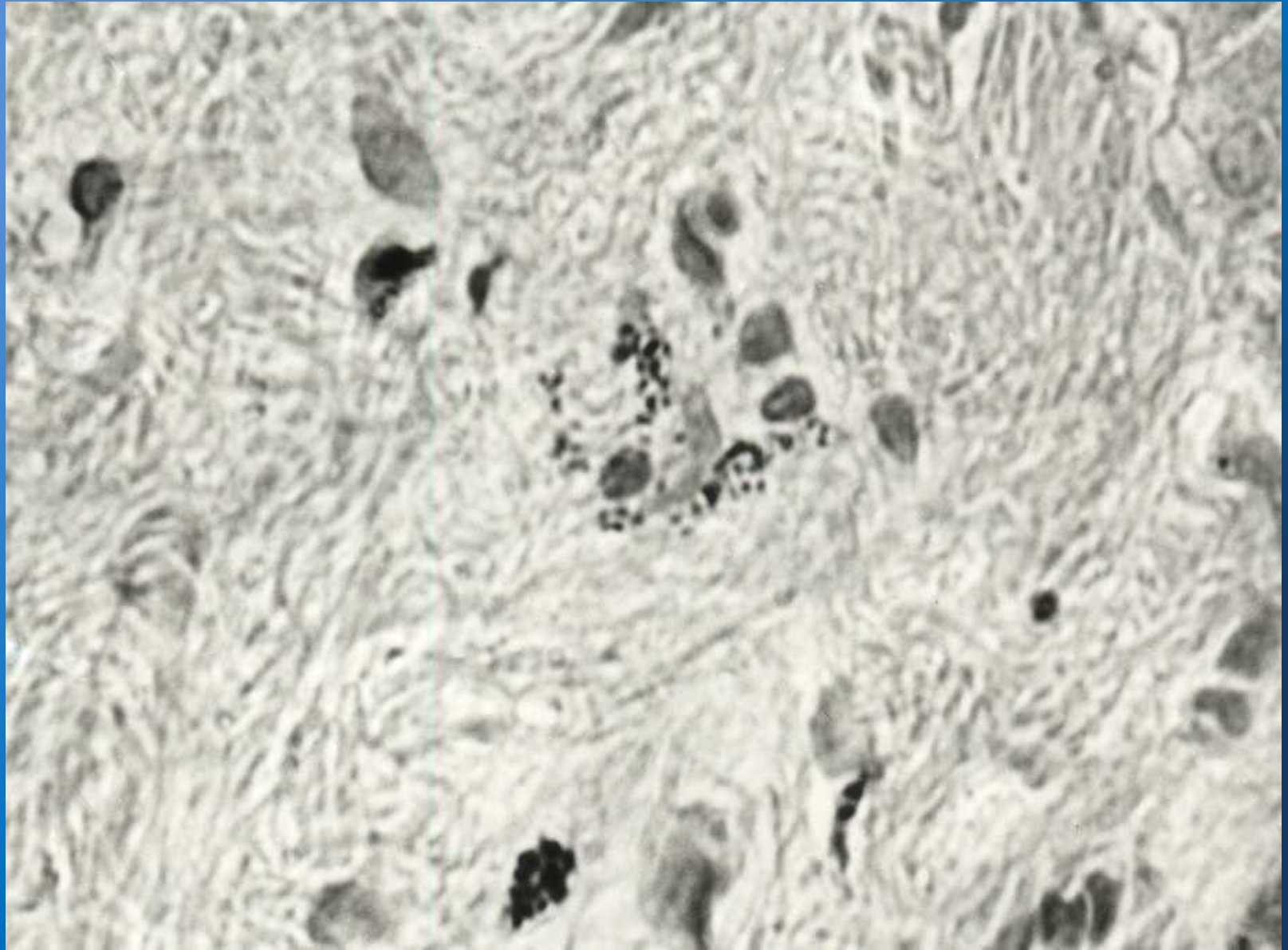


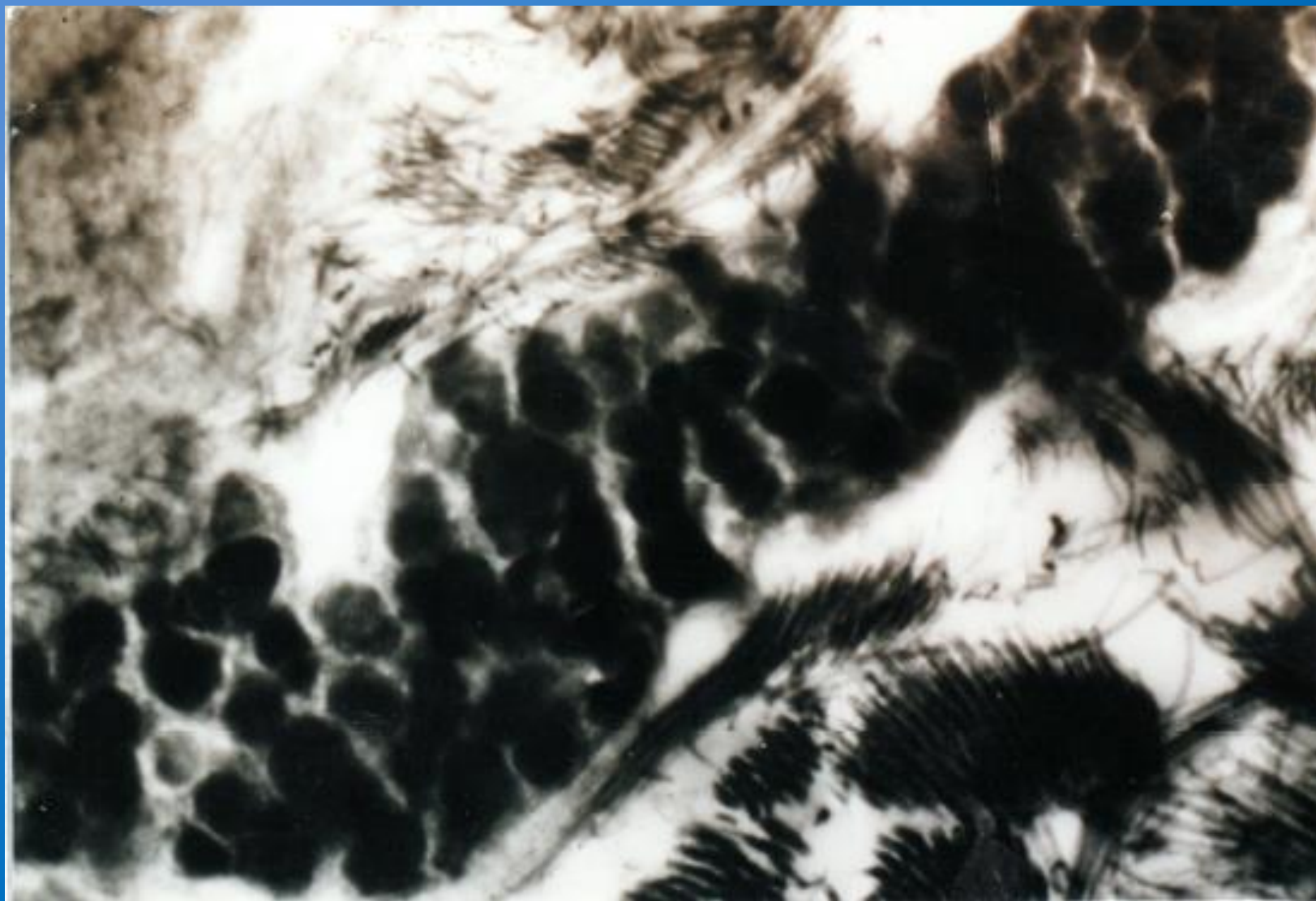
Band-like

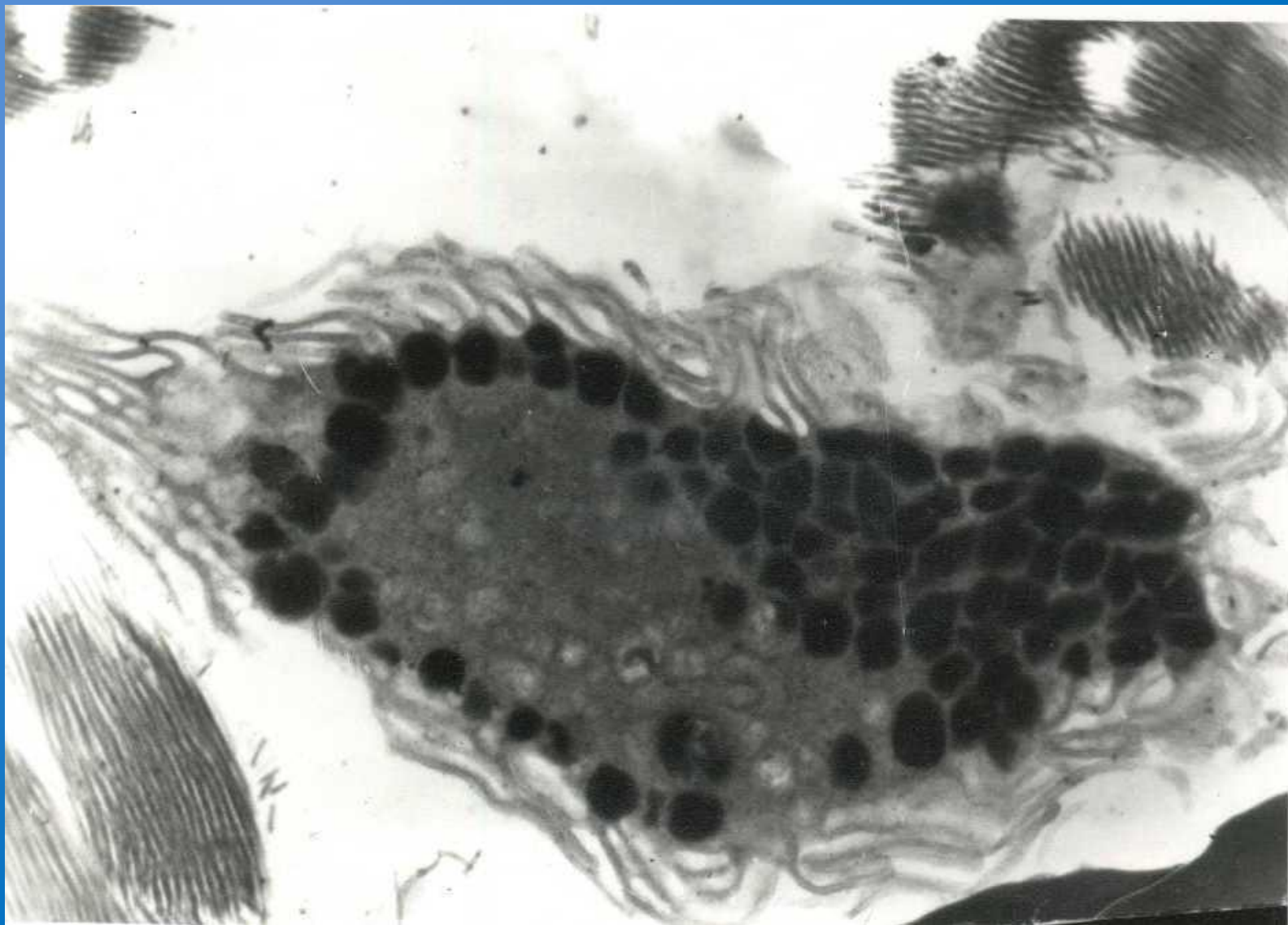






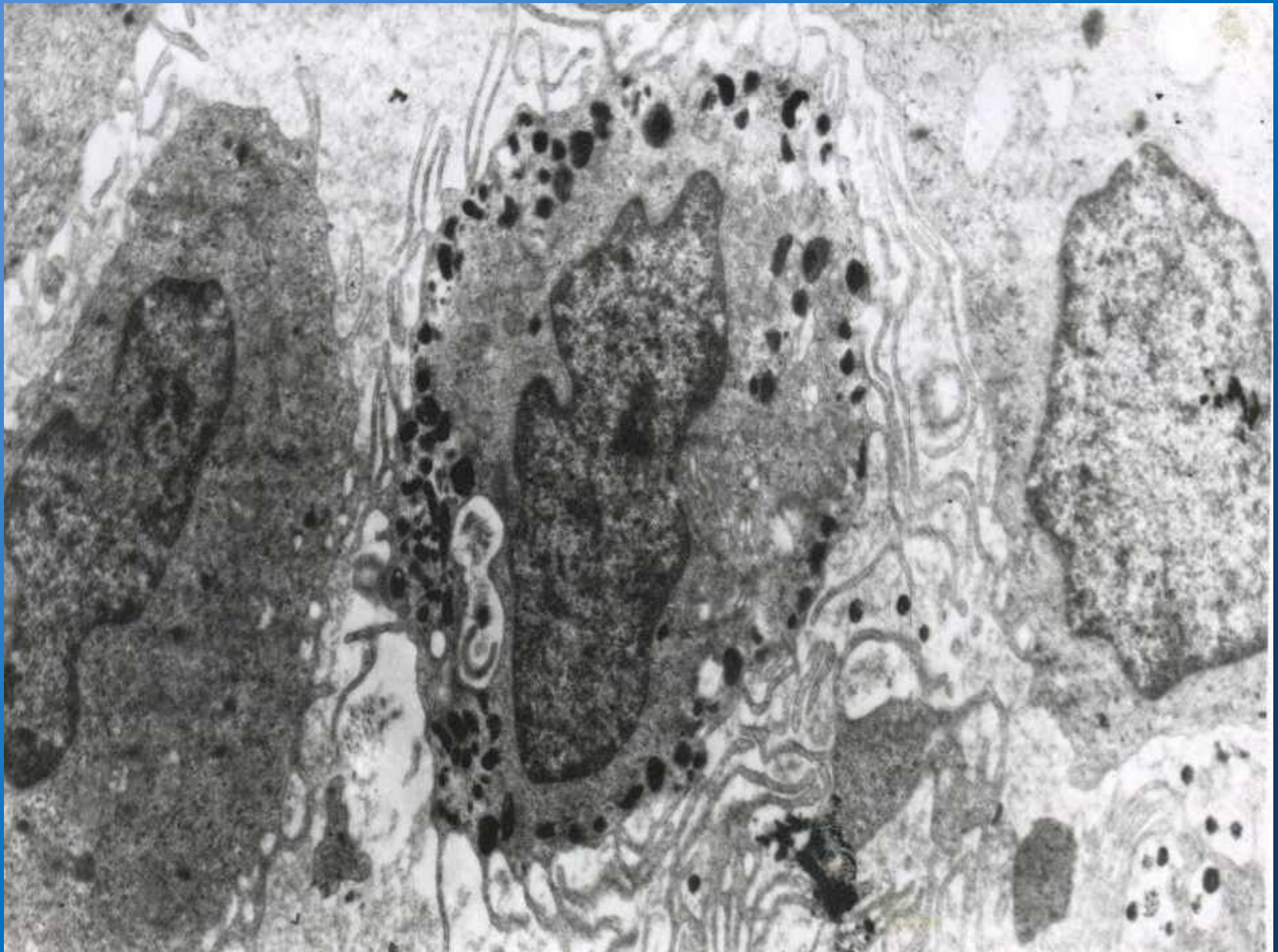





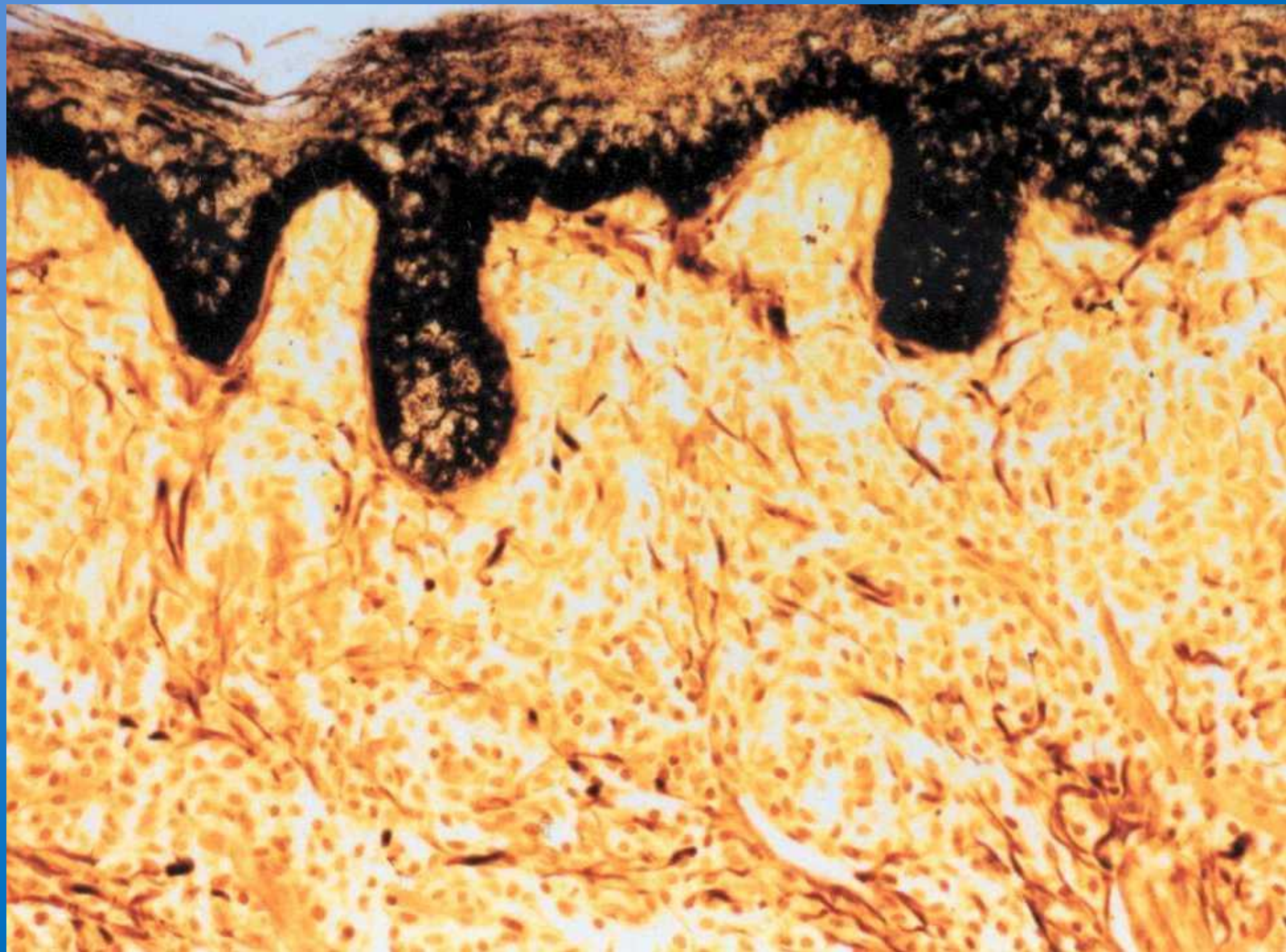
Normálny mastocyt



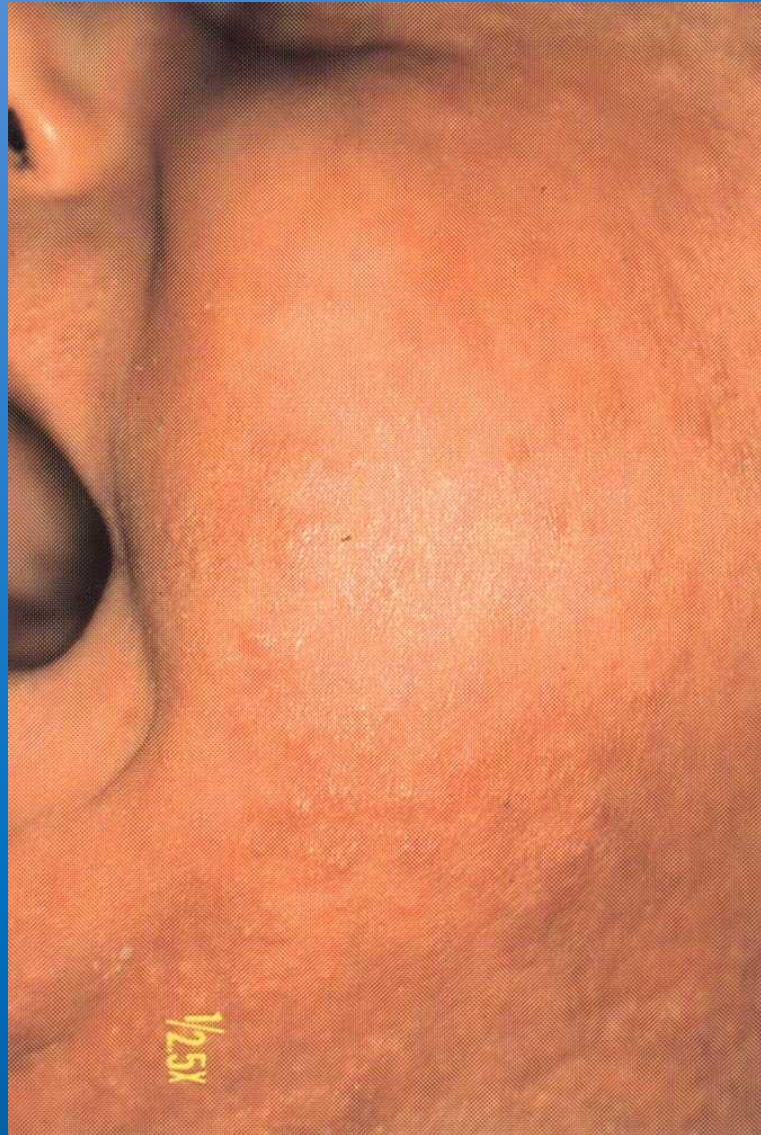

Atypický mastocyt



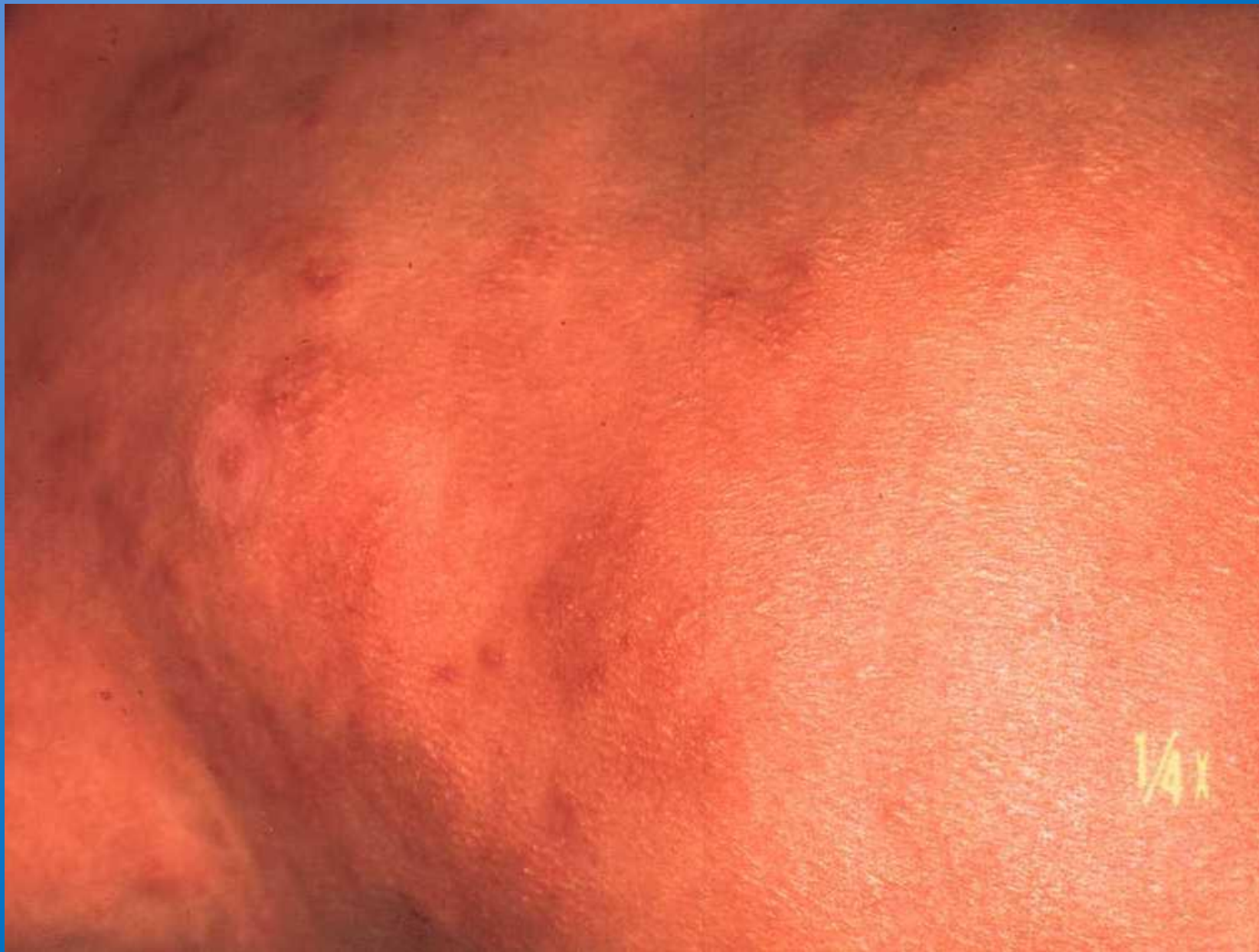



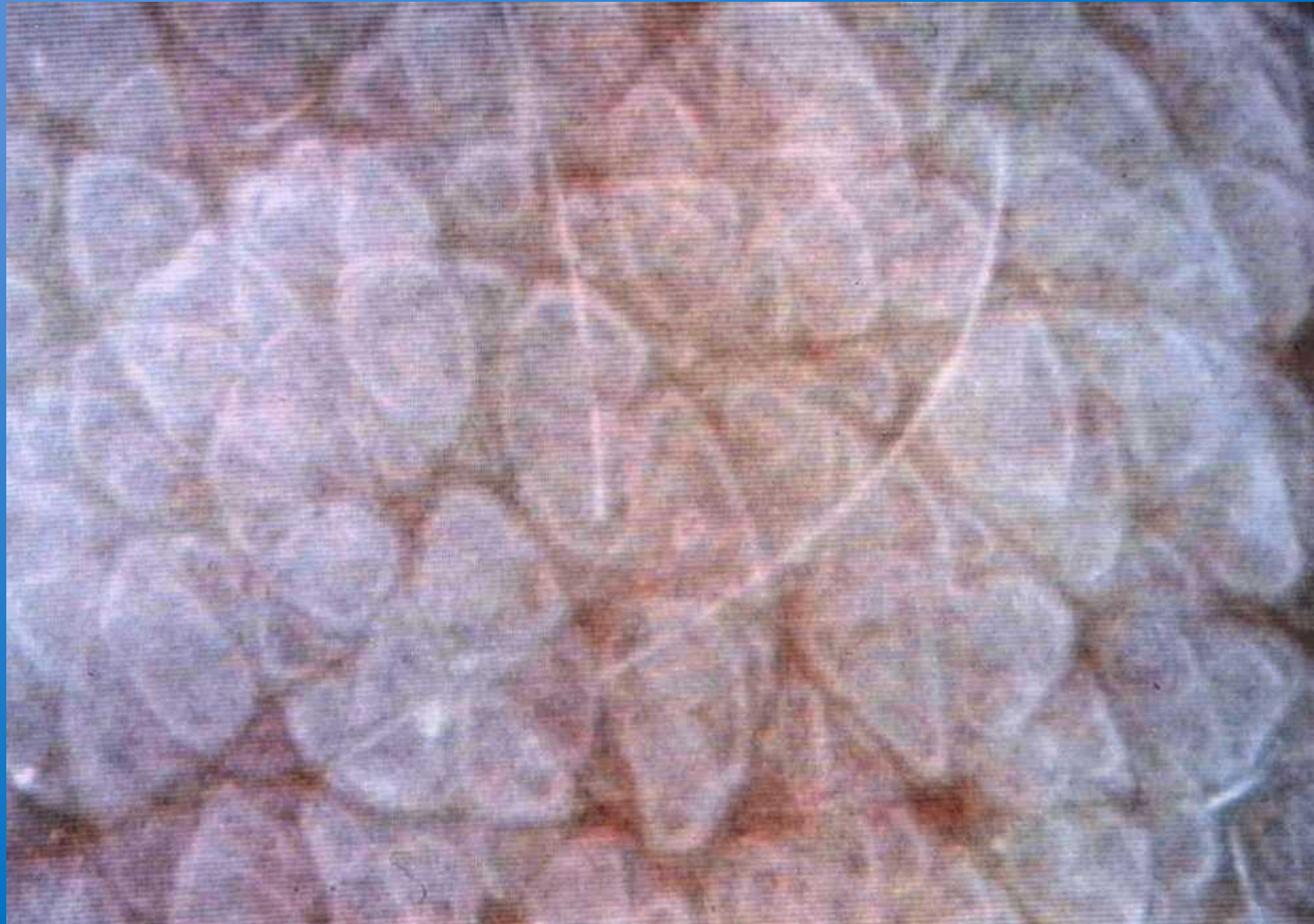


Difúzna kutáňa mastocytóza



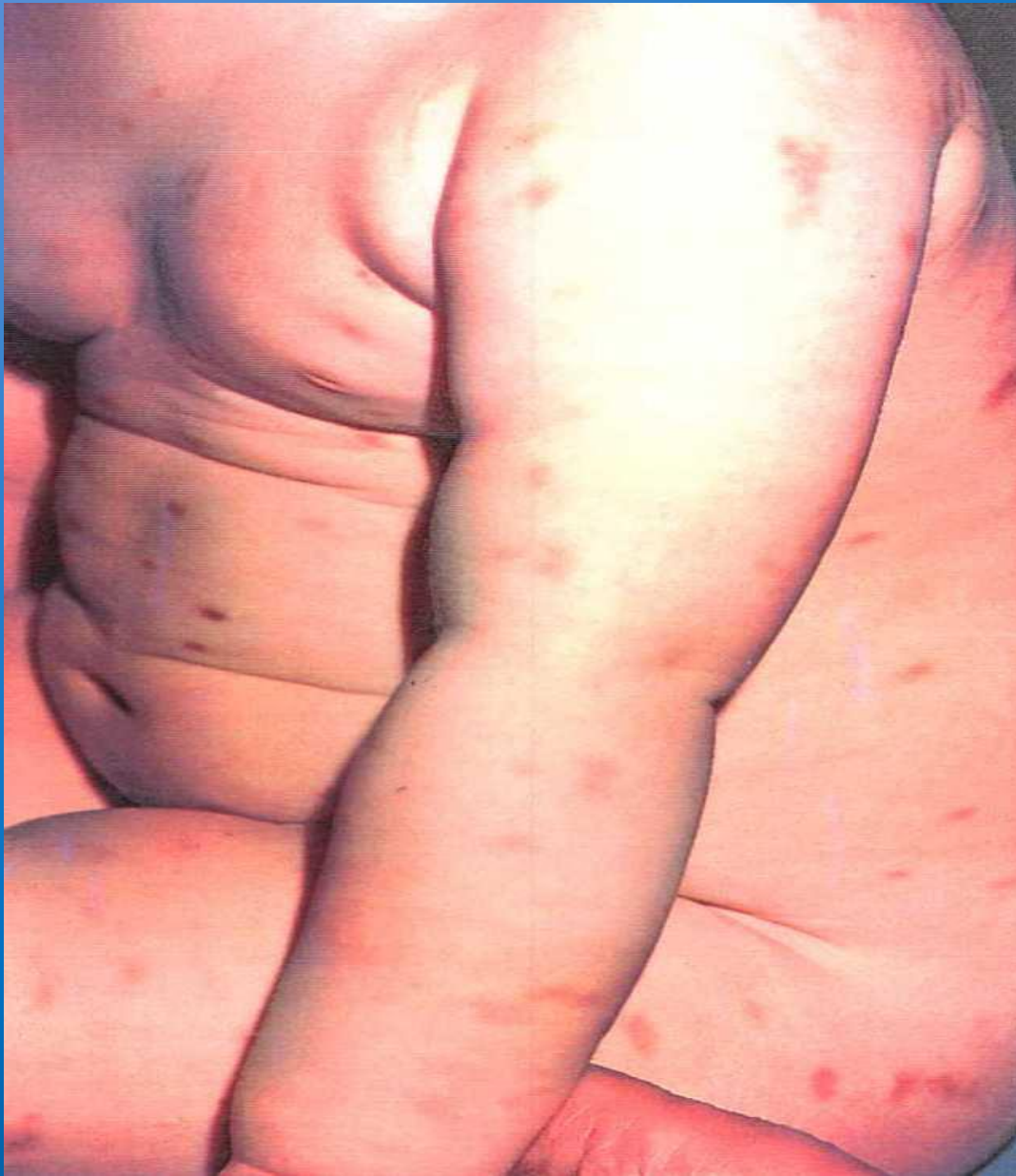

Difúzna kutáňa mastocytóza

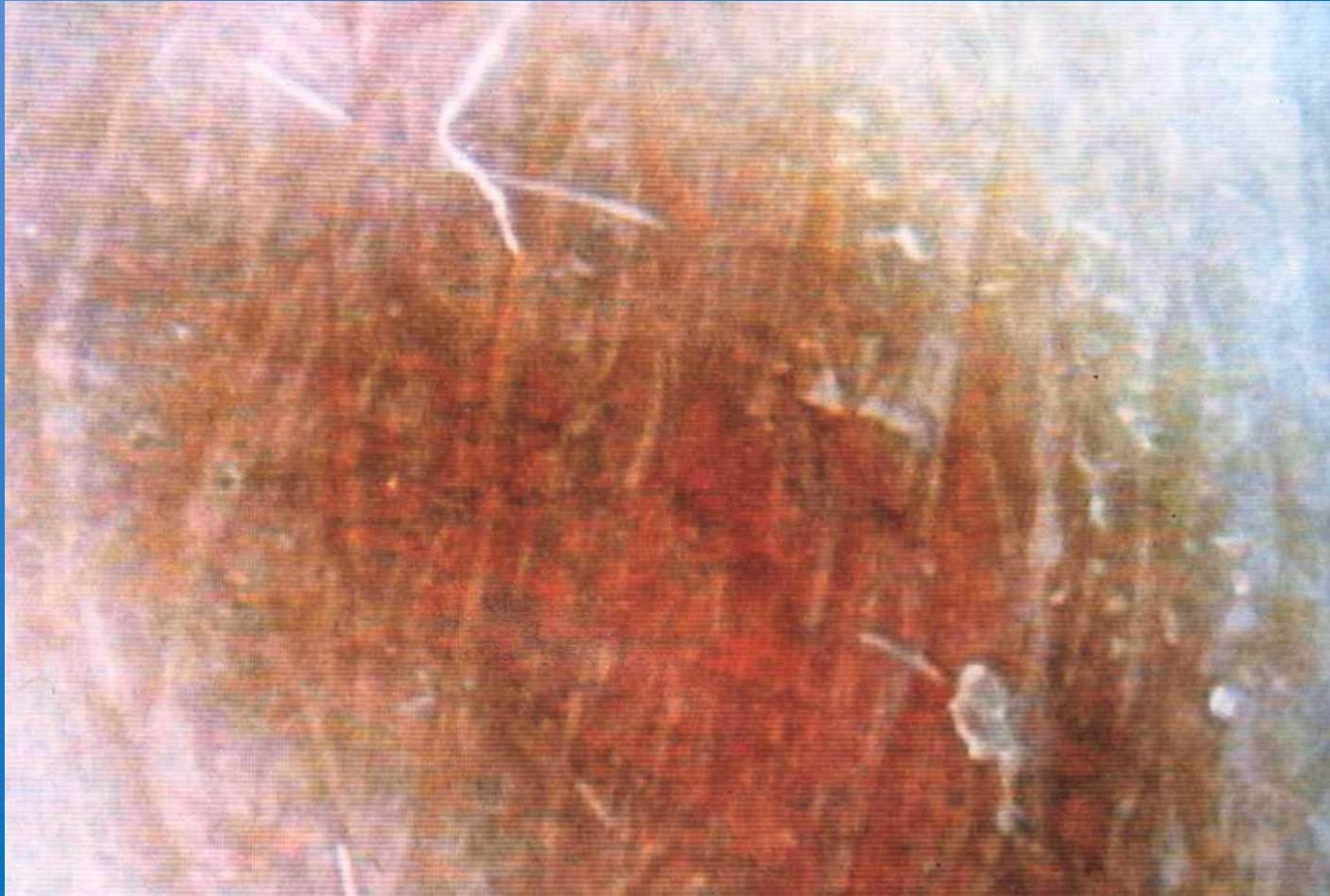

Dermatofibroskopia



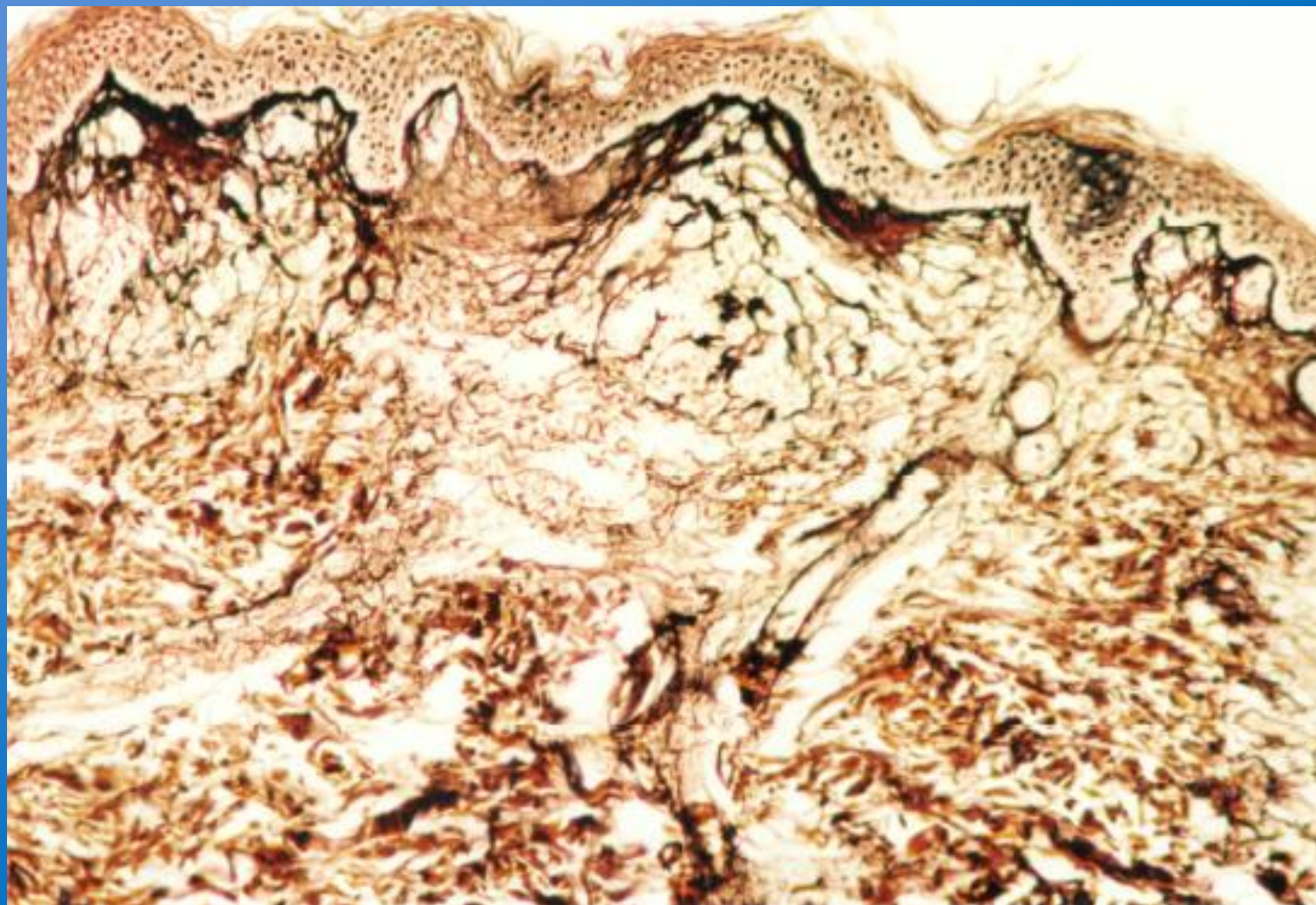


Urticaria pigmentosa



Dermatofibroskopia





Fibrotizácia

